

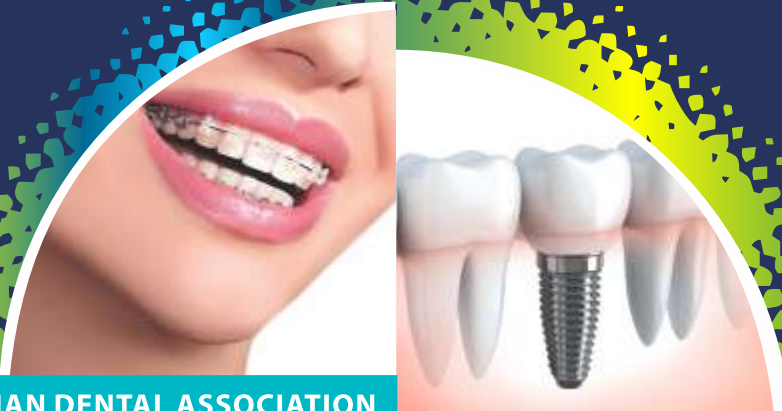

[www.idakochi.org](http://www.idakochi.org)

# JIDAK

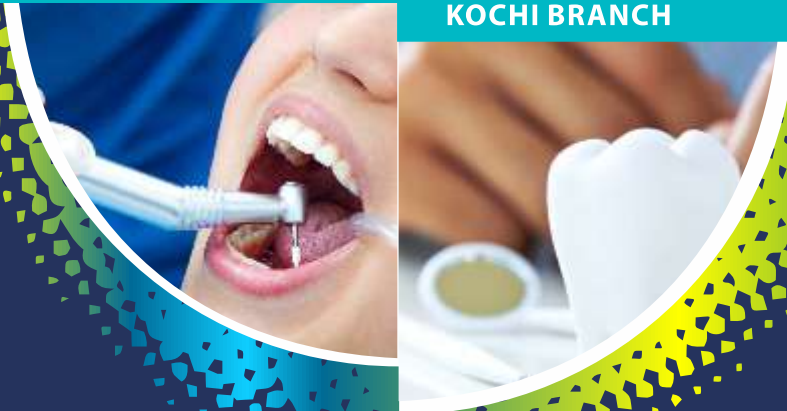Oct.- Dec. 2020, Volume 2 , Issue 4

JOURNAL OF INDIAN DENTAL ASSOCIATION - KOCHI



INDIAN DENTAL ASSOCIATION

KOCHI BRANCH







[www.idakochi.org](http://www.idakochi.org)

# JIDAK

Oct.- Dec. 2020, Volume 2 , Issue 4

**JOURNAL OF INDIAN DENTAL ASSOCIATION - KOCHI**

Journal of Indian Association of Kochi Branch (JIDAK) is the official scientific publication of Indian Dental Association, Kochi Branch. It is a peer-reviewed journal published quarterly in e-format as well as print format.

The journal invites manuscripts from dental and other allied health sciences. It publishes manuscripts under categories of Original Research, Review and Case Reports.

{ For submission of manuscripts,  
log on to [www.jidakochi.org](http://www.jidakochi.org).  
For communications,  
mail to [jidakochi@gmail.com](mailto:jidakochi@gmail.com). }

## EDITORIAL BOARD

### Co-editors:

Dr. Nivedita B.  
Dr. Noorudeen A. M.  
Dr. Prashant P. S.  
Dr. Sunil M. Eraly  
Dr. Pooja Latti  
Dr. Vidya Parameshwaran  
Dr. Esha Madhu  
Dr. Sobitha G.  
Dr. Radhakrishnan

### Advisory Board

Dr. Anjana G.  
Dr. V. I. Paul  
Dr. Ajit P.  
Dr. Siby T. Chennankara

### Chief Editor

Dr. Meera Gopalakrishnan

### Editor in Charge

Dr. Subramaniam R.

## *Chief Editors Message*

Greetings from Team JIDAK

Yet another proud moment for JIDAK, as we are launching the last issue of 2020, continuing our never ending path of academic extravaganza!!

This issue of JIDAK, makes its significance evident in the time of this struggling period of pandemic, and I would like to say that there is always light at the other end, and we should keep our spirits high and continue with never ending optimism!

This issue of JIDAK also coincides with me stepping down from the post of the editor, which I am sure, I have done to the best of my ability.

I am confident that the new Editorial team will definitely raise the bar of JIDAK to even more heights..

I would like to thank my entire team and the IDA KOCHI office for the continuous support in helping me take the JIDAK to the zenith of academic excellence!!



JAI JIDAK

JAI IDA

Dr. Meera Gopalakrishnan  
Chief Editor- JIDAK  
IDA Kochi

# CONTENTS

## **PERIODONTAL CONSIDERATION IN RESTORATIVE DENTIST**

Dr. Neetu Mary Joseph, Dr. Majo Ambooken  
Dr. Jayan Jacob Mathew, Dr. Linta Thomas 04-09

---

## **ENDO-PERIO LESIONS: RESOLVING THE CLINICIAN'S CHAOS**

Dr. Rinu Mary Kuriakose, Dr. Majo Ambooken  
Dr. Jayan Jacob Mathew, Dr. Anu Kuriakose 10-17

---

## **INFECTION CONTROL IN DENTISTRY POST COVID 19 : A REVIEW**

Dr. M. S. Sreelekshmi, Dr. Prabu P. S.  
Dr. Meenu Merry C. Paul, Dr. Binsu Sukumaran  
Dr. Laju S., Dr. Rahul Das 18-25

---

## **FIRE SAFETY IN DENTAL PRACTICE**

Dr. Suma B. Satenahalli, Dr. Mahesh Hiregoudar  
Dr. Anand Patil, Dr. Subhashgouda Patil 26-29

---

## **MAXILLARY EXPANSION - A REVIEW**

Dr. Archana Mohan, Anshad Nazarudheen  
Dr. Sahal Abu 30-35

---

## **CORONA VIRUS AND ROAD TOWARD FUTURE PROSPECTIVE: A REVIEW**

Dr. Ajay Mootha, Dr. Madhushree Patil  
Dr. Surojit Dutta, Dr. Nitin Jaggi 36-41

---

## **PROSTHODONTIC MANAGEMENT OF A XEROSTOMIC PATIENT WITH SALIVARY RESERVOIR DENTURE: A CASE REPORT**

Dr. Ajay Mootha, Dr. Anjusha Pillewar  
Dr. Aniket Shinde 42-49

---

# PERIODONTAL CONSIDERATION IN RESTORATIVE DENTISTRY

## ABSTRACT

The concept of Biologic width has been widely described by periodontists and restorative dentists. An adequate understanding of relationship between periodontal tissues and restorative dentistry is important to ensure proper form, function and esthetics, and comfort of the dentition. The concept of biologic width gains importance in the case of extensive caries management, subgingival margin placement, subgingival perforation, and post and core placement in endodontic therapy. Violation of the biologic width lead to complications like gingival inflammation, alveolar bone loss and improper fit of the restorative component. This article reviews about the clinical aspects of biological width considerations in various restorative and periodontal surgical procedures.

**Keywords:** Biologic width, restorative dentistry, subgingival perforation, post and core.

## Authors:

- <sup>1</sup>Dr. Neetu Mary Joseph  
<sup>2</sup>Dr. Majo Ambooken  
<sup>3</sup>Dr. Jayan Jacob Mathew  
<sup>4</sup>Dr. Linta Thomas

<sup>1</sup>Post Graduate Student  
Department of Periodontics  
Mar Baselios Dental College  
Kothamangalam, Kerala

<sup>2</sup>Professor and Head  
Department of Periodontics  
Mar Baselios Dental College  
Kothamangalam, Kerala

<sup>3</sup>Professor  
Department of Periodontics  
Mar Baselios Dental College  
Kothamangalam, Kerala

<sup>4</sup>Senior Lecturer  
Department of Periodontics  
Mar Baselios Dental College  
Kothamangalam, Kerala

**Address for correspondence**  
Dr. Neethu Mary Joseph  
Post Graduate Student  
Department of Periodontics  
Mar Baselios Dental College  
Kothamangalam, Kerala  
E mail: mary.neetu18@gmail.com

J Ind Dent Assoc Kochi 2020;2(4):4-9.

## INTRODUCTION

The interrelationship between restorative dentistry and periodontics is very dynamic and inseparable. The establishment of periodontal health is necessary for successful restorative procedures, because for a restoration to survive, the periodontium must be healthy so that the teeth are maintained properly in the dental arch and maintain harmony with their surrounding periodontal tissues.

To ensure long term gingival health, one of the most important parameter is managing the proper margin location of a restoration relative to the alveolar bone. Therefore a close attention should be paid to the restorative procedures such as margin placement, contours of restorations as well as occlusal forces.

For long-term survival of restoration, both functionally and esthetically, certain biological considerations are very critical to preserve the health of the periodontium and thus must be given due importance in clinical practice. Restoring the proper anatomy of the tooth and maintaining the health of the soft tissue should be a prime consideration during the restorative procedure.

### Biologic considerations

The biologic width is defined as the dimension of the soft tissue, which is attached to the portion of the tooth coronal to the crest of the alveolar bone.<sup>1</sup> This term was based on the work of Gargiulo et al.<sup>2</sup> who described the dimensions and relationship of the dentogingival junction in humans. Based on this work, the biologic width is commonly stated to be 2.04 mm, which represents the sum of the epithelial and connective tissue measurements.

In order to avoid pathological changes and predict better treatment results, it is necessary to keep gingival biological width unaltered during restorative procedures. The line of treatment mainly depends on relationship of crown-root alveolar bone and patient's esthetical expectations. To keep margins of restoration supragingivally the distance from marginal bone to margins of restoration should not be less than at least 3 mm.

Placing restorative margins within the biologic

width frequently leads to gingival inflammation, clinical attachment loss, and bone loss. This is thought to be due to the destructive inflammatory response to microbial plaque located at deeply placed restorative margins.

### Biologic width consideration in Class II cavity preparation

Establishing the interproximal contact is the primary objective of restorative procedures.<sup>3</sup> Ideal Proximal contact acts as a barrier against food impaction and thus contributes to underlying periodontal health,<sup>4</sup> by providing food spillway and facilitating hygienic cleaning. The most reliable mechanism by which dental restorations may affect marginal health is the increase of plaque accumulation. Loss of periodontal support and subsequent tooth loss can result if the condition is not recognized and treated in its early stages.

Restorative margins placed subgingivally risk invading the attachment apparatus. Restorations may impinge on the biologic width by being placed deep in the sulcus or within the junctional epithelium. This may promote inflammation and loss of clinical attachment with apical migration of the junctional epithelium and reestablishment of the attachment apparatus at a more apical level.

### Problems associated with overhanging restoration

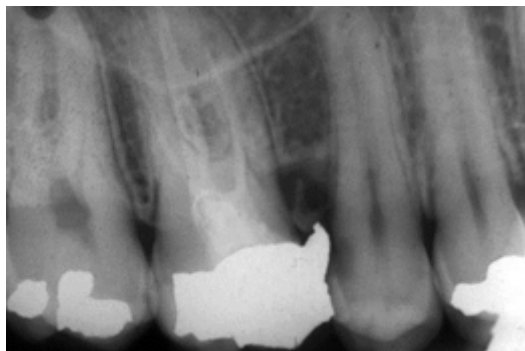Overhanging margins contribute to periodontal disease<sup>5</sup> by:

- (1) Providing ideal locations for the accumulation of plaque by preventing the patient's access to remove accumulated plaque
- (2) Changing the ecologic balance of the gingival sulcus area to one that favors the growth of disease associated organisms (gram-negative anaerobic species) at the expense of the healthy state organisms (gram-positive facultative species).

The frequency of overhanging margins of proximal restorations varies from 16.5% to 75%.<sup>6</sup> Removal of overhanging restorations allows a more effective plaque control, resulting in the disappearance of gingival inflammation and

increase in the alveolar bone support. Margins placed at the level of the gingival crest cause less severe gingival inflammation compared to subgingivally placed margins.<sup>7</sup>

The severity of bone loss was directly proportional to the severity of the overhang. Overhangs were designated as large if they occupied >51% of the interproximal space. Small and medium overhangs (<20% and 20-50% of the interproximal space, respectively) were not associated with bone loss.



IOPA showing class II overhanging restoration

#### Class V cavity preparation (Non carious cervical lesion)

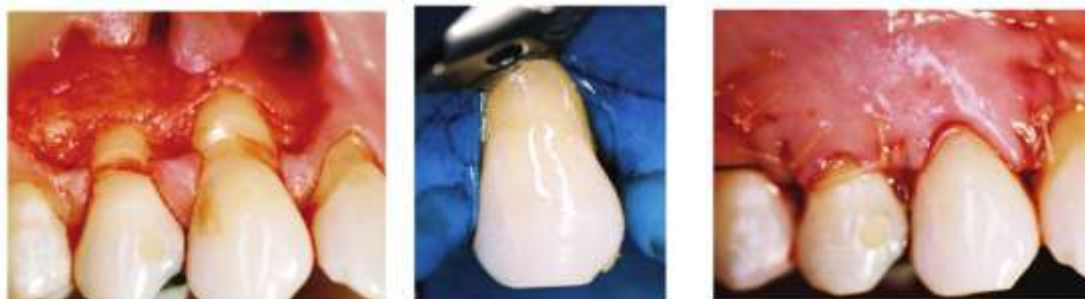Gingival recession associated with cervical abrasion is very common. Possible causes include traumatic brushing in the cervical region, causing gingival recession followed by dental abrasion.<sup>8</sup> Class V lesions can be extremely difficult to restore due to problems, including isolation and crevicular moisture control, adhesion, finishing, and polishing. A combined restorative-periodontal therapy, in

which the restorative therapy is completed before mucogingival surgery, has been proposed for the treatment of gingival recession that is associated with NCCLs.<sup>9</sup> Following the healing period after surgery, the soft tissue is positioned over a part of the restorative material and the apical border of the restoration is in the subgingival area. Response of the gingival tissues to the restorative materials is very important. It has been reported that subgingival restorations are associated with greater plaque accumulation, bleeding on probing, and attachment loss<sup>10</sup> but well-finished subgingival restorations were not associated with periodontal inflammation in combined restorative-periodontal treatment.

Various dental materials and surgical approaches have been used to manage these combined defects. In order to provide the most predictable result in combined restorative-periodontal treatment,<sup>11</sup> resin composites or resin-modified glass ionomer cements (RMGIs) have been commonly used<sup>12</sup>, and gingival recessions have been treated using the coronally advanced flap (CAF) technique, either alone or in combination with a connective tissue graft (CTG)<sup>13</sup>.

#### Furcation involvement

Furcation involvement requires immediate treatment and proper prosthetic replacement. Furcations that have been exposed leading to loss of periodontal attachment should be “fluted” or “barreled out”. The concept of fluting into molar furcations is based on the desire to eliminate “plaque traps” and facilitate



(a) A full-thickness flap was elevated up to 3 mm apically to the bone crest, and a partial thickness flap raised. (b) Restoration performed with resin-modified glass ionomer cement, © Connective tissue graft was placed. Sutures made, pulling the gingival margin as coronally as possible.

Picture courtesy Journal of Periodontology.



plaque control.<sup>14</sup> Final restoration should not follow the anatomy of the original clinical crown but should be an extension of the contours of the periodontally exposed roots.<sup>15</sup> When this approach is properly executed, the triangular region that is created by the roots and the crevicular bulge is eliminated. This triangular region is the most difficult area to maintain in a plaque-free condition with conventional brushing techniques. Recontouring the furcation can eliminate the triangle which can help better plaque control with normal brushing.

### Contoured dental restorations

Dental restorations are ideally made to blend smoothly with the contours of the natural tooth being restored. Ideally, the margins should be tightly adapted against the tooth, providing a hermetic seal against bacterial invasion. The most common error in recreating the contours of the tooth in dental restorations is over contouring of the facial and lingual surfaces, generally in the gingival third. Over contouring is a result of inadequate tooth preparation that forces technician to produce a bulky restoration. This overcontouring results in an area that is inaccessible to oral hygiene procedures and is unable to control plaque accumulation. Consequently plaque accumulates and the gingival becomes inflamed. Over contoured restorations also prevent the self-cleaning mechanisms of the adjacent cheek, lips and tongue. Undercontouring is not nearly as damaging to the gingiva as the overcontouring.

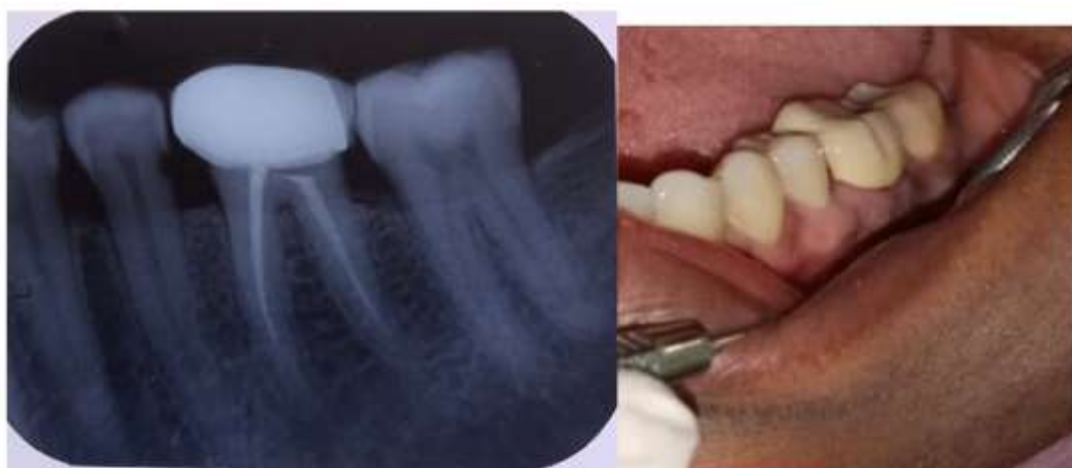### Crown placement

In situations where a tooth has a short clinical crown deemed inadequate for retention of a required restoration, it is necessary to increase the size of the clinical crown using crown lengthening procedures. These crown lengthening procedures enables the restoration to develop an adequate area for retention without extending the margins deep into the periodontal tissues.

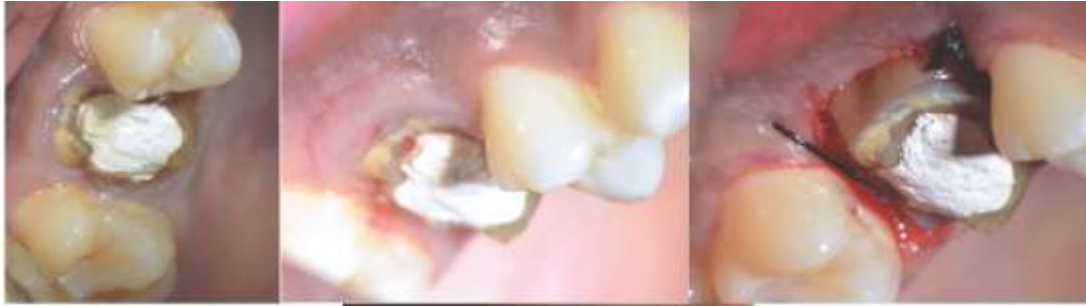Restorative procedures must be delayed until new gingival crevice develops after periodontal surgery. In non-esthetic areas, the site should be re-evaluated atleast 6 weeks post surgically prior to final restorative procedures. In esthetic areas, a longer healing period is recommended to prevent recession. Wise recommends 21 weeks for soft tissue gingival margin stability. Therefore, restorative treatment should be initiated after 4-6 months.<sup>16</sup> The margin of the provisional restoration should not hinder healing before the biologic width is established by surgical procedures.

One major drawback when fitting a cement-retained restoration is the extrusion of excess cement. This residual cement can be extruded into the sulcus. Excess cement located at a depth of more than 3 mm can be difficult to see and thoroughly remove. If it is not properly removed, it can initiate periodontal disease.

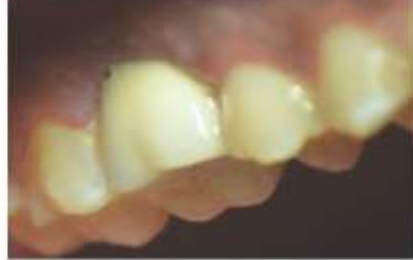A retraction cord can minimizes the risk of excess cement entering the sulcus during the cementation process. Once the crown is in place and the cement is set, the retraction cord



IOPA and clinical pictures showing over contoured crown



(a) Inadequate crown length seen with respect to 16 (b) Crown lengthening with osseous contouring done (c) sutures placed (d) crown placement done



is removed, and the crown is checked for any remaining excess cement. Digital X-ray can also be used to check excess cement.

## CONCLUSION

It is very important for clinician to combine periodontal and restorative procedures in a coordinated manner to get the best clinical outcome. All phases of clinical dentistry are intimately related to a common objective: The preservation and maintenance of the natural dentition in healthy state. For restorations to survive for long-term, the periodontium must remain healthy.

For successful oral rehabilitation of the patient the multidisciplinary approach is required where ideas can be exchanged for sake of sound oral health.

## REFERENCES

1. Tylman SD: Theory and Practice of Crown and Bridge Prosthodontics, Ed 5. St Louis, Mosby, 1965.
2. Gargiulo, A. W., Wentz, F. & Orban, B. (1961) Dimensions and relations of the dentogingival junction in humans. *Journal of Periodontology* 32, 261-267
3. Chuang SF, Su KC, Wang CH, Chang CH. Morphological analysis of proximal contacts in class II direct restorations with 3D image reconstruction. *J Dent* 2011; 39:448-56.
4. Khan FR, Umer F, Rahman M. Comparison of proximal contact and contours of premolars restored with composite restoration using circumferential matrix band with and without separation ring: A randomized clinical trial. *Int J Prosthodont Restor Dent* 2013; 3:7-13.
5. R Vacaru, A Podariu, D Jumanca, A Galuscan, R Muntean. Periodontal-restorative interrelationships. *OHDMBSC*. 2003,3,12-5
6. Jeffcoat MK, Howell TH. Alveolar bone destruction due to overhanging amalgam in periodontal disease *J Periodontol* 1980; 51(10): 599-602.
7. Flores-de-Jacoby L, Zafropoulos GG, Ciancio S. Effect of crown margin location on plaque and periodontal health *Int J Periodontics Restorative Dent* 1989; 9(3): 197-205.
8. Heasman PA, Holliday R, Bryant A, Preshaw PM. Evidence for the occurrence of gingival recession and non-carious cervical lesions as a consequence of traumatic toothbrushing. *J Clin Periodontol*. 2015;42(Suppl 16):S237-S255
9. Lucchesi JA, Santos VR, Amaral CM, Peruzzo DC, Duarte PM. Coronally positioned flap for treatment of restored

- root surfaces: a 6-month clinical evaluation. *J Periodontol.* 2007;78(4):615–623.
10. Padbury A, Jr, Eber R, Wang HL. Interactions between the gingiva and the margin of restorations. *J Clin Periodontol.* 2003;30:379–385.
  11. Lucchesi JA, Santos VR, Amaral CM, Peruzzo DC, Duarte PM. Coronally positioned flap for treatment of restored root surfaces: a 6-month clinical evaluation. *J Periodontol.* 2007;78(4):615–623.
  12. Peumans M, Kanumilli P, De Munck J, Van Landuyt K, Lambrechts P, Van Meerbeek B. Clinical effectiveness of contemporary adhesives: a systematic review of current clinical trials. *Dent Mater.* 2005;21(9):864–881.
  13. Santamaria MP, Ambrosano GB, Casati MZ, Nociti FH, Júnior, Sallum AW, Sallum EA. Connective tissue graft plus resin-modified glass ionomer restoration for the treatment of gingival recession associated with non-carious cervical lesion: a randomized-controlled clinical trial. *J Periodontol.* 2009;36(9):791–798.
  14. Schluger S, Yuodelis RA, Page RC. *Periodontal disease.* Philadelphia: Lea &Febiger; 1977. p. 586-617.
  15. Yuodelis R, Weaver J, Sapkos S. Facial and lingual contours of artificial complete crown restorations and their effect on the periodontium. *J Prosthet Dent* 1973; 29:61.
  16. Wise MD. Stability of the gingival crest after surgery and before anterior crown placement. *J Prosthet Dent* 1985; 53:20-3

# ENDO-PERIO LESIONS: RESOLVING THE CLINICIAN'S CHAOS

## ABSTRACT

Human periodontium and dental pulp cavity are closely connected. This permit passage of pathogens between these two distinct anatomical areas. Pathological process in one entity can lead to disease process in other. This have led to the term endo-perio lesions. Diagnosis and management of endo-perio lesions differ from those lesions of single causative factor. Despite decades of literature describing periodontal-endodontic lesions, they are still a misunderstood disease entity. Detailed examination and definitive treatment plan is pivotal for judicious management of the involved teeth. The aim of the present review is to unwind the confusions and queries in diagnosing and treating the endo-perio lesions.

**Keywords:** endo- perio lesions, pulp, periodontium.

## Authors:

- <sup>1</sup>Dr. Rinu Mary Kuriakose  
<sup>2</sup>Dr. Majo Ambooken  
<sup>3</sup>Dr. Jayan Jacob Mathew  
<sup>4</sup>Dr. Anu Kuriakose

<sup>1</sup>Post Graduate Student  
 Department of Periodontics  
 Mar Baselios Dental College  
 Kothamangalam, Kerala

<sup>2</sup>Professor and Head  
 Department of Periodontics  
 Mar Baselios Dental College  
 Kothamangalam, Kerala

<sup>3</sup>Professor  
 Department of Periodontics  
 Mar Baselios Dental College  
 Kothamangalam, Kerala

<sup>4</sup>Reader  
 Department of Periodontics  
 Mar Baselios Dental College  
 Kothamangalam, Kerala

## Address for correspondence

Dr. Rinu Mary Kuriakose  
 Post Graduate Student  
 Department of Periodontics  
 Mar Baselios Dental College  
 Kothamangalam, Kerala  
 E mail: rinumarykuriakose1994@gmail.com

J Ind Dent Assoc Kochi 2020;2(4):10-7.

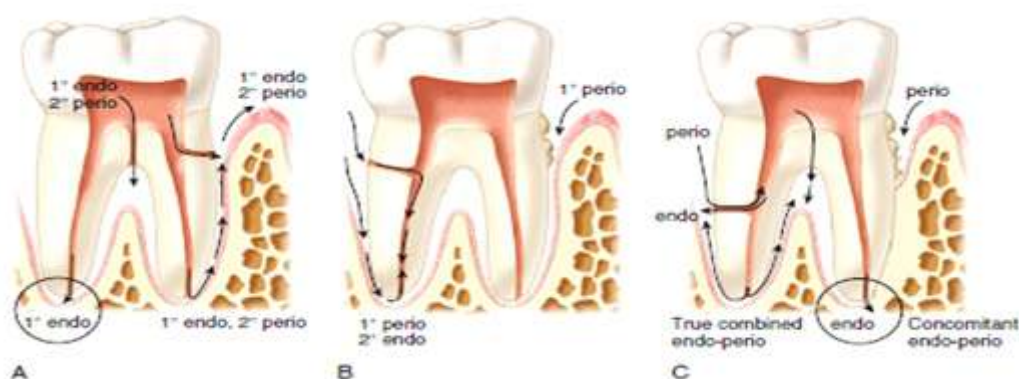## INTRODUCTION

Endodontium and periodontium are closely related. They are considered as one biologic unit. Diseases of one tissue may lead to the involvement of other. The actual relationship between periodontal and pulpal disease was first described by Simring and Goldberg in 1964<sup>1</sup>. Since then, the term “perio-endo” lesion has been used to describe lesions due to inflammatory products found in varying degrees in both periodontium and pulpal tissues. Endo-periodontal lesions (EPL), in spite of being relatively rare in clinical practice, might severely compromise the prognosis of the tooth, and are considered one of the most challenging problem faced by clinicians, because they require multidisciplinary evaluation, diagnosis, and treatment.<sup>2</sup> With tooth development and root canal formation, three main avenues of communication between periodontal and endodontic tissues are created: the apical foramen, the lateral and accessory canals, and the dentinal tubules<sup>3</sup>. These special anatomical structures form an intimate continuum between the periodontal and endodontic tissues, through which pathological changes of either may lead to infection of the other. Bacteriological studies have reported similarities in the quantity and structure of the bacterial flora associated with endodontic and periodontal lesions; these findings indicate the communication between the periodontal and endodontic tissues.<sup>4,5,6</sup> There are various pathways for the exchange of infectious elements and irritants from the pulp to periodontium or

vice versa, leading to the development of endodontic periodontal lesions.<sup>7,8</sup>

- Pathways of developmental origin (anatomical pathways): Apical foramen, accessory canals/lateral canals.
- Pathways of pathological origin: Empty spaces on root created by Sharpey's fibers, root fracture following trauma, idiopathic root resorption internal and external, loss of cementum due to external irritants.
- Pathways of iatrogenic origin: exposure of dentinal tubules following root planning, accidental lateral root perforation during endodontic procedures, root fractures during endodontic procedures.

Penetration of the surface of a healthy (vital) pulp by oral bacteria is relatively slow or may be blocked entirely. In contrast, a necrotic pulp is rapidly invaded and colonized by bacteria. When the pulp becomes necrotic, inflammatory by products of pulpal origin may leach out through these pathways and initiate/trigger an inflammatory vascular response in the periodontium, cause destruction of periodontal tissue fibers, resorption of adjacent alveolar bone and cementum. Nature and extent of periodontal destruction depends on various factors such as virulence of microorganisms, duration of the disease and the host defence mechanism. Similarly, the reverse of the effect of a necrotic pulp on the periodontal ligament, has been referred to as retrograde periodontitis.<sup>9</sup>



A. Endodontic lesions: The pathway of inflammation is through the apical foramen, furcation canals and lateral accessory canals to the periodontium. This results in a primary endodontic lesion, sometimes progressing to secondary periodontal involvement.

B. Periodontal lesions: This is the progression of periodontitis by the way of lateral canal and apex to a secondary endodontic lesion.

C. True combined endodontic and periodontal lesion and concomitant endodontic and periodontal lesions.

Cohen's Pathways of the Pulp 11th edition

## ASSESSMENT AND DIAGNOSIS

Simon et al. in 1972, published the classification system most commonly used for diagnosis of EPL,<sup>10</sup> and included the following categories:

- primary endodontic lesions.
- primary endodontic lesions with secondary periodontal involvement.
- primary periodontal lesions.
- primary periodontal lesions with secondary endodontic involvement; and
- “true” combined lesions.

The main drawback of this classification and a recent proposed amendment<sup>11</sup> was to base their categories on the primary source of infection (root canal or periodontal pocket). This seemed to be a suitable approach, as lesions of periodontal origin might have a worse prognosis than those of endodontic origin. Von Arx and Cochran<sup>12</sup> proposed a clinical treatment classification of perio endo furcation lesions based on the role of membrane application in endodontic surgery. Singh<sup>13</sup> classified endo perio lesions based on the pathogenesis and added the term iatrogenic lesions, usually endodontic lesions produced as a result of treatment modalities. There are many classifications for endo perio lesions, but for differential diagnostic purposes, the so called ‘endo perio lesions’ are best classified as endodontic, periodontal, or a combined disease.<sup>14</sup>

Nonetheless, using “history of the disease” as the main criteria for diagnosis was not practical, because in the majority of cases the complete history is unavailable to the clinician. In addition, determining the primary source of infection is not relevant for the treatment of EPL, as both the root canal and the periodontal tissues would require treatment.<sup>15,16</sup> Thus, ideally, the diagnosis and classification of EPL should be based on the present disease status and on the prognosis of the tooth involved, which would determine the first step of the treatment planning that would be whether to maintain or extract the tooth.

The three main prognostic groups for a tooth with an EPL are: (1) hopeless, (2) poor, and (3) favourable. The hopeless prognosis is normally associated with EPL caused by trauma or iatrogenic factors, whereas the prognosis of a tooth with an EPL associated with endodontic and periodontal infections may range from favour-

able to hopeless, depending on the extension of the periodontal destruction around the affected tooth, and the presence and severity of the periodontal disease affecting the patient's oral health.

**Several examinations help the diagnosis between endodontic and periodontal disease:**

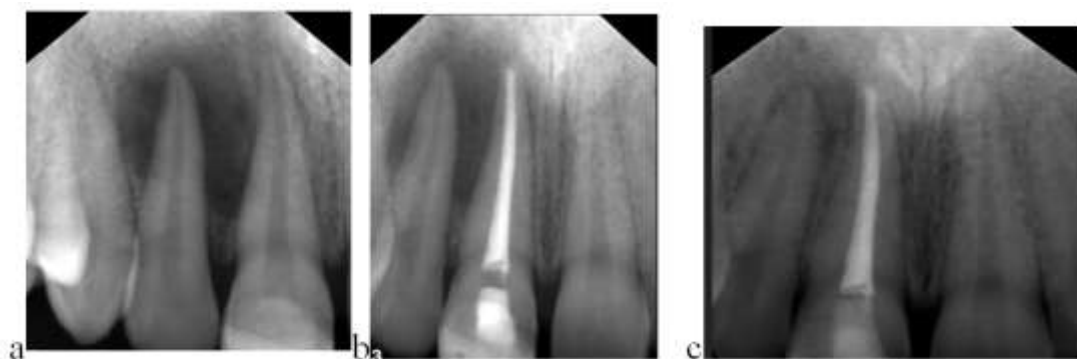
- Vitality test:** In endodontic disease, the tooth is non-vital; in periodontal disease, the tooth is vital in most cases.
- Plaque/calculus:** In endodontic disease, plaque or calculus may be present, but they are not the primary cause of the disease; in periodontal disease, plaque or calculus is the primary cause.
- Pocket/probing depth:** In endodontic disease, a single and narrow pocket may be present; in periodontal disease, generalized periodontal pockets may present and they are located relatively wide and coronally.

## TREATMENT

When a clinician cannot make a definitive diagnosis in the case of an endo- perio lesions, it may be prudent for him or her to initiate either of the treatment modalities and hope for repair. However, this could be overcome by proper history taking and sequential treatment planning.

When the etiology is purely endodontic, calcium hydroxide can be used as an intracanal medicament. It can be very effective in the healing of large periapical lesion. Calcium hydroxide works in many ways,<sup>17</sup> chemically it damages the microbial cytoplasmic membrane by the direct action of hydroxyl ions, suppresses enzyme activity, disrupts the cellular metabolism and inhibits deoxyribonucleic acid (DNA) replication by splitting DNA. Physically it acts as a physical barrier that fills the space within the canal and prevents the ingress of bacteria into the root canal system. It also kills the remaining micro organisms by withholding substrates for growth and limiting space for multiplication. Biologically it encourages the periapical hard tissue healing around teeth with infected canals, inhibits root resorption and stimulates periapical healing after trauma.<sup>18-22</sup>

Primary periodontal disease should only be treated by periodontal therapy. They are treated

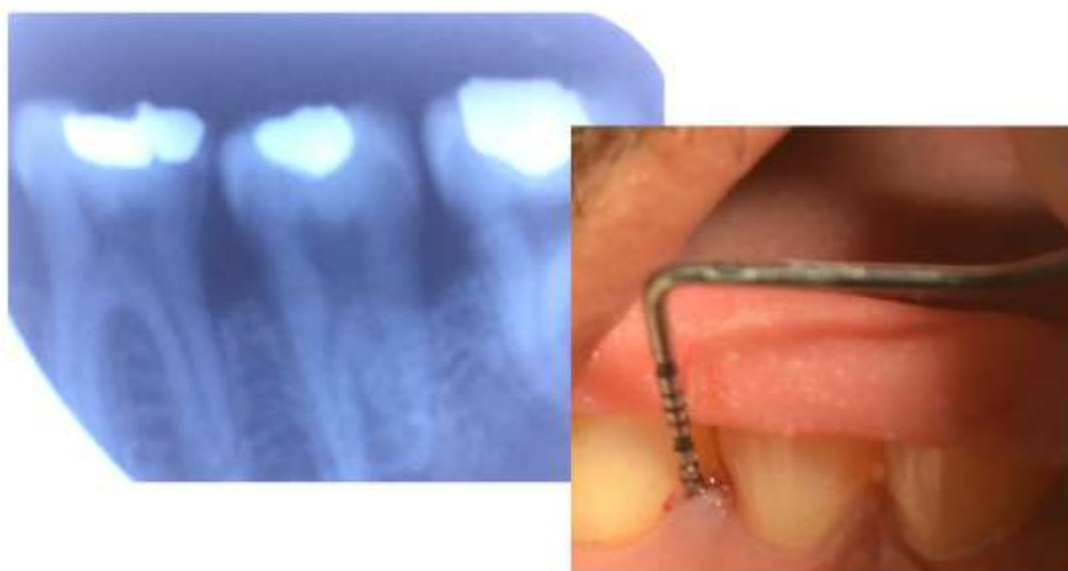

a) pre-operative radiograph of a primary endodontic lesion, b) lesion treated endodontically c) complete healing after 6 months.  
Pic courtesy Inter J Dental Research 2010

by hygiene phase therapy followed by subsequent correction of poor restorations and development grooves. If necessary periodontal surgery should be performed, clinicians should take precautions during periodontal therapy and avoid the use of irritating chemicals, minimize the use of ultrasonics and rotary scaling instruments. Judicious use of periodontal surgical intervention is advantageous to treat this lesions.<sup>23</sup>

The prognosis for treatment of primary endodontic disease with secondary periodontal involvement depends primarily on the severity of periodontal involvement. Tooth with these lesions should first be treated with endodontic and simple hygiene phase therapy. Multi visit endodontics should be practiced and the placement of intracanal medicament was found to be very useful in reducing inflamma-

tion and favoring repair.<sup>24</sup> Treatment results should be evaluated in 2 3 months and only then further periodontal treatment should be considered. This sequence of treatment allows sufficient time for initial tissue healing and better assessment of the periodontal condition.<sup>25,26</sup> It also reduces the potential risk of introducing bacteria and their byproducts during the initial phase of periodontal healing. In this regard, it has been suggested that aggressive removal of the periodontal ligament and underlying cementum during interim periodontal therapy may adversely affect periodontal healing, therefore, should be avoided.<sup>27</sup> But in cases where healing with only endodontic therapy does not occur then both endodontic and periodontal treatments should be carried out since with endodontic treatment alone, only part of the lesion may heal up to the level of the secondary periodontal lesion.



Primary periodontal lesions showing radiographic evidence of bone loss and clinical probing depth of 8mm

Root fractures may also present as primary endodontic lesions with secondary periodontal involvement. These typically occur on root treated teeth, often with post and crowns. Treatment depends on the tooth type, extent, duration and location of fracture, for example, single rooted tooth with lesions caused by vertical root fracture has a hopeless prognosis and should be extracted while molars can be treated by root resection or hemisection.<sup>28</sup>

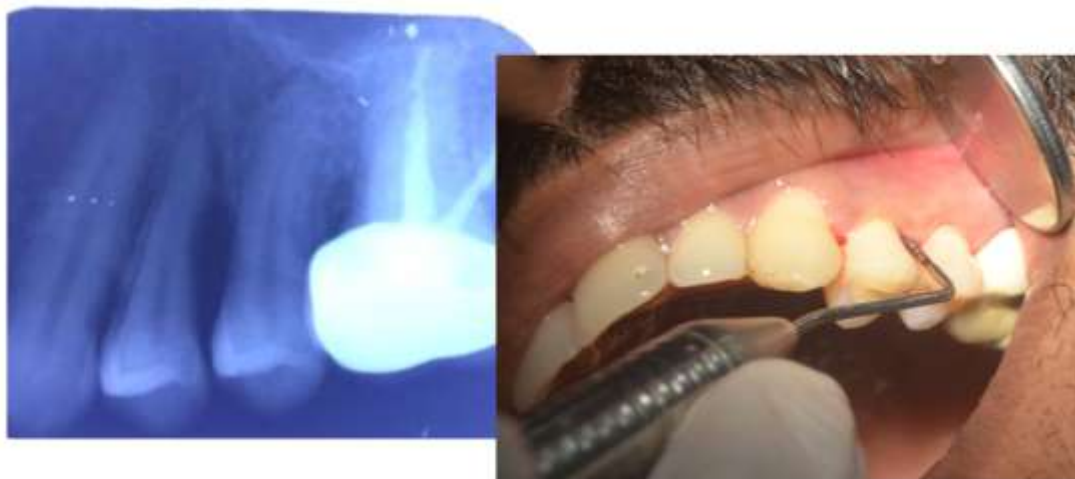Primary periodontal disease with secondary endodontic involvement and true combined endodontic periodontal diseases require both endodontic and periodontal regenerative procedures. The prognosis of combined diseases mainly rests with the efficacy of periodontal therapy.<sup>29</sup> Though, root amputation, hemisection or bicuspidization may allow the root configurations to be changed sufficiently for a part of the root structure to be saved, however, the operator need to consider various factors before root resection such as tooth function, root filling, anatomy, restorability, bone support around the healthy root and patient's compliance. A tooth that requires a root to be resected always needs root canal treatment; therefore, the surgery must be planned with care, particularly with respect to the timing of the root treatment. Ideally, the tooth should be root filled prior to surgery.<sup>30</sup> The prognosis of an affected tooth can also be improved by increasing bony support, which can be achieved by bone grafting and guided tissue regeneration (GTR). These advanced treatment options are based on responses to conventional

periodontal and endodontic treatment over an extended time period. These regenerative procedures with the aid of the microscope, in the treatment of combined lesions have been found to have a success rate of 77.5%.<sup>31</sup> GTR therapy has also been implemented in the endodontic surgeries as a concomitant treatment during the management of the endodontic periodontal lesions.<sup>32,33</sup> The decisions and treatment strategy for the application of the regenerative procedures are made at various levels such as pre surgical, post root canal treatment, intra surgical, and post surgical.

However, lesions which are not true combined lesions, little or no improvement would be seen with the periodontal perspective after endodontic treatment, leaving a very poor and often hopeless prognosis. But with the advent of new regenerative materials, however, successful periodontal treatment of such lesions has been possible.

#### Root resection for management of endodontically & periodontally involved teeth

Root resection commits the patient not only to periodontal and endodontic treatment, but it may also involve a restorative procedure. Treatment of periodontally involved maxillary teeth creates unique challenges, given the presence of furcations, root proximities and the maxillary sinus. Maxillary molars have been more frequently diagnosed with furcation



Primary periodontal lesion extending to secondary endodontic lesion pre-operative radiograph and clinical probing depth of 12mm.



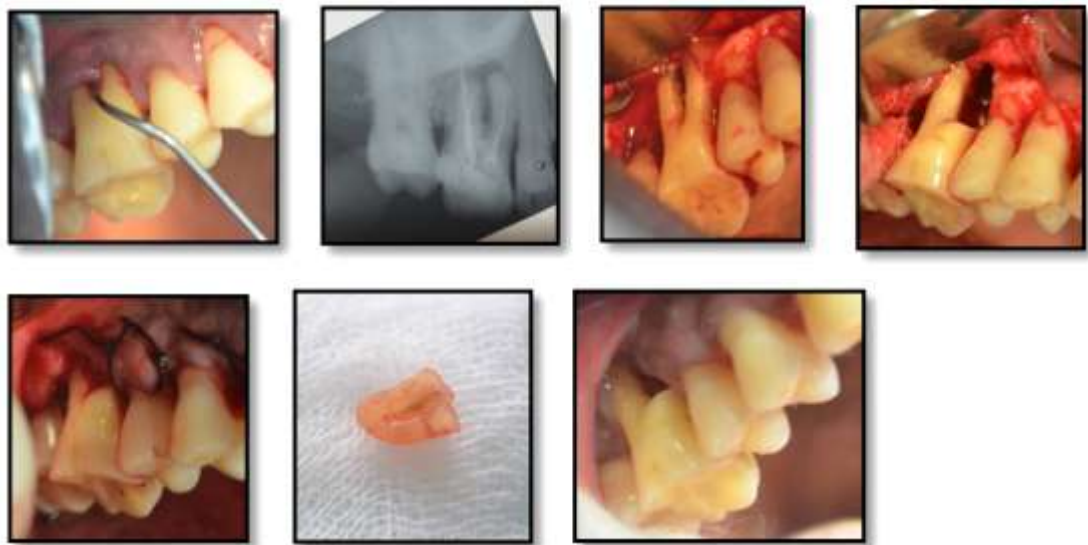
lesions than mandibular molars. Dannewitz et al. (2006) reported that 72% of the maxillary molars had furcation involvement, but 50% of the mandibular molars revealed furcation involvement upon flap reflection in patients with chronic periodontitis.

An accurate diagnosis is mandatory for the successfully treated endo-perio lesions. This diagnosis must cover both endodontic and periodontal component of the lesion. If the primary aspect cannot be evaluated, endodontic treatment should be given precedence, fol-

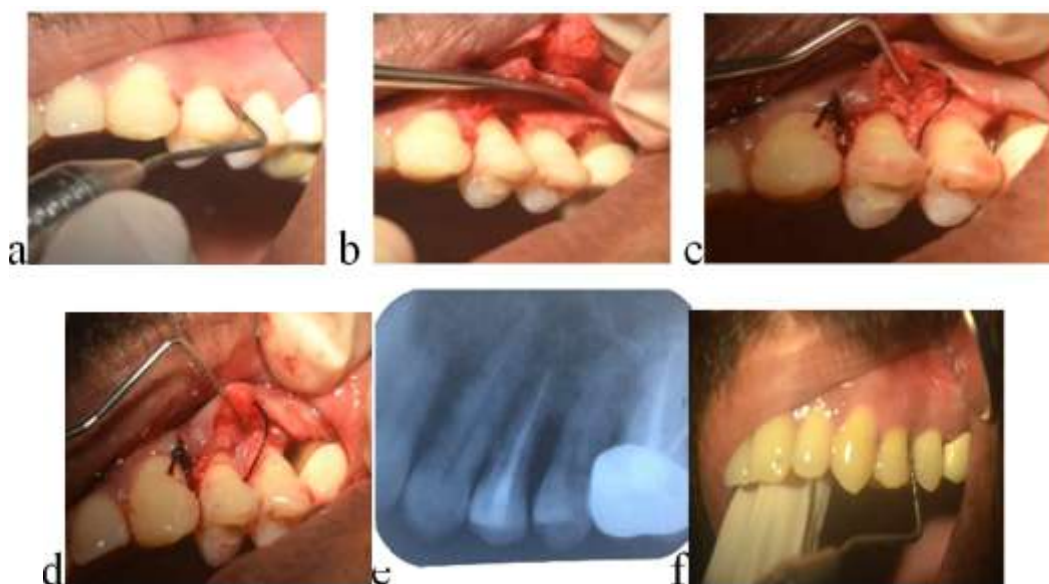
lowed by a wait-and-see approach until a decision for any additional endo-surgical and/or periodontal procedure can be focussed.

### GTR Therapy for management of endo-perio lesions

GTR therapy has also been implemented in the endodontic surgeries as a concomitant treatment during the management of the endodontic - periodontal lesions.<sup>33,34,35</sup>



Management of endodontic-periodontal combined lesions managed with mesio-buccal root resection: Endodontically treated 16; with Grade II furcation involvement, after completion of Endodontic treatment.



a) Clinical probing a PPD of 12mm, persisted after endodontic treatment, b) On flap elevation a deep defect was found on distal aspect of 24 c) & d) Bone graft with GTR membrane was placed. e) Post operative radiograph after 6 months f) Clinical probing depth reduced to 5mm.

true challenge. Its management requires thorough understanding of wound healing process involving both endodontic and periodontal complex. Concerted interdisciplinary approach can result in improving and maintaining the natural dentition in order to achieve health, comfort, aesthetics, and function even in teeth with periodontic endodontic lesions with primary periodontal origin.

## REFERENCES

1. Simring M, Goldberg M. The pulpal pocket approach: Retrograde periodontitis. *J Periodontol* 1964;35:22-48.
2. Rotstein I, Simon JH. Diagnosis, prognosis and decision-making in the treatment of combined periodontal-endodontic lesions. *Periodontol* 2000. 2004;34:165-203.
3. P. Singh, "Endo-perio dilemma: a brief review," *Dental Research Journal*, vol. 8, no. 1, pp. 39-47, 2011
4. T. Kobayashi, A. Hayashi, R. Yoshikawa, K. Ookuda, and K. Hara, "The microbial flora from root canals and periodontal pockets of non-vital teeth associated with advanced periodontitis," *International Endodontic Journal*, vol. 23, no. 2, pp. 100-106, 1990.
5. K. Kerekes and I. Olsen, "Similarities in the microfloras of root canals and deep periodontal pockets," *Dental Traumatology*, vol. 6, no. 1, pp. 1-5, 1990.
6. H. Li, R. Guan, J. Sun, and B. Hou, "Bacteria community study of combined periodontal-endodontic lesions using denaturing gradient gel electrophoresis and sequencing analysis," *Journal of Periodontology*, vol. 85, no. 10, pp. 1442-1449, 2014
7. Zehnder M, Gold SI, Hasselgren G. Pathologic interactions in pulpal and periodontal tissues. *J Clin Periodontol* 2002;29:663-71.
8. Sunitha VR, Emmadi P, Namasivayam A, Thyegarajan R, Rajaraman V. The periodontal endodontic continuum: A review. *J Conserv Dent* 2008;11:54-62.
9. Anand V., Govila V., Endo-Perio Lesion : Part I (The Pathogenesis) - A Review, *Archives of Dental Sciences* 2012;Volume3,Issue1.
10. Simon JH, Glick DH, Frank AL. The relationship of endodontic periodontic lesions. *J Periodontol*. 1972;43:202-208
11. Al-Fouzan KS. A new classification of endodontic-periodontal lesions. *Int J Dent*. 2014;2014:919173.
12. Von Arx T, Cochran DL. Rationale for the application of the GTR principle using a barrier membrane in endodontic surgery: A proposal of classification and literature review. *Int J Periodontics Restorative Dent* 2001;21:127-39.
13. Singh P. Endo perio dilemma: A brief review. *Dent Res J (Isfahan)* 2011;8:39-47
14. Rotstein I, Simon JH. The endo perio lesion: A critical appraisal of the disease condition. *Endod Top* 2006;13:34-56.
15. Meng HX. Periodontic-endodontic lesions. *Ann Periodontol*. 1999;4:84-90.
16. Chapple IL, Lumley PJ. The periodontal-endodontic interface. *Dent Update*. 1999;26:340-331. 331-336, 338.
17. Siqueira JF Jr, Lopes HP. Mechanisms of antimicrobial activity of calcium hydroxide: A critical review. *Int Endod J* 1999;32:361-9
18. Mhairi RW. The pathogenesis and treatment of endo perio lesions. *CPD Dent* 2001;2:77-104.
19. Fava LR, Saunders WP. Calcium hydroxide pastes: Classification and clinical indications. *Int Endod J* 1999;32:257-82.
20. Rehman K, Saunders WP, Foye RH, Sharkey SW. Calcium ion diffusion from calcium hydroxide containing materials in endodontically treated teeth: An in vitro study. *Int Endod J* 1996;29:271-9.
21. Lin YH, Mickel AK, Chogle S. Effectiveness of selected materials against *Enterococcus faecalis*: Part 3. The antibacterial effect of calcium hydroxide and chlorhexidine on *Enterococcus faecalis*. *J Endod* 2003;29:565-6.
22. Evanov C, Liewehr F, Buxton TB, Joyce AP. Antibacterial efficacy of calcium

- hydroxide and chlorhexidine gluconate irrigants at 37°C and 46°C. *J Endod* 2004;30:653 7.
23. Carrotte P. Endodontics: Part 9. Calcium hydroxide, root resorption, endo perio lesions. *Br Dent J* 2004;197:735 43.
  24. Paul BF, Hutter JW. The endodontic periodontal continuum revisited: New insights into etiology, diagnosis and treatment. *J Am Dent Assoc* 1997;128:1541 8.
  25. Chapple IL, Lumley PJ. The periodontal endodontic interface. *Dent Update* 1999;26:331 6, 338, 340.
  26. Blomlöf L, Lindskog S, Hammarström L. Influence of pulpal treatments on cell and tissue reactions in the marginal periodontium. *J Periodontol* 1988;59:577 83.
  27. Solomon C, Chalfin H, Kellert M, Weseley P. The endodontic periodontal lesion: A rational approach to treatment. *J Am Dent Assoc* 1995;126:473 9.
  28. Moule AJ, Kahler B. Diagnosis and management of teeth with vertical root fractures. *Aust Dent J* 1999;44:75 87
  29. Rotstein I, Simon JH. Diagnosis, prognosis and decision making in the treatment of combined periodontal endodontic lesions. *Periodontol* 2000 2004;34:165 203.
  30. Kim E, Song JS, Jung IY, Lee SJ, Kim S. Prospective clinical study evaluating endodontic microsurgery outcomes for cases with lesions of endodontic origin compared with cases with lesions of combined periodontal endodontic origin. *J Endod* 2008;34:546 51.
  31. John V, Warner NA, Blanchard SB. Periodontal endodontic interdisciplinary treatment: A case report. *Compend Contin Educ Dent* 2004;25:601 2,604.
  32. Bashutski JD, Wang HL. Periodontal and endodontic regeneration. *J Endod* 2009;35:321 8.
  33. Gottlow J, Nyman S, Lindhe J, Karring T, Wennstrom J. New attachment formation in the human periodontium by guided tissue regeneration: case reports. *J Clin Periodontol* 1986;13:604–6. 15. 34. Bowers GM, Chadroff B, Carnevale R, et al. Histologic evaluation of new attachment apparatus formation in humans: part II. *J Periodontol* 1989;60:675–82.
  34. Abramowitz PN, Rankow H, Trope M. Multidisciplinary approach to apical surgery in conjunction with the loss of buccal cortical plate. *Oral Surg Oral Med Oral Pathol* 1994;77:502–6.

# INFECTION CONTROL IN DENTISTRY POST COVID 19 : A REVIEW

## ABSTRACT

Dental professionals are exposed to a variety of infectious diseases through the microorganisms in blood and saliva. A proper infection control procedure helps in preventing cross contamination. All the dental technicians and personnel's should have a basic understanding about the transmission of infections. With the outbreak of COVID 19, all the sectors in the country are affected including dentistry. Since the transmission of the infection is airborne, there is a high risk for both the professionals and the patients. This article aims to provide a brief information regarding various measures to control the transmission of infection during COVID 19 pandemic.

**Keywords :** COVID 19, Dentistry, Infection control, Interleukins, Pathogenesis.

## Authors:

<sup>1</sup>Dr. M. S. Sreelekshmi

<sup>2</sup>Dr. Prabu P. S.

<sup>3</sup>Dr. Meenu Merry C. Paul

<sup>4</sup>Dr. Binsu Sukumaran

<sup>5</sup>Dr. Laju S.

<sup>6</sup>Dr. Rahul Das

<sup>1,6</sup>Post Graduate Student  
Department of Prosthodontics  
Malabar Dental College and Research Centre  
Manoor, Chekanoor Road Mudur (PO) Edappal,  
Malappuram District, Kerala, India.

<sup>2</sup>Professor and Head  
Department of Prosthodontics  
Malabar Dental College and Research Centre  
Manoor, Chekanoor Road Mudur (PO) Edappal,  
Malappuram District, Kerala, India.

<sup>3</sup>Principal  
Malabar Dental College and Research Centre  
Manoor, Chekanoor Road Mudur (PO) Edappal,  
Malappuram District, Kerala, India.

<sup>4,5</sup>Professor  
Department of Prosthodontics  
Malabar Dental College and Research Centre  
Manoor, Chekanoor Road Mudur (PO) Edappal,  
Malappuram District, Kerala, India.

## Address for correspondence

Dr. M. S. Sreelekshmi

Post Graduate Student

Department of Prosthodontics

Malabar Dental College and Research Centre

Manoor, Chekanoor Road Mudur (PO) Edappal,

Malappuram District, Kerala, India.

E mail: sreelekshmigk8@gmail.com

J Ind Dent Assoc Kochi 2020;2(4):18-25.

## INTRODUCTION

Infection is the multiplication and survival of microorganisms on or in the body. An infection does not always intricate a disease, but diseases seldom results without infection. Infection control is the prevention of multiplication and survival of microorganisms or in the body of living and non-living objects<sup>1</sup>. Blood and saliva are the major vectors in the spread of infectious diseases. Sterilization and disinfection basically deals with the prevention of spread of infection, in dentistry it relates to the proper cleaning and processing of the instruments and disinfection of the clinical areas<sup>2</sup>. Sterilization basically frees the surfaces from organism both in their vegetative as well as sporicidal form while disinfection kills the microorganism alone and not the spore forms<sup>2</sup>.

Dentistry is one major field where there is high risk of transmission of infection. Dental professionals are always exposed to variety of infectious and non-infectious agents through saliva and blood, aerosols produced and also reheating of local anesthetic needles also causes serious health hazards<sup>3</sup>. It is essential for all the dental clinic faculties to have an understanding about the different types of infectious diseases and to identify the rate of expose of the risk factor. The impressions, diagnostic instruments and even the dental chairs can transmits infection<sup>3</sup>.

The outbreak of Coronavirus disease 2019 (COVID 19) in China was sudden and became a major cause of health crisis and the spread became worldwide. Covid 19 has been declared as a pandemic in 11th March 2020, by the director general of World Health Organization. Severe acute respiratory syndrome coronavirus 2 (SARS-CoV-2) also known as coronavirus 2 belong to the family of single stranded RNA virus, with an asymptomatic incubation period of the between 2 and 12 days and may extend upto 24days<sup>4</sup>. Transmission is basically through direct contact or through droplet spread. The widespread transmission of infection to health professional had become a great concern especially for dentists where the treatment procedures involves is generation of large amount of aerosols<sup>4</sup>.

The most common symptoms includes fever, tiredness, dry cough, shortness of breath, sore throat, loss of taste and smell<sup>5</sup>. Chest X rays and computed tomography shows ground glass appearance of chest. 80% of cases are mild and recovers without needing special treatment. 15% of cases are categorised as severely ill and

the remaining 5% are categorised as critically ill<sup>6</sup>. Severe and critical cases can lead to pneumonia, kidney failure, and even death. Personal protective equipment's have become an important part in the prevention of COVID 19 cross infection. In case of improper infection control, the dental clinic itself can act as potential source of cross contamination<sup>7</sup>.

### Mechanism of Covid 19 invasion into host cell

Corona viruses are enveloped single stranded RNA viruses that infects a wide variety of host species. There are 5 steps in the life cycle of virus with the host<sup>8</sup>.

**Attachment** - virus binds to the receptors in the host cell.

**Penetration** - virus enters the host cell through endocytosis.

**Biosynthesis** - viral RNA enters the nucleus to make new viral proteins.

**Maturation** - synthesis of new viral particles.

**Release** - new viral particles are released.

Corona viruses have four structural proteins. They are Spike (S), Membrane (M), Envelop (E) and Nucleocapsid (N). Spike is made of trimetric glycoprotein and this determines the diversity of coronavirus and host tropism. It has 2 functional units: S1 & S2. S1 helps in binding of the virus to the receptors in host cell and S2 helps in the fusion of the virus with the cellular membrane. These corona virus also binds to angiotensin converting enzyme 2 (ACE2). Once the corona virus binds to the host cell, the spike protein undergoes a two-step protease cleavage and gets activated. The protease cleavage occurs at the S1/S2 cleavage site for priming and cleavage for the activation at the S2 site. Following the protease cleavage, S1/S2 cleavage site remains non covalently bonded and cleavage at the S2 site activates the spike for membrane fusion<sup>9</sup>.

### Host response to Coronavirus

The Computerized Tomography (CT) of an asymptomatic patient shows characteristic pulmonary ground glass appearance. The three main components for innate immunity are the dendritic cells, the alveolar macrophages and the epithelial cells. The antigenic presentation through dendritic cells and macrophages initiates T cell response. Coronavirus also binds with the dendritic cell specific intercellular

adhesion molecule-3-grabbing nonintegrin (DC-SIGN) and DC-SIGN-related protein (DC-SIGNR, L-SIGN) in addition to ACE2. CD4<sup>+</sup> and CD8<sup>+</sup> T cells plays an important role. CD4<sup>+</sup> T cells activates B cells which in turn causes the production of Virus specific antibodies and CD8<sup>+</sup> T cells kills the infected cells. In cases of severe disease, patient shows leukopenia and increased plasma concentration of proinflammatory cytokines, including interleukin (IL)-6, IL-10, granulocyte-colony stimulating factor (G-CSF), monocyte chemo attractant protein 1 (MCP1), macrophage inflammatory protein (MIP) 1 $\alpha$ , and tumour necrosis factor (TNF)- $\alpha$ . As the severity increases, the levels of IL 6 also increases. In patients with severe disease, aberrant pathogenic CD4<sup>+</sup> T cells with co - expressing interferon (IFN)- $\gamma$  and granulocyte-macrophage colony-stimulating factor (GM-CSF) are also seen; the lungs also shows infiltration of large number of inflammatory cells<sup>10</sup>.

### Pathogenesis of Covid 19

Based on the clinical stages of the, Covid 19 can be divided into three phases:

**Stage 1-** Asymptomatic phase

**Stage 2-** Upper airway and conducting airway response

**Stage 3-** Hypoxia, ground glass infiltrates and progression to ARDS

**Stage 1 -** Asymptomatic phase. This is the first 2 days of the infection. The virus enters the nasal cavity through inhalation, binds to the epithelial cells and undergoes replication. A limited innate immunity response occurs during this stage but local propagation of virus also occurs. During this stage, the virus can be detected through nasal swabs. The amount of virus present is low but the individuals are infectious<sup>11</sup>.

**Stage 2-** Upper airway and conducting airway response. The disease is clinically manifested during this stage. During this stage, the virus travels through the conducting airways and triggers the innate immunity response. Nasal swabs or sputum are considered as early markers of innate immunity response. The infected epithelial cells are the source of beta and lambda interferons. CXCL10 is one of the disease marker at this stage. For 80% of the individuals, the disease at this stage is mild and can be treated at home with conservative therapy<sup>11</sup>.

**Stage 3-** Hypoxia, ground glass infiltrates and

progression to ARDS. About 20% of the infected patients' progresses to this severe stage of the disease. In this stage, the virus reached the lungs and infects the alveolar type II cells which tends to be peripheral and subpleural. The disease progresses resulting in the release of large number of viral particles and the apoptosis and death of the cells occurs. The released viral particles infects the type II cells of the adjacent units. The end result is the alveolar damage with fibrin rich hyaline membranes and a few multinucleated giant cells and wound healing leads to severe scarring and fibrosis of the tissues. It is not safe to administer endothelial growth factors as they results in increase amount of virus by producing more ACE2 expressing cells. The elderly will be at risk as their ability to repair the damaged epithelium is reduced<sup>11</sup>.

### Disease transmission through air-borne route

The major route of spread of Covid 19 is through respiratory droplets or by contact. Dental professionals are one of the high risk categories for the transmission of the disease because of the specificity of the treatment procedures which includes frequent exposure with saliva, blood and also handling of infected sharp instruments. During treatment procedures like cavity preparation, tooth preparation and ultrasonic scaling, large amount of aerosols and droplets are produced that is mixed with patients' blood and saliva. The droplets produced are of two types, the larger droplets that settles down on the surfaces and the smaller droplets which remains in the air and enter the respiratory tract through inhalation. The droplets that settles down cause's contamination of the surfaces<sup>12</sup>.

### Laboratory testing guidelines for suspected cases of Covid 19

All health care personnel's who works in collecting the test samples must strictly follow the infection prevention and control guidelines<sup>12</sup>. The samples collected are the upper and lower respiratory specimens. The upper respiratory specimen includes the nasopharyngeal and oropharyngeal swabs while the lower respiratory specimen includes the sputum and endotracheal aspirants. Additional specimens includes blood and urine samples. In deceased individuals, autopsy of lung tissue can be taken. Specimens may be stored and shipped at a temperature of 2 to 8° C. in case of any delay in

transportation, the samples may be frozen at -20°C and shipped on dry ice<sup>13</sup>.

**Specific laboratory testing for diagnosis of Covid 19 includes:** Nucleic acid amplification tests (NAAT) for COVID-19 virus, serological testing, viral sequencing and viral culture<sup>13</sup>.

**Nucleic acid amplification tests (NAAT) for COVID-19 virus:** Confirmation of COVID-19 is based on detection of unique sequences of virus RNA by NAAT. RNA extraction should be done in a biosafety cabinet in a BSL-2 or equivalent facility. Heat treatment of samples prior to RNA extraction is not recommended<sup>14</sup>.

**Serological testing:** Aid investigation of an ongoing outbreak and retrospective assessment of the attack rate or extent of an outbreak. In cases where NAAT assays are negative and there is a strong epidemiological link to COVID-19 infection, paired serum samples (in the acute and convalescent phase) could support diagnosis once validated serology tests are available. Serum samples can be stored for these purposes<sup>14</sup>.

**Viral sequencing:** Regular sequencing of a percentage of specimens from clinical cases can be useful to monitor for viral genome mutations that might affect the performance of medical countermeasures. Virus whole genome sequencing can also inform molecular epidemiology studies.

**Viral culture:** this is not a routine diagnostic procedure<sup>14</sup>.

### Dental clinical setup

All the dental professionals need to update their knowledge about the infection control procedures for the proper prevention of spread of infection. They should be aware about the various ways by which the infection can spread<sup>15</sup>. Teledentistry plays a major role during this current pandemic situation. Tele screening of the patient is mandatory. The patient should be screened for any symptoms of Covid 19, whether there is any recent contact with the confirmed cases. Based on the screening, a decision should be made whether to call the patient for treatment or not. Each patient should be given a scheduled time for the treatment. Patient should be asked to arrive in the clinic at the time allotted for them, not too early not too late. Remove thing which cannot be disinfected easily which includes magazines and reading materials. Patients must be placed in an adequately ventilated waiting room<sup>15</sup>.

As soon as the patient enters the dental clinic,

the temperature of the patient should be recorded using a contact free infrared thermometer. Recording the temperature should be a part of the routine assessment of the patient. A proper questionnaire should be used to screen the patients which includes whether the patient had any fever or related symptoms within the past 14 days, whether they have come in contact with patients with confirmed Covid 19 disease within the past 14 days, whether they have travelled to any other state or country in the past 14 days or whether they have come in contact with people who came from other state or country within the past 14 days<sup>16</sup>. If the patient's body temperature is below 37.3°C and the answer to all these questions are no, the treatment can be started with proper precautions to avoid spread of aerosols<sup>16</sup>.

Dentist should make sure that they wash their hands before and after each procedure and also after touching the surfaces. Treatment should be completed in a single room with doors closed. Use proper isolation methods to decrease the spread of infection. Handpieces should be autoclaved after each patient<sup>17</sup>. The patient should use rinse with 1% hydrogen peroxide before the treatment procedure. All the instruments should be properly sterilized before proceeding with the treatment. Only essential staffs should enter the room. Avoid treatment procedures that causes generation of aerosols. If aerosol generating procedure is mandatory then use appropriate Personal Protection Equipment. Use of single patient treatment rooms with closed doors. Use of high volume evacuations to minimize the aerosol generation<sup>17</sup>.

### Personal Protective Equipment

During dental treatment, spread of droplets and aerosols which contains microorganisms occurs and they radiates towards the dentists face and body. Personal protection equipment acts as a barrier against these aerosols and droplets<sup>18</sup>. Personal protection equipment (PPE) is a collective term for equipment's worn by health professionals which act as a barrier to protect them from exposure to potentially infectious materials. The type of PPE selected is based on the risk and the procedures performed. It includes use of masks, gloves, protective eyewear, face shields and enclosed footwear. Proper donning and doffing protocol should be followed while using PPE<sup>18</sup>.

## Masks

Masks are used to prevent the spread of infectious respiratory aerosols between patients. There are different types of masks depending upon the risk of spread of infection. Medical masks which does not provide complete protection against small particle aerosols and must be replaced when it is wet or dirty<sup>19</sup>. Surgical masks prevents the large particles from reaching nose and mouth but does not protect individuals from the spread of airborne infectious agents as they does not seal against the skin of the face. Filtering face piece FFP2, FFP3, N95, N99 etc. are considered to be high performance filtering masks where filtration is achieved by a web of polypropylene microfibers and electrostatic charge. FFP3 is more effective than FFP2 and both of them are superior to N95 mask. FFP2 and FFP3 respirators are available as with and without valves. These valves just acts as regulators of airflow<sup>20</sup>.

## Goggles and face shields

Goggles are used for providing protection to eyes along with better peripheral vision. They provides better protection than eyeglasses and contact lenses<sup>20</sup>. Use of goggles can be alternated with the use of face shields which protects the face besides the eyes. It extends from the forehead to the chin, provides protection to face and eye. Disposable goggles and face shields are preferred. If using a reusable type, make sure to clean them after each patient<sup>21</sup>.

## Gowns

The use of gowns provides protection of the operator from infectious agents and also prevents the operator from becoming a carrier of infection. Disposable clothing's are mostly preferred. Additional disposable gowns can be worn depending upon the risk assessment or in cases where high contamination are expected. In case of using reusable gowns (fabric), they should be washed daily on a hot 60° cycle although they are not considered under PPE<sup>22</sup>.

Depending upon the risk of the infectious agents and the type of tissue being exposed different types of gowns are available. Waterproof and fluid resistant gowns can be worn while treating high risk cases. During surgical procedures, surgical gowns with tight cuffs are used which is inserted under the gloves.

Disposable head cap prevents hair fouling due to various contaminants, prevention of dispersion of dandruff to the operating surfaces and also burning of hair due to flames<sup>22</sup>.

## Gloves

During dental procedures, the dentist and the entire dental team must wear protective gloves because it is impossible to avoid contact of hands with blood and saliva<sup>23</sup>. They should be changed with each patients and when in contact with contaminated surfaces. Two categories of gloves are used in dental clinic: those used for treatment purposes and those for cleaning the instruments and the surfaces of the clinic. More durable gloves should be worn during cleaning of instruments to prevent injury<sup>23</sup>.

There are basically two types of gloves used: surgical gloves (sterile) and inspection gloves (non-sterile). Gloves can be made of latex, nitrile or vinyl. Gloves contains powders which makes them easier to wear. Some patients may be allergic to latex and some to the powder present in the gloves, in such cases, latex free gloves and powder free gloves can be used. For double protection, two pairs of gloves can be worn so that the passage of blood through micro perforations will be reduced<sup>23</sup>.

## Hand hygiene

Hand washing is mandatory in personal protection. Antimicrobial soaps kills the microorganisms. Surgical hand rub kills the transient organisms. There are different types of soaps available. Washing hands with plain soap removes dirt and microorganisms. Use of alcohol based hand rub kills microorganisms. Hands should be washes after each and every procedure, before gloves are put and after they have been removed. It is recommended to wash hands for a minimum of 60 seconds<sup>23</sup>. Alcohol containing hand washes and hand rubs are more preferred as they are more effective in killing the microorganisms. Cold water is preferred for washing as repeated use of hot water causes dermatitis. Before hand washing, all the ornaments should be removed and disposable paper towels can be used for drying hands. Alcohol based hand sanitizer containing 60% alcohol can be used as an alternative to hand washing with soap<sup>23</sup>.

## Sterilization of instruments

It is mandatory to clean and sterilise all the instruments before and after each patient. Before sterilisation instruments must be cleaned with water and soap. Autoclaving the instruments are the best method for sterilising the instruments. Those instruments that can-



not be autoclaved can be disinfected<sup>13</sup>. After sterilisation, instruments should be kept properly to avoid recontamination for approximately 30 days. An alternative for steam sterilisation is the use of chemical sterilisers that include use of ethylene oxide gas, formaldehyde gas, hydrogen peroxide gas, liquid peracetic acid or ozone. The commonly used disinfectants includes 70% alcohol, Chlorhexidine, 2% Glutaraldehyde, Hypochlorite<sup>13</sup>.

### Surface disinfection

There are two ways to keep the surface free from infection: to clean and disinfect the contaminated surfaces and to use covers to prevent the surface from getting contaminated. Sodium hypochlorite and phenolic compounds

can be used for disinfection of the surfaces<sup>26</sup>. After each treatment surfaces should be disinfected with either 70% ethyl alcohol or with 0.5% sodium hypochlorite (if pus or blood is present).

Ultraviolet C (UV-C) irradiation lamp can be used as an alternative to disinfection with chemical<sup>27</sup>. It does not require any ventilation, has a wide spectrum activity in a short time period and does not leave any residue. But this should be used only when the room is empty without any staff. UV-C degraded the acrylic material when exposed for a long period of time. They have a wavelength between 100 and 280nm which causes cell damage thus blocking cell replication<sup>28</sup>. They are generated by low pressure mercury lamps and pulsed xenon lamps with a higher germicidal action<sup>29</sup>. UV-C

## Instrument sterilisation procedures<sup>13</sup>

Instruments	Sterilisation procedures
Articulators	Cleaned using 70% ethyl alcohol
Burs-diamond	Autoclaved
Burs-steel tungsten-carbide	Dry heat sterilisation
Dental mirrors	Autoclave
Denture	Clean with detergent and water. If contaminated with blood, immerse in 0.1% sodium hypochlorite for 10 min and rinse
Extraction Forceps	Autoclave
Handpieces	Autoclave
Impressions–Alginate (plastic trays).	Spray with 0.1% sodium hypochlorite
Zinc-oxide eugenol paste	Spray with 0.1% sodium hypochlorite
Alginate (metallic tray)	Spray with 2% glutaraldehyde
Rubber base	Immerse in 2% glutaraldehyde
Instrument trays	Autoclave
Orthodontic bands	Autoclave
Polishing stones	Autoclave
Prophylactic cups and brushes	Disposable
Protective, plastic glasses and shields	Scrub with 0.1% sodium hypochlorite
Root canal instruments	Autoclave
Rubber dam clamps	
Rubber dam forceps	
Rubber dam punches	Clean with detergent and water
Stainless steel instruments	Autoclave
Suction tube adaptors	Wipe with 70% alcohol
Surgical instruments	Autoclave
Ultrasonic scalar tips and inserts	Autoclave

lights have the ability to block the light rays or allow itself to pass through for the irradiation of the objects. The amount of UV-C dose received determines the amount of inactivation of the microorganisms.

Dental chairs and dental service units should be cleaned with detergent and water. If there is any blood or pus, clean and disinfect with 0.5% sodium hypochlorite or 2% glutaraldehyde<sup>30</sup>.

### Dental unit waterlines (DUWLS)

Any failure to maintain the dental unit waterlines causes the growth of pathogens in the waterline. The biofilm formed on the internal surface of the water tubes are the surface for the growth of the pathogens. Draining of the water at the end of the day prevents the formation of the biofilm. The water flow and the filters in the DUWLS should be regularly checked and cleaned on a regular basis. If the filters used are disposable they should be replaced regularly<sup>30</sup>.

### Waste management

All the waste in the dental clinics must be categorized either as clinical or non-clinical waste. All sharp and pointed instruments should be disposed in a rigid container to avoid injury. Regular cleaning and proper disposal of the wastes for the proper prevention of infection transmission<sup>31</sup>.

### Other protection measures

Patient is asked to keep their hands in pocket and to avoid touching the surfaces of the dental clinics. The use of rubber dams minimises the production and splatter of blood and saliva. After each session the rooms should be cleaned, floor should be mopped. All the instruments should be properly autoclaved and kept in pouches. Impressions should be properly disinfected with glutaraldehyde solution before dispatching to lab. Fumigating daily with quaternary ammonium compounds<sup>31</sup>.

### CONCLUSION

Dentists are at higher risk of exposure of infectious diseases. During the progressive spread of COVID 19 pandemic, it is important for all the

dental health professionals to incorporate all the routine precautionary measures for their personal safety as well as the safety of their patients<sup>12</sup>. Every patient must be considered either as an infected patient or as a carrier and a proper history must be recorded. A regular update about the recent advances in infection control and also train the staffs to promote the screening and preventive measures. The use of PPE does reduce the rate of cross infection. A better understanding about aerosol spread can be very helpful also to help avoid any mistakes that can occur during routine diagnosis<sup>23</sup>.

### REFERENCES

1. Baveja CP. Textbook of microbiology for dental students. Arya; 2006.
2. Ananthanarayanan R, Panicker CK. Textbook of microbiology: 9th edition 2009.
3. Sumanth KS, Shwetha P, Gautham S. Infection control protocol in prosthodontics- a review. 2018 March 8(3):1-3.
4. Alharbi A, Alharbi S, Alqaidi S. Guidelines for dental care provision during the COVID-19 pandemic. The Saudi Dental Journal. 2020 Apr 7.
5. Devidas KP. Managing the Pandemic: COVID-19, Precautions and Protections in dental Practice.
6. Li R W, Leung K W C, Sun F C S, Samaranayake L P. Severe Acute Respiratory Syndrome (SARS) and the GDP. Part II: Implications for GDPs. Br Dent J 2004; 197: 130-134.
7. Peng X, Xu X, Li Y, Cheng L, Zhou X, Ren B. Transmission routes of 2019-nCoV and controls in dental practice. Int J Oral Sci 2020; 12:
8. Mason RJ. Pathogenesis of COVID-19 from a cell biology perspective.
9. Yuki K, Fujiogi M, Koutsogiannaki S. COVID-19 pathophysiology: A review. Clinical immunology. 2020 Apr 20:108427.
10. Rothan HA, Byrareddy SN. The epidemiology and pathogenesis of coronavirus disease (COVID-19) outbreak. Journal of autoimmunity. 2020 Feb 26:102433.
11. .Sekhsaria S, Sharma A, Tiwari B, Sharma

- A, Mahajan T. Changing paradigm in prosthodontics practice post COVID-19 outbreak.
12. Mishra K, Hegde D, Shetty S, Shah S, Priya A, Reddy SL. Coronavirus Disease 19 (COVID-19) and Prosthodontic Consideration-A. *Journal of Advanced Medical and Dental Sciences Research*. 2020 May;8(5).
  13. Bizzoca ME, Campisi G, Muzio LL. Covid-19 Pandemic: What Changes for Dentists and Oral Medicine Experts? A Narrative Review and Novel Approaches to Infection Containment. *International Journal of Environmental Research and Public Health*. 2020 Jan;17(11):3793.
  14. Bhanushali P, Katge F, Deshpande S, Chimata VK, Shetty S, Pradhan D. COVID-19: Changing Trends and Its Impact on Future of Dentistry. *International Journal of Dentistry*. 2020 May 29;2020.
  15. Checchi V, Bellini P, Bencivenni D, Consolo U. COVID-19 dentistry-related aspects: a literature overview. *International dental journal*. 2020 Jul 5.
  16. Peng X, Xu X, Li Y et al. Transmission routes of 2019-nCoV and controls in dental practice. *Int J Oral Sci* 2020 12:9.
  17. Checchi L, Montebugnoli L, Samaritani S. Contamination of the turbine air chamber: a risk of cross infection. *J Clin Periodontol* 1998 25: 607–611.
  18. Qureshi Z, Yassin MH. Role of ultraviolet (UV) disinfection in infection control and environmental cleaning. *Infect Disord Drug Targets* 2013 13: 191–195.
  19. Checchi L, Montebugnoli L, Samaritani S. Contamination of the turbine air chamber: a risk of cross infection. *J Clin Periodontol* 1998 25: 607–611.
  20. Hillier MD. Using effective hand hygiene practice to prevent and control infection. *Nurs Stand* 2020 35: 45–50.
  21. Lindblad, M.; Tano, E.; Lindahl, C.; Huss, F. Ultraviolet-C decontamination of a hospital room: Amount of UV light needed. *Burns* 2019.
  22. Ather A, Patel B, Ruparel NB, Diogenes A, Hargreaves KM. Coronavirus disease 19 (COVID-19): implications for clinical dental care. *Journal of endodontics*. 2020 Apr 6.
  23. Ge ZY, Yang LM, Xia JJ, Fu XH, Zhang YZ. Possible aerosol transmission of COVID-19 and special precautions in dentistry. *Journal of Zhejiang University-SCIENCE B*. 2020 Mar 16:1-8.
  24. Kochhar AS, Bhasin R, Kochhar GK, Dadlani H. COVID-19 Pandemic and Dental Practice. *International Journal of Dentistry*. 2020 Jul 9;2020.
  25. Gamage B, Moore D, Copes R, Yassi A, Bryce E, BC Interdisciplinary Respiratory Protection Study Group. Protecting health care workers from SARS and other respiratory pathogens: a review of the infection control literature. *American journal of infection control*. 2005 Mar 1;33(2):114-21.
  26. Harrel SK, Molinari J. Aerosols and splatter in dentistry: a brief review of the literature and infection control implications. *The Journal of the American Dental Association*. 2004 Apr 1;135(4):429-37.
  27. Kumar GA, Mohan R, Hiremutt DR, Vikhram KB. COVID-19 pandemic and safe dental practice: Need of the hour. *Journal of Indian Academy of Oral Medicine and Radiology*. 2020 Apr 1;32(2):164.
  28. Harrel SK 1, Molinari J. Aerosols and splatter in dentistry: a brief review of the literature and infection control implications. *J Am Dent Assoc*. 2004 Apr;135(4):42937.
  29. Micik RE, Miller RL, Mazzarella MA, Ryge G. Studies on dental aerobiology, I: bacterial aerosols generated during dental procedures. *J Dent Res* 1969;48(1):49-56.
  30. Micik RE, Miller RL, Leong AC. Studies on dental aerobiology, 3: efficacy of surgical masks in protecting dental personnel from airborne bacterial particles. *J Dent Res* 1971;50:626-30.
  31. World Health Organization. Laboratory testing for coronavirus disease 2019 (COVID-19) in suspected human cases: interim guidance, 2 March 2020. World Health Organization; 2020.

# FIRE SAFETY IN DENTAL PRACTICE

## ABSTRACT

The prerequisite of running successful dental practice is to manage dental clinic without any impediments. Along with learning cognitive, clinical and communication skills in dentistry dentist should possess cognizance of safety measures and handling of emergencies which are decisive part of dental practice management. From the establishing to coordinating the dental practice, ample investment of resources are put together which are expected to be safeguarded in the event of any disasters. Fire mishaps are perceived to be pertinent risk in the present-day dental practice. Scrupulous knowledge of safety measures is indeed indispensable in handling of fire mishaps or crisis in dental clinic.

**Keywords:** Fire safety, fire extinguisher, types of fire

## Author:

<sup>1</sup>Dr. Suma B. Satenahalli

<sup>2</sup>Dr. Mahesh Hiregoudar

<sup>3</sup>Dr. Anand Patil

<sup>4</sup>Dr. Subhashgouda Patil

<sup>1</sup>Senior Lecturer

Department of Pedodontics  
Al-Badar Dental College & Hospital  
Gulbarga, Karnataka, India

<sup>2</sup>Reader

Department of Public Health Dentistry  
Al-Badar Dental College & Hospital  
Gulbarga, Karnataka, India

<sup>3</sup>Reader

Department of Conservative  
Dentistry and Endodontics  
HKDET Dental College  
Humnabad, Bidar, Karnataka, India

<sup>4</sup>Reader

Department of Public Health Dentistry  
HKE's S.N Institute of Dental Science  
Gulbarga, Karnataka, India

## Address for correspondence

Dr. Mahesh Hiregoudar

Reader

Department of Public Health Dentistry  
Al-Badar Dental College & Hospital  
Gulbarga, Karnataka, India

E mail: maheshiregoudar@gmail.com

J Ind Dent Assoc Kochi 2020;2(4):26-9.

## INTRODUCTION

Fire in the dental office/clinic can be a small accident to life-threatening emergency that leads to property damage and loss of human life/lives. In order to prevent and handle the fire accidents quickly, efficiently dentist and team must understand basic concepts of fire and its management in dental setup. At present throughout country it is mandatory to register our dental clinic and obtained license to practice from the local authorities. In order to register one must fulfill fire safety norms and criteria prescribed by the government bodies. Lamentably dental practitioners and institutions approach towards fire safety is indifferent and neglected.

## PARADIGM OF FIRE TRIANGLE

Fire is a form of a chemical reaction that involves the rapid oxidation of combustible fuel (material) with the subsequent liberation of heat smoke and light engendering to carbonizing of affected area of the clinic. The presence and interaction of three main components i.e. combustible fuel, presence of oxygen and source of ignition, leads to fire or explosion accidents in the dental clinic. The paradigm of three components referred to as the "fire triangle"<sup>1</sup>.

## COMPONENTS OF FIRE TRIANGLE

The first component is a fuel, commonly is any combustible material that can be used as the source of ignition of the fire, includes aerosol sprays, torch, prepping agents, drapes, towels, sponges, dressings, tapes, gowns, hoods, masks, ointments, benzoin, electric wires, waxes, alcohol and LPG used in labs etc. can be enlisted in the dental setup.

Oxygen is an oxidizing agent that reacts with the fuel to start and continue the fire. Common oxidizers are room air, oxygen, nitrous oxide etc.

Third necessary component is ignition sources or heat, which includes light/heating electric source, laser, electro-cautery, sparks from high-speed drills and burrs, charred tissue etc.<sup>2</sup>

## DIFFERENT CLASSES OF FIRES

Based on the types of contributing fuel/ com-

busion materials, there are five classes of fires that are categorized.<sup>3,4</sup>

**Class A:** Fires involving ordinary combustible materials such as wood, cloth, paper, rubber, and many plastics.

**Class B:** Fires involving inflammable/combustible liquids, such as petroleum greases, tars, oils, oil-based paints, solvents, lacquers, alcohols, and flammable gases.

**Class C:** Fires involving electrical equipment, such as power tools, wiring, fuse boxes, appliances, TVs, computers, and electrical motors.

**Class D:** Fires involving combustible metals such as magnesium, potassium, titanium, zirconium, lithium, and sodium.

**Class K:** Fires involving combustible cooking oils and fats used in commercial cooking equipment.

Fire accidents in dental clinics commonly attributed to A, B and C classes of fires, as combustibles required are often found in dental setup and utilized in dental practices.

## Fire safety in dental practice

The disasters related to fire are complex, unexpected and immediate situations in which the consequences are beyond the anticipation to respond effectively and neutralize entirely. The fire disasters in the dental practice could be managed formally by preparing dental setup beforehand, mitigating the risk and responding in case of disaster. This disaster management cycle of preparedness, mitigation and response can be rephrased as prevention, suppression and evacuation in case fire management.<sup>5</sup>

## Preparedness or prevention

The preparedness begins with incorporation of fire safety measures and guidelines specified by the local authorities, while constructing new buildings and modifications/renovations in existing buildings. Installation of smoke sensors, heat sensors, smoke alarm, and water sprinkler system<sup>6</sup>, identifying the evacuation route, proper electric networking and routine inspections are few measures to curtail the risk of fire. Further to minimize fire mishap extensive usage of fire proof materials, appliances

and equipment's in setting up of dental clinic. The safety attained also by relevant signboards, securing enough fire neutralizing agents, placing in appropriate places, rigorous training of dental team and conducting regular fire drills.

### Mitigation or suppression

In order to abrogate, the small and controllable fire accidents, fire neutralizing systems or agents are intended to be in action such as heat or smoke sensor, water sprinkler system, fire extinguishers. By controlling small fire at earliest can save life/lives, check the physical and monetary losses. The small fires usually arising out of chair side procedures such as usage of electric, electronic appliances, charred tissues, burner/torches and chemicals used for dental procedures and disinfection can be prevented by thorough knowledge about fire mechanism, timely decision and disengaging the components of fire triangles. The dentist and his/her team should have basic knowledge about origin of fire, different class of fire, and appropriate fire extinguishers to be used.

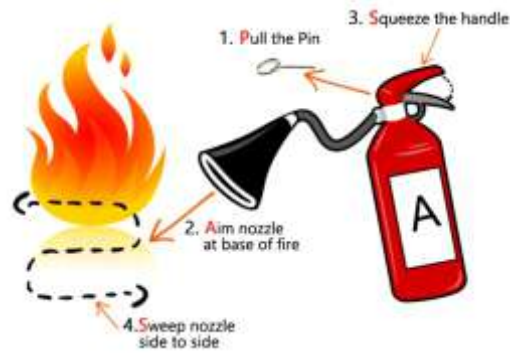
**Table 1: Different classes of fires and fire extinguishers**

#### Type of extinguishers and the classes of fire<sup>4,7</sup>

Class of Fire	Neutralizing agent
Class A fire	Water
Class B & C fire	Dry chemical powder
Class A & B fire	Foam
Class B & C fire	Carbon dioxide
Class D fire	Special dry powder

When using fire extinguishers, team should employ the “PASS” method; **P**: Pull the pin on the extinguisher, **A**: Aim at the base of the fire, **S**: Squeeze the handle, **S**: Sweep at the fire, moving from side to side.

To alleviate the uncontrolled and large fire accidents, actuate fire alarm to signal out, evacuate patient and team from the affected area, and call for external help. In the large fire, heavy smoke can lead to decreased oxygen supply and toxic inhalation of smoke, hence dental



**Figure 1:**  
Showing how to use Fire Extinguishers

clinic should be equipped with smoke masks. In such situations assembly and direction of evacuation should be mentioned on the floors of the clinic.

The fire safety training of dental team is very vital to minimize the risk and effect of fire and following are the topics to be trained under;<sup>8</sup>

- Blue print of dental clinic area and building.
- Fire warning systems; Smoke & heat sensors, smoke alarm, water sprinkler.
- Action on detecting fire.
- Action on hearing fire alarm.
- Location of nearest fire equipment ex. fire extinguisher and alarm point.
- Assembly point of evacuation and signboards.
- Keeping exit ways/ evacuation ways without obstructions.
- Importance of closing fire doors.
- First aid care for burns.

### REFERENCES

- Blazquez E, Thorn C. Fires and explosions. *Anaesthesia & Intensive Care Medicine*. 2010 Nov 1;11(11):455-7.
- Stuart R. Hart, MD, Amit Yajnik, MD, Jeffrey Ashford, RN, Randy Springer, Sherry Harvey, RN, Operating Room Fire Safety. *Ochsner J*. 2011,11(1):37-42.
- Nimlyat PS, Audu AU, Ola-Adisa EO, Gwatau D. An evaluation of fire safety measures in high-rise buildings in Nigeria.

- Sustainable Cities and Society. 2017 Nov;35:774-85.
4. Indian Standard: SELECTION, INSTALLATION AND MAINTENANCE OF FIRST-AID FIRE EXTINGUISHERS-CODE OF PRACTICE [Internet]. [cited 2020 Nov 3]. Available from: <https://law.resource.org/pub/in/bis/S03/is.2190.2010.html>
  5. Malilay J, Heumann M, Perrotta D, Wolkin AF, Schnall AH, Podgornik MN, et al. The Role of Applied Epidemiology Methods in the Disaster Management Cycle. *Am J Public Health*. 2014 Nov;104(11):2092-102.
  6. Amintabish S. Fire safety in health care facilities. *J Acad Hosp Adm*. 1997 Jul;9(2):55-62.
  7. Kalyana Chakravarthy Pentapati, Meena Anand Kukkamalla, Tina Puthen Purayil. Fire safety in dental clinics: Basics for dentists and dental students. *Journal of Dental Research and Review* 2015, 2( 2), 102-03.
  8. FSF - Fire Safety Manual.pdf [Internet]. [cited 2020 Nov 3]. Available from: <http://www.firesafetyfirst.co.uk/publications/FSF%20-%20Fire%20Safety%20Manual.pdf>

# MAXILLARY EXPANSION - A REVIEW

## ABSTRACT

A major portion of the treatment rendered in any orthodontic practice is concerned with lack of space – the transverse and sagittal crowding of teeth within the alveolus. Expansion is a conservative choice of treatment in treating space discrepancy in transverse dimension. Expansion can be Passive, Orthopaedic or Orthodontic based on the mode of force application and can Slow or Rapid based on the rate of expansion. Surgically assisted rapid palatal expansion (SARPE) has gradually gained popularity as a treatment option to correct maxillary transverse deficiency in adult patients. Miniscrew-assisted rapid palatal expansion (MARPE) was devised and used to treat adult patient with severe transverse discrepancy nonsurgically. Alternative Rapid Maxillary Expansion and Constriction (Alt-RAMEC) procedure introduced by Liou has been introduced in 2019 to improve the effectiveness of the maxillae relative to the surrounding sutures and the enhancement of the maxillae. With patient cooperation, expansion of the dental arches has yielded good results.

**Keywords:** Rapid maxillary expansion, mini screws, Alt RAMEC.

## Author:

<sup>1</sup>Dr. Archana Mohan

<sup>2</sup>Anshad Nazarudheen

<sup>3</sup>Dr. Sahal Abu

<sup>1</sup>Consultant Orthodontist  
Kozhikode, Kerala

<sup>2</sup>Undergraduate Student  
Indira Gandhi Institute  
of Dental Sciences  
Nellikuzhi P.O.  
Kothamangalam 686691, Kerala

<sup>3</sup>Private Dental Practitioner  
Kothamangalam 686691, Kerala

**Address for correspondence**  
Dr. Archana Mohan  
Palathpost, Kakkodi  
Kozhikode, Kerala 673611  
E mail: [achuveluthure@gmail.com](mailto:achuveluthure@gmail.com)



## INTRODUCTION

A major portion of the treatment rendered in any orthodontic practice is concerned with lack of space – the transverse and sagittal crowding of teeth within the alveolus. Orthodontic philosophies over the years have vacillated between a strict non-extraction approach and an approach, which requires extraction of teeth.<sup>1</sup> Angle believed that ideal occlusion requires a full complement of teeth and each tooth shall be made to occupy its normal position in the arch to achieve maximum functional efficiency and to ensure a permanent result.<sup>2</sup> Thus, Palatal expansion to such a degree as to accommodate a full complement of teeth was thought to be the only way to ensure treatment stability.

## TYPES OF EXPANSION

### Passive expansion

When the forces of the buccal and labial musculature are shielded from occlusion and when there is no application of extrinsic biomechanical forces but rather intrinsic forces such as those produced by the tongue.(Fig 1)

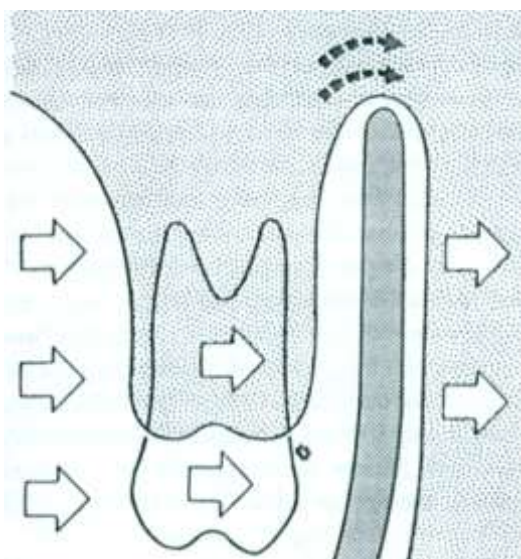


Figure 1- Passive expansion

McNamara JA, Brudon WL, Kokich VG. Orthodontics and dentofacial orthopedics. Ann Arbor, Mich: Needham Press; 2001.

### Orthodontic expansion

It produces lateral movement of posterior segments with labial/buccal tipping of crown and lingual tipping of root. The forces of cheek musculature still remain, providing a force that may lead to relapse or rebound of the achieved orthodontic expansion.(Fig 2)

### Orthopaedic expansion

The term orthopaedic has been introduced to describe those procedures developed to change the relationship of bones to facilitate the correction of malocclusion.<sup>3</sup> (Fig 3) In true orthope-

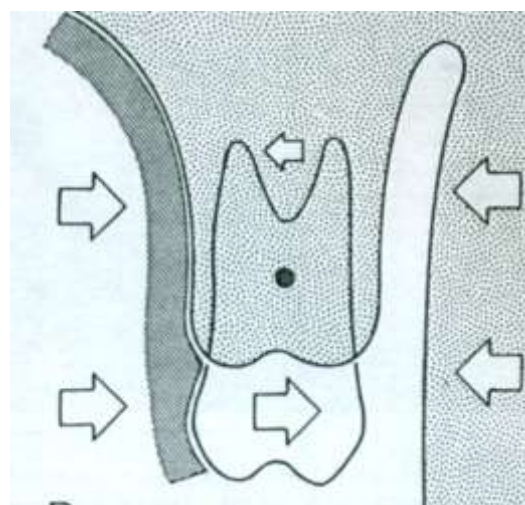


Figure 2- Orthodontic expansion (McNamara JA, Brudon WL, Kokich VG. Orthodontics and dentofacial orthopedics. Ann Arbor, Mich: Needham Press; 2001).

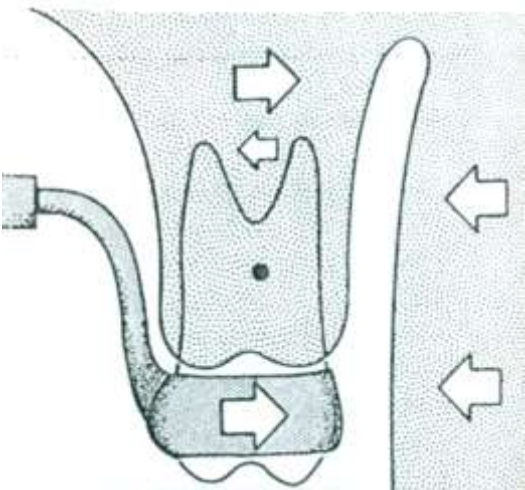


Figure 3-Orthopaedic expansion

(McNamara JA, Brudon WL, Kokich VG. Orthodontics and dentofacial orthopedics. Ann Arbor, Mich: Needham Press; 2001.)

dic expansion, changes are produced primarily in the underlying skeletal structure rather than by the movement of teeth through alveolar bone. Orthopaedic expansion not only separates the midpalatal suture but also affects the circumzygomatic and circum maxillary sutural systems.<sup>4</sup>

### Slow maxillary expansion (SME)

It is a form of dentoalveolar expansion which involves increase of arch width by movement of few teeth or many teeth. The results are more stable, when the maxillary arch is expanded slowly at a rate of 0.5 - 1 mm per week. The forces generated is much lower 2-4 pounds. Slow expansion may take as much as 2-5 month.<sup>2</sup> Slow palatal expansion is mainly achieved by the use of removable expanders eg Quad Helix, W-arch, Coffin spring, Ni-Ti expander, Schwarz appliance, Crozat appliance.

### Rapid maxillary expansion (RME)

It is a skeletal type of expansion that involves the separation of the mid-palatal suture and movement of the maxillary shelves away from each other. RME expands at rate of 0.5mm or more/day Its indication includes correction of cross bite, addition of arch length, correction of axial inclination of posterior teeth, spontaneous correction of classII malocclusion, reduction of nasal resistance ,broadening of smile and cleft palate with collapsed arch.<sup>5</sup> They can

be Banded or Bonded RME appliances. Eg: Derichsweiler, Haas, Isaacson and Hyrax type.<sup>3</sup>

### Surgically Assisted Rapid Palatal Expansion (SARPE)

Correction of maxillary transverse deficiency in a skeletally mature patient is more challenging because of changes in the osseous articulations of the maxilla with the adjoining bones. Surgically assisted rapid palatal expansion (SARPE) has gradually gained popularity as a treatment option to correct maxillary transverse deficiency in adult patients. Palatal osteotomy is done in patients who are above the age of 25 years or younger if rapid maxillary expansion has been tried and has failed.<sup>6</sup>

### Miniscrew Assisted Rapid Palatal Expansion (MARPE)<sup>7</sup>

Nonsurgical maxillary expansion helps to avoid a 2-stage surgical procedure surgically assisted rapid palatal expansion followed by orthognathic surgery and detrimental periodontal effects and relapse. So a miniscrew - assisted rapid palatal expansion was devised and used to treat adult patient with severe transverse discrepancy. (Fig4)

### Alt-RAMEC

Alternative Rapid Maxillary Expansion and Constriction (Alt-RAMEC) procedure introduced by Liou, which improves the effective-

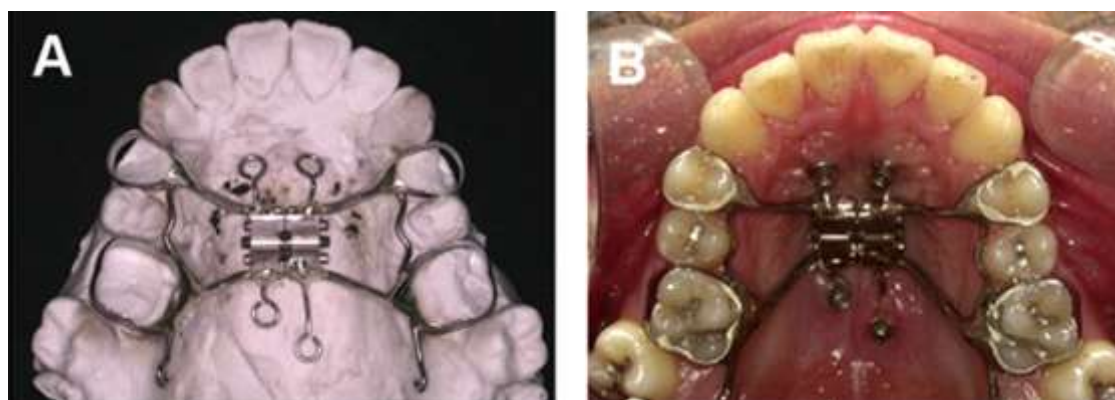


Figure 4-Miniscrew-assisted rapid palatal expansion

(Miniscrew-assisted nonsurgical palatal expansion before orthognathic surgery for a patient with severe mandibular prognathism. Am J Orthod Dentofacial Orthop 2010;137:830-9)

ness of the maxillae relative to the surrounding sutures and the enhancement of the maxillae. In the Alt-RAMEC protocol, maxillae will be enlarged 1 mm per day, first enlarged to 7 mm, and then the 1 mm screw is closed. In other weeks, in this order the screw of the expansion device is turned on for one week and then closed for one week, completing the Alt-RAMEC protocol at the end of the 9-week process. Alt-RAMEC procedure, a method commonly used in the treatment of class III malocclusion.<sup>8</sup>

## DISCUSSION

The first palatal expansion appliance was developed by Angell in 1860.<sup>9</sup> The objective of maxillary expansion is to increase the transverse width of the maxillary dental arch at the apical base with minimal concomitant movement of the posterior teeth within the alveolus. The maxilla can be considered as a bone held within the facial area of the skull by a series of calcified bony interdigitations, some of which are permanently connected to other bones of the cranium, such as the frontal, zygomatic, and palatal bones, by connective tissue fibers which form the suture system. The expansion by these expansion appliances has been related to orthodontic or orthopedic effect. Upon the application of transverse forces, initial changes produce lateral tipping of the posterior maxillary teeth due to controlled orthodontic movements when the compressed buccal alveolar plate resorbs at the root periodontal ligament interface as a result of continued force application.<sup>10</sup> If the applied transverse forces are of sufficient magnitude, movement and expansion of maxillary segments can occur.<sup>3</sup>

RME has been used extensively in arch expansion<sup>11,12</sup> but limitations associated with it includes bite opening,<sup>13</sup> relapse,<sup>14</sup> microtrauma of the temporomandibular joint and the midpalatal suture, root resorption,<sup>15,16</sup> tissue impingement and pain, and excessive tipping of anchorage teeth.<sup>17</sup> Martina et al demonstrated that SME is as effective as RME in determining skeletal transverse expansion of the maxilla in patients with posterior crossbite. Slow maxillary expansion may be preferred to rapid maxillary expansion because of the

reduced pain and discomfort.<sup>18</sup> This was favoured by Isaacson and Zimring suggesting that slower rates of expansion would allow for a physiologic adjustment at the maxillary articulations and would prevent the accumulation of large residual loads within the maxillary complex.<sup>19,20</sup> SME procedures produce less tissue resistance around the circummaxillary structures and, therefore, improve bone formation in the intermaxillary suture, which theoretically should eliminate or reduce the limitations of RME. Fabio et al claimed that long term results yielded by RME and SME were similar, and it can be assumed that a certain degree of skeletal maxillary constriction can be compensated with buccal tipping of posterior teeth when correcting posterior crossbite.<sup>21</sup> But in contrary Juliana et al observed that both treatment approaches were able to make some changes, especially at dental level, but RME generated greater changes.<sup>22</sup> Gray et al claimed an increase in the width of the nasal cavity immediately following expansion thereby improving breathing capacity.<sup>23</sup> An RME procedure separates the external walls of the nasal cavity laterally and causes lowering of the palatal vault and straightening of the nasal septum.<sup>24</sup> This remodeling decreases nasal resistance, increases internasal capacity, and improves breathing.

Isaacson et al showed that the facial skeleton increases its resistance to expansion as it ages and matures.<sup>25</sup> After sutural closure or completion of skeletal maturation, expansion without surgery causes less bony displacement and more dentoalveolar movement. This can lead to many problems in adults, including pain upon activation of the appliance, extrusion of the teeth, and periodontal complications. Therefore, large transverse discrepancies in adults are corrected preferably through Surgically assisted rapid palatal expansion (SARPE) to overcome the resistance of maturing suture. Socuci et al found that the dentoalveolar responses with RME and SARPE are similar after orthodontic treatment.<sup>26</sup>

In 2010, Lee et al treated a 20-year old patient with severe transverse discrepancy and mandibular prognathism. Before orthognathic surgery, the patient used an expansion appliance secured to the palate by means of miniscrews (miniscrew-assisted rapid palatal expander, or

MARPE). Expansion was achieved with minimal damage to teeth and periodontium, with stable outcomes confirmed by clinical and radiographic examination. The authors concluded that it is an effective treatment modality used for transverse correction and which might eliminate the need for a few surgical procedures in patients with craniofacial discrepancies, thus taking advantage of the possibilities offered by the sutures.<sup>27</sup>

## CONCLUSION

With patient cooperation, expansion of the dental arches has yielded good results. As with any form of therapy there are contraindications, occasional unfavorable responses and at times partial success. Nevertheless when properly used, expansion is of great value in treating malocclusion.

## REFERENCES

1. Timms DJ. Rapid maxillary expansion in the treatment of nocturnal enuresis. *Ang Orthod.* 1990 Sep;60(3):229-33.
2. Proffit WR, Fields Jr HW, Sarver DM. *Contemporary orthodontics.* Elsevier Health Sciences; 2006 Dec 8.
3. McNamara JA, Brudon WL, Kokich VG. *Orthodontics and dentofacial orthopedics.* Ann Arbor, Mich: Needham Press; 2001.
4. Starnbach H, Bayne D, Cleall J, Subtelny JD. Facioskeletal and dental changes resulting from rapid maxillary expansion. *The Angle Orthodontist.* 1966 Apr;36(2):152-64.
5. Andrew Hass and Cuyahoga Falls. Rapid expansion of the maxillary dental arch and nasal cavity by opening the midpalatal suture. *Am J. Orthod* 1961; 31(2):73-90
6. Lokesh suri, Parul Taneja. Surgically assisted rapid palatal expansion: *Am J Orthod Dentofacial Orthop* 2008; 133:290-302.
7. Lee KJ, Park YC, Park JY, Hwang WS. Miniscrew-assisted nonsurgical palatal expansion before orthognathic surgery for a patient with severe mandibular prognathism. *American Journal of Orthodontics and Dentofacial Orthopedics.* 2010 Jun 1;137(6):830-9
8. Büyükçavuş MH. Alternate Rapid Maxillary Expansion and Constriction (Alt-RAMEC) protocol: A Comprehensive Literature Review. *Turkish journal of orthodontics.* 2019 Mar;32(1):47.
9. Angell EC. Treatment of irregularities of the permanent or adult teeth. Part 1. *Dent Cosmos.* 1860;1(10):541-4.
10. Krebs A. Expansion of the midpalatal suture studied by means of metallic implants. *Acta Odont Scand.*1959;17:491-501. (As cited by Robert A. Wertz. Changes in nasal airflow incident to rapid maxillary expansion. *Am J. Orthod* 1968; 38:1-11)
11. Harrison JE, Ashby D. Orthodontic treatment for posterior crossbites. *Cochrane Database Syst Rev* 2001(1):CD000979.
12. McNamara JA Jr, Baccetti T, Franchi L, Herberger TA. Rapid maxillary expansion followed by fixed appliances: a long-term evaluation of changes in arch dimensions. *Angle Orthod* 2003;73(4):344-53
13. 5. Chang JY, McNamara JA Jr, Herberger TA. A longitudinal study of skeletal side effects induced by rapid maxillary expansion. *Am JOrthod Dentofacial Orthop* 1997;112(3):330-7.
14. Timms DJ. An occlusal analysis of lateral maxillary expansion with midpalatal suture opening. *Dent Pract Dent Rec* 1968;18(12):435-41
15. Darendeliler MA, Strahm C, Joho JP. Light maxillary expansion forces with the magnetic expansion device: a preliminary investigation. *Eur J Orthod* 1994;16(6):479-90
16. Akkaya S, Lorenzon S, Ucem TT. Comparison of dental arch and arch perimeter changes between bonded rapid and slow maxillary expansion procedures. *Eur J Orthod* 1998;20(3):255-61.
17. Capelozza Filho L, Cardoso Neto J, da Silva

- Filho OG, Ursi WJ. Non-surgically assisted rapid maxillary expansion in adults. *Int J Adult OrthodonOrthognathSurg* 1996;11(1):57-66; discussion 67-70.
18. Martina R, Cioffi I, Farella M, Leone P, Manzo P, Matarese G, Portelli M, Nucera R, Cordasco G. Transverse changes determined by rapid and slow maxillary expansion—a low-dose CT-based randomized controlled trial. *Orthodontics & craniofacial research*. 2012 Aug;15(3):159-68.
19. Isaacson R.J, Jack L. Wood and Arthur H. Ingram. Forces produced by rapid maxillary expansion - I. Design of the force measuring system. *Am J. Orthod* 1964; 34:256-260
20. Zimring J.F. and Isaacson R.J. Forces produced by rapid maxillary expansion III. Forces present during retention. *Am J. Ortho* 1965; 35:178-186.
21. Pinheiro FH, Garib DG, Janson G, Bombonatti R, Freitas MR. Longitudinal stability of rapid and slow maxillary expansion. *Dental press journal of orthodontics*. 2014 Dec;19(6):70-7.
22. Pereira JD, Jacob HB, Locks A, Brunetto M, Ribeiro GL. Evaluation of the rapid and slow maxillary expansion using cone-beam computed tomography: a randomized clinical trial. *Dental Press Journal of Orthodontics*. 2017 Apr;22(2):61-8.
23. Gray LP. Results of 310 cases of rapid maxillary expansion selected for medical reasons. *J LaryngolOtol* 1975 Jun;89(6):601-614.
24. Cameron CG, Franchi L, Baccetti T, McNamara Jr JA. Long-term effects of rapid maxillary expansion: a posteroanterior cephalometric evaluation. *Am J Orthod Dentofacial Orthop*. 2002;121(2):129-35
25. Isaacson R.J and Ingram A.H. Forces present during treatment II. *Am J. Orthod* 1964; 34 (4):261-270
26. Sokucu O, Kosger HH, Bıçakcı AA, Babacan H. Stability in dental changes in RME and SARME: a 2-year follow-up. *The Angle Orthodontist*. 2009 Mar;79(2):207-13.
27. Lee KJ, Park YC, Park JY, Hwang WS. Miniscrew-assisted nonsurgical palatal expansion before orthognathic surgery for a patient with severe mandibular prognathism. *Am J Orthod Dentofacial Orthop*. 2010 Jun;137(6):830-9.

# CORONA VIRUS AND ROAD TOWARD FUTURE PROSPECTIVE: A REVIEW

## ABSTRACT

The outbreak of COVID-19 is a major area of concern globally. Within no time, despite global efforts to curb the spread of disease, the endemic has taken a huge toll on people. To control the outbreak of COVID there is an urgent need for vaccinations. This article, gives an update and information on the ongoing researches, regarding vaccines on COVID 19.

A detailed review was performed using both primary sources, such as scientific articles and secondary ones (bibliographic indexes, web pages, and databases).

PubMed and Google scholar were the principal search engines. The aim of the article is to provide a quick guidance with adequate safety to carry out all the dental procedures in this horrifying era of pandemic.

**Keywords:** COVID-19; prosthodontics and Covid-19; pandemic; precautions and prevention during COVID -19.

## Author:

<sup>1</sup>Dr. Ajay Mootha

<sup>2</sup>Dr. Madhushree Patil

<sup>3</sup>Dr. Surojit Dutta

<sup>4</sup>Dr. Nitin Jaggi

<sup>1</sup>Professor and Head  
Department of Prosthodontics  
Late Shri Yashwantrao  
Chavan Dental College  
Ahmednagar 414001, Maharashtra

<sup>2</sup>Post Graduate Student  
Department of Prosthodontics  
Late Shri Yashwantrao  
Chavan Dental College  
Ahmednagar 414001, Maharashtra

<sup>3</sup>Assistant Professor  
Department of Prosthodontics  
Late Shri Yashwantrao  
Chavan Dental College  
Ahmednagar 414001, Maharashtra

<sup>4</sup>Professor and Head  
Department of Oral and  
Maxillofacial Surgery  
Late Shri Yashwantrao  
Chavan Dental College  
Ahmednagar 414001, Maharashtra

## Address for correspondence

Dr. Madhushree Patil  
Post Graduate Student  
Department of Prosthodontics  
Late Shri Yashwantrao  
Chavan Dental College  
Ahmednagar 414001, Maharashtra  
Email: drajay\_mootha@rediffmail.com

J Ind Dent Assoc Kochi 2020;2(4):36-41.

## INTRODUCTION

In December 2019, a group of patients with symptoms of pneumonia, were identified in Wuhan, China. On investigations, it was found that,  $\beta$ -coronavirus was the causative organism. In January 2020, this coronavirus was named as the 2019-novel coronavirus (2019-nCoV) by World Health Organization (WHO). Again, on 11 February, Coronavirus Study Group (CSG) of the international committee proposed the new coronavirus as SARS-CoV-2. As of 1 March 2020, a total of 79,968 cases of COVID-19 have been confirmed in mainland China. Studies estimated the basic reproduction number ( $R_0$ ) of SARS-CoV-2 to be around 2.2, or even more (range from 1.4 to 6.5).<sup>1</sup>

## VIRAL ETIOLOGY

Researchers have predicted that SARS-CoV-2 and Middle East respiratory syndrome coronavirus, have their probable origin from horseshoe bat (*RHINOLOPHUS SINICUS*).<sup>2</sup> Initially, it was believed that snakes could be the possible host, however, after genomic findings, novel coronavirus was found dominant in bats. Thus it has been suggested that, only bats could be the possible host. Further analysis of homologous recombination revealed that, receptor binding spike glycoprotein of novel coronavirus is developed from a SARS-CoV-2 (CoVZXC21 or CoVZC45) and a yet unknown Beta-CoV.<sup>2,3</sup>

## STRUCTURE OF CORONAVIRUS

SARS-CoV-2 has a typical coronavirus structure with spike protein and it also expressed other polyproteins, nucleoproteins, and membrane proteins, such as RNA polymerase, 3-chymotrypsin-like protease, papain-like protease, helicase, glycoproteins, and accessory proteins. The spike protein of SARS-CoV-2 contains a 3-D structure in the RBD region to maintain the van der Waals forces.<sup>4,5</sup>

S- Spike protein (has a receptor binding domain [RBD] that binds to ACE2 receptor)

E- Envelope protein

M- Matrix protein

HE- Hem agglutinin- esterase (introduced to group 2 coronavirus genome by influenza C)

–Nucleocapside

## MODE OF TRANSMISSION

1. The corona virus interpersonal transmission occurs mainly via respiratory droplets and contact transmission.
2. The patients with symptomatic COVID-19 are the main source of transmission. Recent observations predicts that, asymptomatic patients in their incubation period are also a source of interpersonal transmission.

## CLINICAL MANIFESTATION

1. The most common symptoms associated with covid-19 are fever, myalgia or fatigue, cough and complicated dyspnea.
2. The less common symptoms are headache, anorexia, diarrhea, hemoptysis, runny nose and phlegm producing cough.
3. Increase in severity are primarily seen in middle-aged and elderly patients with pre-existing diseases like tumor, surgery, cirrhosis, hypertension, coronary heart disease, diabetes, and Parkinson's disease.<sup>6</sup>
4. The immunological reaction triggered by infection with SARS-CoV2 mobilizes numerous cytokines, mainly of pro inflammatory character. Changes in their levels are associated with the presence of the disease and a more severe prognosis.

## COVID 19 - A road towards future prospective

### VACCINE

It is a substance used to stimulate the production of antibodies and provide immunity against several diseases. It is prepared from the causative agent of a disease. Its products, or a synthetic substitute, is treated to act as an antigen without inducing the disease.

### TYPES OF VACCINE

1. Live attenuated vaccines:

This type of vaccine contains whole bacteria or

viruses which have been “weakened” so that they can create a protective immune response but do not cause disease in healthy people. The following are examples of live attenuated vaccines.

1. Rotavirus vaccine
2. MMR vaccine
3. Nasal flu vaccine
4. Shingles vaccine
5. Chickenpox vaccine
6. BCG vaccine against TB.

## 2. Inactivated vaccines:

It contains whole bacteria or viruses which have been killed, or small parts of bacteria or viruses, such as proteins or sugars, which cannot cause diseases.

1. Hepatitis A vaccine
2. Rabies vaccine
3. Japanese encephalitis vaccine

## COVID-19 AND VACCINE

There is an urgent need for vaccines to control the ongoing pandemic COVID-19 and previously-existing MERS/SARS caused by coronavirus (CoV) infections. The spike receptor-binding domain (RBD) of Covid 19 serves as an enticing target for the vaccine but is undermined by reduced immunogenicity.<sup>7</sup>

In general, the current CoV vaccine can be classified into two categories:

(i) Gene-based vaccines including recombinant vaccine vectors, DNA/messenger RNA vaccines, and live-virus vaccines, which produce antigens in host cells.<sup>7,8</sup>

(ii) Protein-based vaccines including protein subunit vaccine and inactivated whole virus whose antigens, are manufactured in vitro.<sup>7,8</sup>

As it is important to develop safe and effective vaccines to control the COVID-19 pandemic and it has been found that the SARS-CoV-2 virus have significant sequence homology with two other lethal coronaviruses, MERS and SARS, the vaccines identified in these patents viruses can facilitate the design of anti-SARS-CoV-2 vaccines.

1. **Attenuated Virus Vaccines:** After the incorporation of a mutation of Orf1a/b polyprotein (p59/nsp14/ExoN) into (Y6398H), it has shown the complete attenuation of virulence in mouse coronavirus.<sup>9</sup>

2. **DNA-Based Vaccines:** ZyCov-D' by Zydus Cadila

Using gene gun delivery of DNA-coated gold particles, the vaccination of mice against a calreticulin nucleocapsid fusion protein was held, which resulted in potent nucleocapsid-specific humoral and T cell-mediated immunity. Vaccinated animals' shows significant reduction of the titer of a challenging vaccine vector expressing the N protein of the SARS virus.

3. **Protein-Based Vaccines:** A vaccine capable of provoking a defensive immune response against SARS was reported by GlaxoSmithKline (GSK). An S protein immunogen and oil-in-water emulsion adjuvant are used in the vaccine. The engineered ectodomain immunogen (soluble S protein) induced high levels of anti-SARS-CoV IgG2a or IgG2b antibody and neutralized antibody responses in animal models in combination with the emulsion adjuvant GSK2.

In late February 2020, GSK announced a partnership to test a coronavirus (COVID-19) vaccine candidate with the Chinese firm Clover Biopharmaceuticals. The use of Clover's protein-based coronavirus vaccine candidate (COVID-19 S-Trimer) with GSK's adjuvant method will be part of this collaboration.

4. **Virus-like Particle Vaccines (VLPs):** Novavax showed an immunogenic composition consisting of MERS-CoV nanoparticle VLPs containing at least one trimer of S protein produced by over expression of baculovirus in Sf9 cells. This VLP preparation induced a neutralizing antibody response in mice and transgenic cattle, when administered along with their proprietary adjuvant Matrix M.

On February 26, 2020, Novavax announced that, animal testing of possible candidates for COVID-19 vaccines had started due to their prior experience dealing with other coronaviruses, including both MERS and SARS. Using their recombinant nanoparticle vaccine technology along with their propri-



etary adjuvant Matrix-M, their COVID-19 candidate vaccines targeting the S protein of SARS-CoV-2 have been created.

5. **mRNA -Based Vaccines:** Moderna announced on February 24, 2020 that it had released the first batch of mRNA-1273 for human use against SARS-CoV-2, prepared using the methods and strategies outlined in its previous patents. The mRNA-1273 vials were sent to the National Institute of Allergy and Infectious Diseases (NIAID), a division of the National Institutes of Health (NIH), to be used in the United States in the planned Phase 1 research. Moderna notes that mRNA-1273 is a prefusion st-target mRNA vacciner.<sup>9</sup>
6. **BCG vaccine and covid 19 mortality rate:**

Vaccination with BCG can result in improved immune surveillance for a lifetime. The BCG strains used, or the route of administration, can also have an effect on the innate immune response to vaccination. Provided the remarkable ability of transmission and the mortality rates of COVID-19, a vaccine capable of offering even transient protection (e.g., 6 mo to 12 mo) could be beneficial in high-risk people, such as health professionals, first responders and police officers, or those with pre-existing conditions. Similarly, also increased unspecific immunity via BCG vaccination in vulnerable age groups may improve severe COVID-19. Until new vaccines and/or effective therapies are available for serious acute respiratory syndrome

coronavirus<sup>2</sup> infections, temporarily induced trained immunity can buy time.<sup>10</sup>

### CORONA VIRUS VACCINE UPDATES

**INDIAN VACCINE UPDATE-** Human clinical trials for a Covid-19 vaccine have been launched in the country, according to ICMR, with approximately 1,000 volunteers participating in the exercise for each of the two indigenous created vaccine candidates.

Two vaccines have been approved by the Drugs Controller General of India (DCGI)- one developed by Bharat Biotech International Limited in collaboration with the Indian Medical Research Council and another by ZydusCadila Healthcare Ltd for the first and second phases of human clinical trials.<sup>12</sup>

### VACCINES INTREND

#### 1. 'Covishield' by University of Oxford-AstraZenec

This vaccine operates on a system that uses a weakened and non-replicating variant of a common cold virus that infects chimpanzees to carry a code that tells cells to create only the spiky outer layer of the SARS-CoV-2 virus (the spike protein), one of the most closely monitored candidates worldwide. The immune system of the body is supposed to identify this as a threat and produce antibodies to combat the spike protein so that if the actual virus wants to infect it, it will be ready.<sup>12,13</sup>

### CORONA VACCINE TRACKER.<sup>12</sup>

	IN THE LAB	PHASE 1	PHASE 2	PHASE 3	EMERGENCY AUTHORISATION	FINAL APPROVAL
OXFORD-ASTRA ZENECA	✓	✓	✓	✓		
MODERNA	✓	✓	✓	✓		
PIFZER-BIONTECH	✓	✓	✓	✓		
GAMALEYA (RUSSIA)	✓	✓	✓	✓	✓	✓
SINOVAC (CHINA)	✓	✓	✓	✓		
COVAXIN(INDIA)	✓	✓	✓			

In late phase III studies on more than 10,000 human participants across countries such as the UK, Brazil and South Africa, they have also entered phase II human trials in India.

## 2. ZyCoV-D' by Zydus Cadila

A genetically engineered DNA molecule coded with the SARS-CoV-2 virus DNA sequence, against which the immune response is expected to be created, is one of the indigenously generated frontrunners in the Covid-19 vaccine race. Early in August, Zydus Cadila announced that the candidate's phase I trials showed it was "safe and well tolerated," enabling it to pass to the second phase of human trials on August 6<sup>12</sup>

## 3. Covaxin by Bharat Biotech

This vaccine works by injecting SARS-CoV-2 virus that has been killed in the laboratory, a candidate who raked up controversy in early July following a letter from the Indian Council of Medical Research (ICMR) calling for an August 15 launch. In order to stimulate the body's immune response, the candidate tries to use this dead virus, which is not supposed to have the ability to kill or reproduce in those injected with it. It is currently predicted that the candidate will reach phase II human trials soon.<sup>12</sup>

## 4. RBD protein vaccine by Baylor College of Medicine - Biological E

According to the Baylor College of Medicine, this is a recombinant protein vaccine candidate developed using the same conventional methodology used to manufacture vaccines against Hepatitis B, making it simpler to manufacture since most companies already have the technological know-how for it. Biological E, which entered into an agreement with BCM last month, is scheduled to conduct clinical trials in India for this candidate vaccine.<sup>12</sup>

## CONCLUSION

As the number of cases are increasing and there is an outburst of the COVID 19 disease it has become the major global issue. Though number of precautionary measures is available there is still an urgent need for vaccine.

Considering the possible pandemic hazard, to learn this new virus and the pathophysiology of this new virus, scientists and doctors have been rushing to reveal potential treatment regimens. This article supports to update the knowledge on vaccines development and their progress.

## REFERENCES

1. Guo YR, Cao QD, Hong ZS, Tan YY, Chen SD, Jin HJ, Tan KS, Wang DY, Yan Y. The origin, transmission and clinical therapies on coronavirus disease 2019 (COVID-19) outbreak—an update on the status. *Military Medical Research*. 2020 Dec; 7(1):1-0.
2. Meng L, Hua F, Bian Z. Coronavirus disease 2019 (COVID-19): emerging and future challenges for dental and oral medicine. *Journal of Dental Research*. 2020 May; 99(5):481-7.
3. Li X, Song Y, Wong G, Cui J. Bat origin of a new human coronavirus: there and back again. *Science China Life Sciences*. 2020 Mar; 63(3):461-2.
4. Shereen MA, Khan S, Kazmi A, Bashir N, Siddique R. COVID-19 infection: Origin, transmission, and characteristics of human coronaviruses. *Journal of Advanced Research*. 2020 Mar 16.
5. Wu F, Zhao S, Yu B, Chen YM, Wang W, Song ZG, Hu Y, Tao ZW, Tian JH, Pei YY, Yuan ML. A new coronavirus associated with human respiratory disease in China. *Nature*. 2020 Mar; 579(7798):265-9.
6. Adhikari SP, Meng S, Wu YJ, Mao YP, Ye RX, Wang QZ, Sun C, Sylvia S, Rozelle S, Raat H, Zhou H. Epidemiology, causes, clinical manifestation and diagnosis, prevention and control of coronavirus disease (COVID-19) during the early outbreak period: a scoping review. *Infectious diseases of poverty*. 2020 Dec;9(1):1-2.
7. Dai L, Zheng T, Xu K, Han Y, Xu L, Huang E, An Y, Cheng Y, Li S, Liu M, Yang M. A Universal Design of Beta coronavirus Vaccines against COVID-19, MERS, and SARS. *Cell*. 2020 Aug 6; 182(3):722-33.
8. Graham BS. Rapid COVID-19 vaccine development. *Science*. 2020 May 29;

368(6494):945-946.

8. Hotez PJ, Corry DB, Bottazzi ME. COVID-19 vaccine design: the Janus face of immune enhancement. *Nature Reviews Immunology*. 2020 Jun; 20(6):347-8.
9. Liu C, Zhou Q, Li Y, Garner LV, Watkins SP, Carter LJ, Smoot J, Gregg AC, Daniels AD, Jervey S, Albaiu D. Research and development on therapeutic agents and vaccines for COVID-19 and related human coronavirus diseases.
10. Escobar LE, Molina-Cruz A, Barillas-Mury C. BCG vaccine protection from severe coronavirus disease 2019 (COVID-19). *Proceedings of the National Academy of Sciences*. 2020 Jul 28; 117(30):17720-6.
11. Ahmed SF, Quadeer AA, McKay MR. Preliminary identification of potential vaccine targets for the COVID-19 coronavirus (SARS-CoV-2) based on SARS-CoV immunological studies *Viruses*. 2020 Mar; 12(3):254.
12. Indian Covid-19 vaccine: At what stage are under-trial coronavirus vaccine candidates. (Indian express news).
13. Le TT, Andreadakis Z, Kumar A, Roman RG, Tollefsen S, Saville M, Mayhew S. The COVID-19 vaccine development.

# PROSTHODONTIC MANAGEMENT OF A XEROSTOMIC PATIENT WITH SALIVARY RESERVOIR DENTURE: A CASE REPORT

## ABSTRACT

Saliva plays a vital role in retention of complete denture. Reduced flow of saliva also called as xerostomia is the most common symptom of middle aged and old age group people. Xerostomia can cause serious difficulties to edentulous patients wearing complete denture as it not only affects retention but also makes the oral mucosa more prone to injury. This article gives a simple and cost-effective technique of maxillary salivary reservoir denture to treat the xerostomia and gives patient comfort of wearing a complete denture to improve the patient's quality of life.

**Keywords:** Xerostomia, salivary reservoir denture, complete denture.

## Author:

<sup>1</sup>Dr. Ajay Mootha

<sup>2</sup>Dr. Anjusha Pillewar

<sup>3</sup>Dr. Aniket Shinde

<sup>1</sup>Professor and Head  
Department of Prosthodontics  
Late Shri Yashwantrao Chavan Dental College  
Ahmednagar 414001, Maharashtra

<sup>2,3</sup>Post Graduate Student  
Department of Prosthodontics  
Late Shri Yashwantrao Chavan Dental College  
Ahmednagar 414001, Maharashtra

**Address for correspondence**  
Dr. Aniket Shinde  
Post Graduate Student  
Department of Prosthodontics  
Late Shri Yashwantrao Chavan Dental College  
Ahmednagar 414001, Maharashtra  
Email: [ajay\\_mootha@rediffmail.com](mailto:ajay_mootha@rediffmail.com)

J Ind Dent Assoc Kochi 2020;2(4):42-9.

## INTRODUCTION

"Saliva is a clear, tasteless, odourless slightly acidic viscous fluid, consisting of secretions from the parotid, sublingual, submandibular salivary glands and mucous glands of oral cavity". Saliva plays an important role in maintaining the integrity of oral tissues, it also aids in swallowing, speech and deglutition. In prosthodontic point of view saliva plays a vital role in retention of complete denture. The physical forces of retention in which saliva is involved are adhesion, cohesion, interfacial surface tension, capillarity and atmospheric pressure, which majorly aid in retention of complete denture.<sup>1,2</sup>

Dry mouth sensation is subjective and it is known as xerostomia. The victims of xerostomia are middle or old age group people and patients with systemic diseases. It is objectively demonstrated as reduced saliva flow than 0.1 to 0.2 ml non stimulated and 0.7 stimulated i.e., 500 ml saliva secretion per day. Xerostomia can make wearing complete dentures difficult for the edentulous patient as it not only affects retention but also makes the oral mucosa more prone to injury.<sup>3</sup>

Several treatment options are available to the clinician depending on the aetiology of xerostomia. Symptomatic treatment like changes in dietary pattern, patient counselling, lifestyle modifications, salivary stimulants, and use of salivary substitute are used in most of the xerostomia cases. A salivary reservoir denture is an effective solution in edentulous patients with xerostomia to deliver salivary substitute constantly into the patient's mouth without affecting the normal routine<sup>4, 5,6</sup>. This article demonstrates a simple and innovative technique of fabrication and designing of complete denture with functional salivary reservoir for the patients with xerostomia.

## CASE REPORT

A 78 years old patient reported to Department of Prosthodontics at Late Shri Yashwant Rao Chavan Memorial Medical & Rural Foundation's Dental College and Hospital, Ahmednagar with chief complaint of missing teeth, dry mouth, bad breath, difficulty in speech and chewing. Patient had not given any

relevant medical history. Intraoral examination revealed high, well rounded maxillary and mandibular ridges, thick ropy saliva and age-related changes in the mucosa led to dry mouth and halitosis. Considering the clinical scenario, a treatment plan was formulated to construct a salivary reservoir in maxillary complete denture containing salivary substitute as it has advantages over a reservoir in the mandibular denture which includes larger reservoir size, provides flow of saliva to the whole mouth unlike mandibular reservoir where flow is restricted to the floor of the mouth, and do not block the outlet holes by fluid and food in the floor of the mouth. This treatment plan was well accepted by the patient. (fig.1,2)

## PROCEDURE

1. Conventional procedural steps (case history, primary impression, final impression, jaw relation) were followed for fabrication

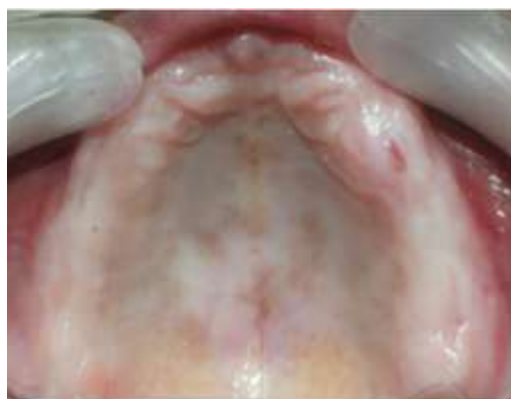

Fig 1. Maxillary arch

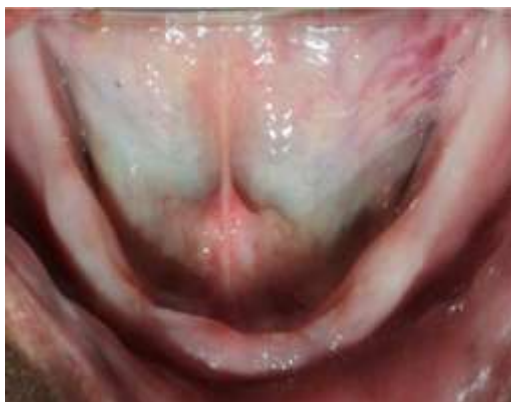

Fig 2. Mandibular arch

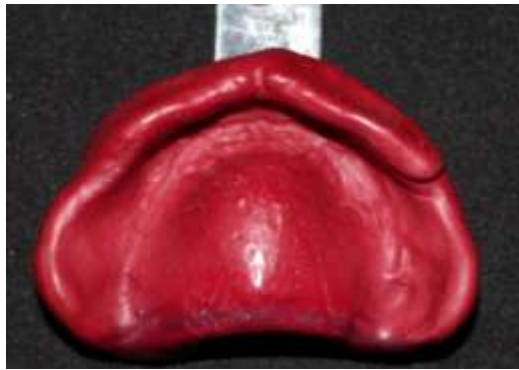

Fig 3. Maxillary primary impression

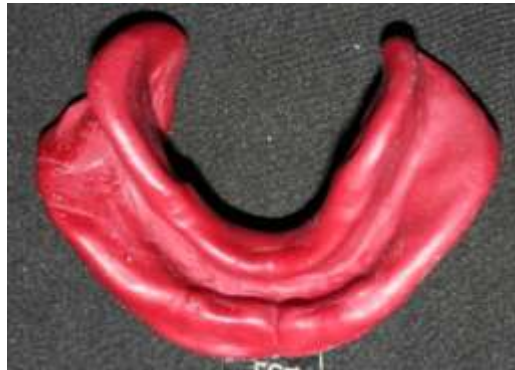

Fig 4. Mandibular primary impression

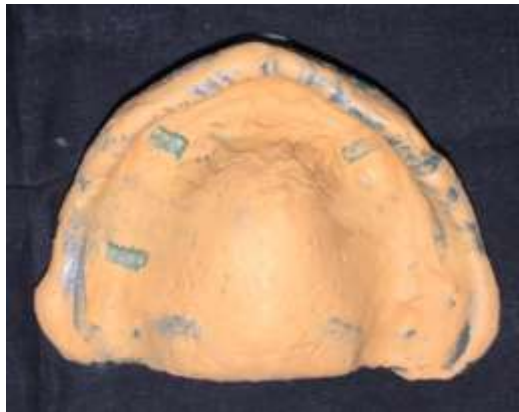

Fig 5. Maxillary final impression

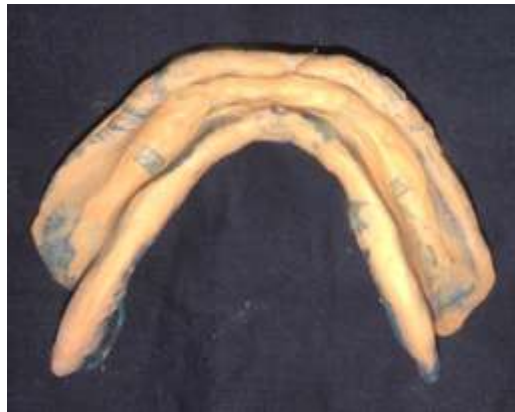

Fig 6. Mandibular final impression



Fig 7. Maxillary and mandibular jaw relation

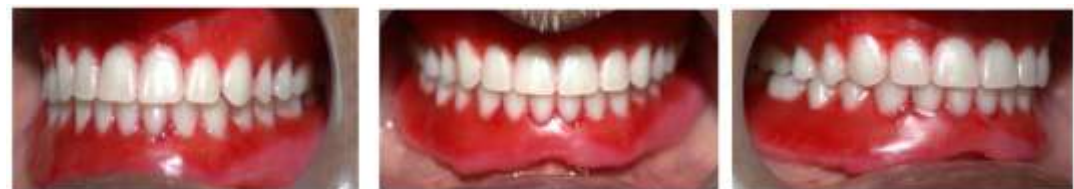

Fig 8. Try in

of complete denture up to the try in stage. (Fig.3-8).

2. Palatal contours were recorded using a tissue conditioning material at the try in stage by asking the patient to perform the swallowing action repeatedly to determine the appropriate position of the reservoir and

also to avoid any interference of tongue. (GC Soft Liner, GC Corporation, Japan) (Fig.9).

3. Fabrication of reservoir (Fig.10):
  - In order to fabricate the reservoir, a wax pattern was made with 3mm sprue wax which is circular in configuration and placed at the

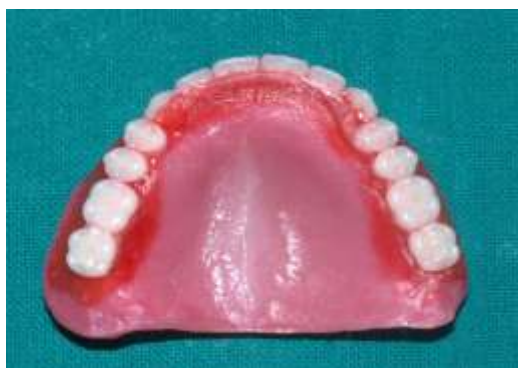

Fig 9. Palatal contour recording

anterior portion of contoured soft liner.

- With adequate confinement, it was placed in a such way that it could provide volume of 1.8 to 2 ml.
- Try in of the reservoir wax pattern was done to check the aesthetics and phonetics and then the position of reservoir was fixed.
- For the retention of the lid of the reservoir there is incorporation of grooves on the

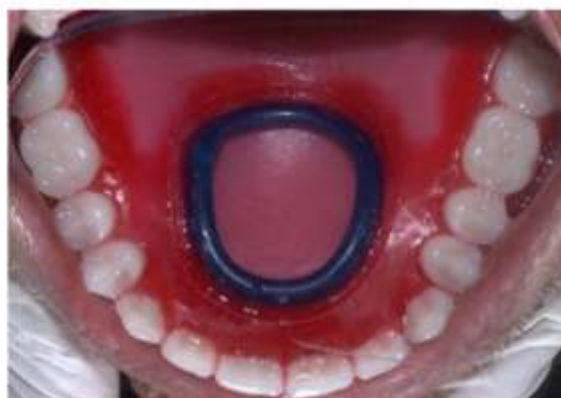
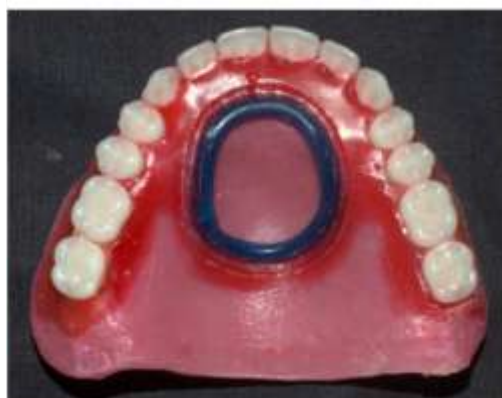
Fig 10. Reservoir fabrication with sprue wax

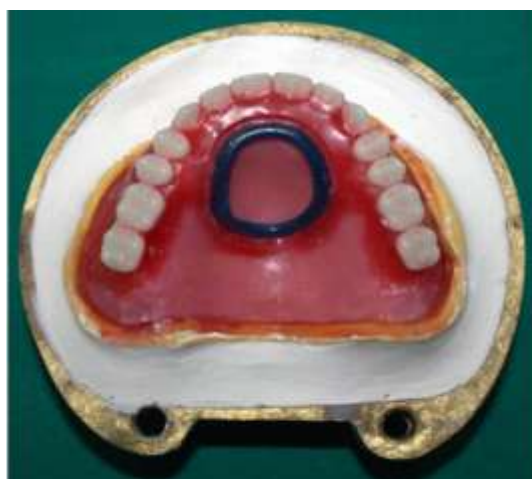

Fig 11. Processing of reservoir

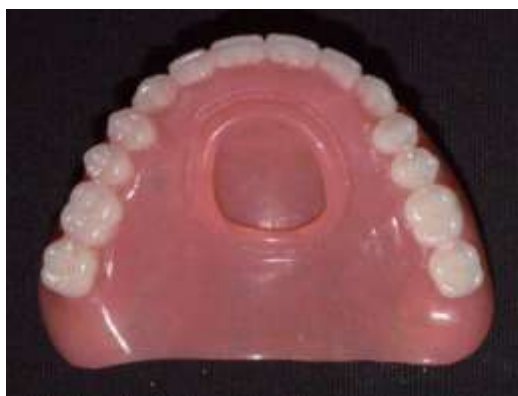

Fig 12. Final finished denture with reservoir

inner and outer surface of the wax pattern of the reservoir with discoid end of the carver.

4. Processing of upper and lower denture using compression moulding technique. (Fig.11).
  5. Lab remounting, finishing and polishing of dentures was done.(Fig. 12),
  6. Duplication of upper denture (Fig. 13-14):
- Impression of upper denture was done with

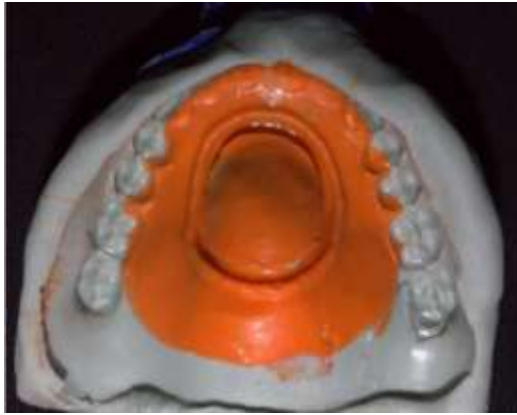

Fig 13. Putty impression of denture

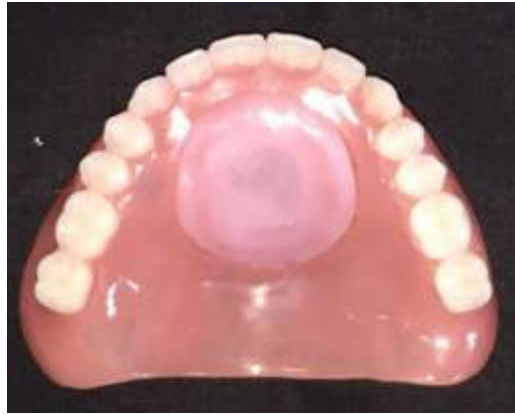

Fig 16. Fabricated lid



Fig 14. Duplicated cast of denture

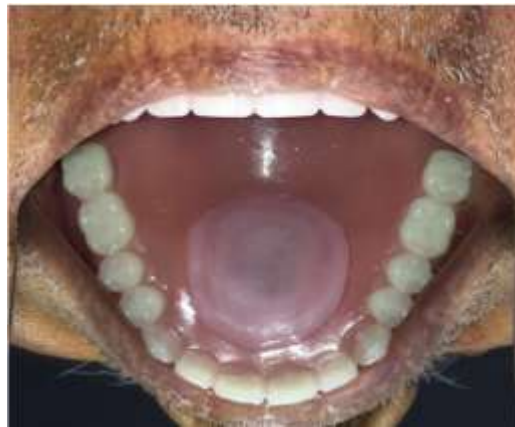

Fig 17. Intraoral view

C-silicone putty and light body. (zhermack-zetaplus condensation silicone).

- Then it is poured with diestone (kalrock die stone class IV dental stone) to obtain cast.
  - The cast was trimmed up to the reservoir for the fabrication of the lid.
7. Fabrication of flexible lid (Fig.15-17):
- The space was blocked for salivary substitute by means of modelling wax, leaving a

periphery of 1-2 mm.

- Material of choice for the fabrication of lid was gingifast due to its flexibility and comfortable to the patient. (zhermack gingifast).
- The material was injected in to the mould space and allowed to set.
- Silicone burs were used for finishing of lid.
- Thickness of the lid was kept 1.5 mm.
- Anendodontic file no. 20 was used to create



Fig 15. Lid fabrication with gingifast



a hole for the escape of salivary substitute in the oral cavity.

8. Denture insertion was done and checked for aesthetics, phonetics and functional efficacy of reservoir.(Fig.18,21,22),

**Patient instructions:**

- Patient was advised to take a bottle of salivary substitute (wet mouth) and a syringe to fill the reservoir (Fig.19).
- Patient was trained to fill the reservoir with syringe (Fig.20).
- Patient was asked to refill the reservoir every 2 to 3 hrs.
- Patient was trained to clean the reservoir and denture with soft brush and soap water.
- Patient instructed to use the denture for 8 hours a day.

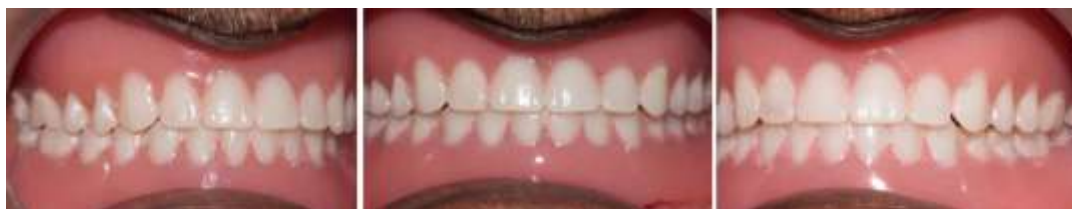

Fig 18. Denture insertion

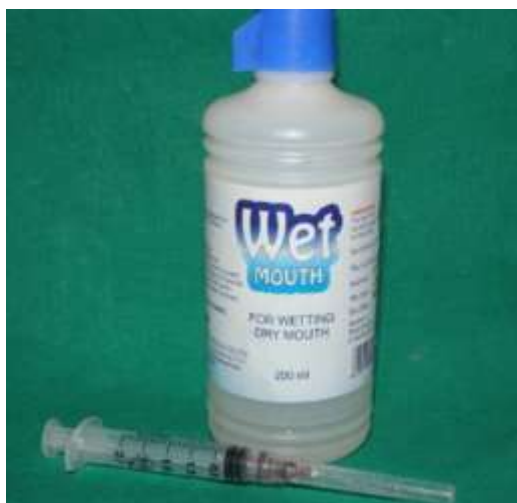

Fig 19 .artificial salivary substitute

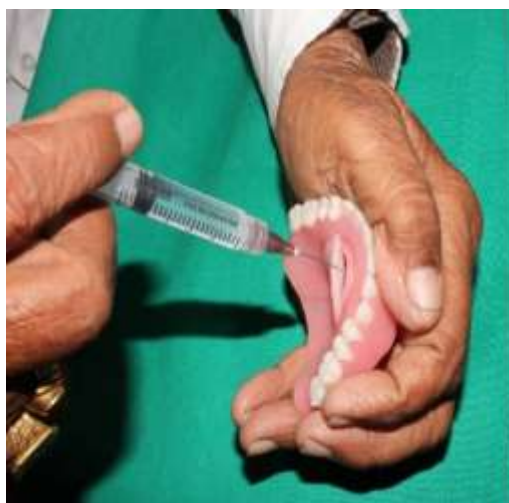

Fig 20. Refilling the reservoir

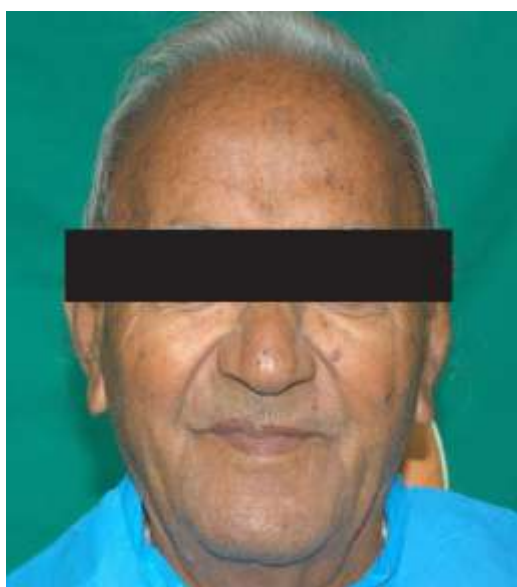

Fig 21. Pre-treatment photograph

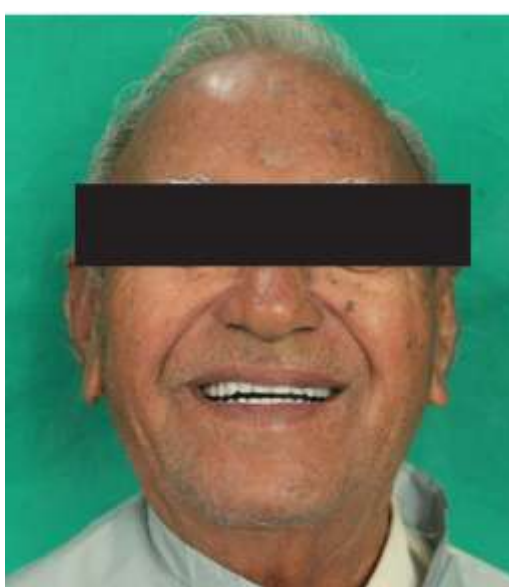

Fig 22. Post treatment photograph

## DISCUSSION

Many old age patients suffer from xerostomia. Xerostomia leads to unhealthy oral environment and painful oral condition. The dental practitioners must recognize the seriousness of these complications and continue efforts to alleviate them. Depending on the aetiology of xerostomia, various treatment options are available. However, a combination of methods is often employed to make prosthesis successful. The goal in management of xerostomia is to restore the salivary flow and to help the patient to use the denture and perform normal oral functions comfortably.<sup>4</sup>

Complete dentures patient's oral mucosa can get injured and also loss of retention due to diminished salivary flow because of the lack of saliva bonding between the interface of the prosthesis and the oral/gingival tissues.<sup>7</sup> The reservoir denture containing salivary substitute offers clinician an alternative method of treating patients suffering from xerostomia with a slow, sustained, and continuous release of salivary substitute.<sup>8</sup>

Several authors have recommended many approaches to fabricate reservoir dentures with available space in either the maxillary denture or the mandibular denture<sup>9</sup>. Mendoza and Tomlinson described split-denture technique for artificial saliva reservoir in the mandibular denture, which was split into upper and lower parts.<sup>10</sup> The time required to perform the laboratory steps were more. Burhanpurwala et al. described a method for fabricating mandibular reservoir denture, but still the laboratory steps were complicated.<sup>11</sup> Toljanic and Zucuskie described the use of salivary reservoir in the maxillary denture in patients with xerostomia. Its advantages over a reservoir in the mandibular denture includes larger reservoir size, provides flow of saliva to the whole mouth unlike mandibular reservoir where flow is restricted to the floor of the mouth, and do not block the outlet holes by fluid and food in the floor of the mouth.<sup>12</sup> However, due to incorporation reservoir in the maxillary denture can lead to increase in weight, which ultimately affect its retention and stability. Hirvikingas et al. used a Gerber attachment to operate the release mechanism for the salivary substitute in the maxillary reservoir complete denture. Disadvantage of this technique is that the pre-

cision attachment increased the cost of the treatment.<sup>13</sup>

The disadvantages of the techniques mentioned above are improved in our technique. The lid made with gingifast gives patient comfort than acrylic resin lid. Also the lid is flexible and aesthetically superior. Within the clinical limits the disadvantage of this technique is the fabrication of the lid requires precision and also the lid has to be remade every 6 months as the material gets loses its desirable properties which has been observed in recall of patient over a year that in turn increases the clinical visits and maintenance of the denture.

## CONCLUSION

This article describes a simple technique for the fabrication of reservoir maxillary denture for xerostomic patients. It helps to improve the oral health of the patient and also the denture wearing experience. Gingifast used here is comfortable and more aesthetic for patients. Further research should be directed towards the development of sensory driven salivary reservoir so that it will detect the dryness of mouth and supply the salivary substitute on constant interval.<sup>14</sup>

### Declaration Patient consent

The authors certify that they have obtained all appropriate patient consent forms. In the form, the patient has given his consent for his images and other clinical information to be reported in the journal.

## REFERENCES

1. Lakhyani R, Wagdargi SS. Saliva and its importance in complete denture prosthodontics. *Natl J Integr Res Med.* 2012;3:139-46.
2. Dr.B. Sivasaranya Physiology And Composition Of Saliva And Its Influence In Prosthodontics- A Review Volume 4 Issue 2 October 2016 ISSN: 2321 - 788X.
3. Singh OP, Mittal N, Saini R. How to manage xerostomia in prosthodontics. *Dental*

- Journal of Advance Studies. 2013  
Dec;1(03):144-51.
4. Joseph AM, Joseph S, Mathew N, Koshy AT. Functional salivary reservoir in maxillary complete denture—technique redefined. *Clinical case reports*. 2016 Dec;4(12):1082.
  5. Gurkar H, Venkatesh OY, Somashekar JM, Gowda MH, Dwivedi M, Ningthoujam I. Prosthodontic management of xerostomic patient: A technical modification. *Case Reports in Dentistry*. 2016 Feb 10;2016.
  6. Ladda R, Kasat VO, Gangadhar SA, et al. Reservoir complete denture in a patient with xerostomia secondary to radiotherapy for oral carcinoma: a case report and review of literature. *Ann Med Health Sci Res* 2014;4:271-5.
  7. Carl, W. 1974. Oral and dental care for the irradiated patient. *Quintessence Int. Rep.* 10:1102–1155.
  8. Daly, T. E. 1973. Dental care in the irradiated patient. Pp. 157–165 in G. H. Fletcher, ed. *Textbook of radiotherapy*. Lea &Febiger, Philadelphia.
  9. Bhushan P, Aras MA, Chitre V, Coutinho I, Nagarsekhar A, Mysore A. Salivary reservoir designs for patients with xerostomia: a review. *Journal of Research in Dentistry*. 2016 Oct 10;4(2):51-7.
  10. Mendoza, A. R., and M. J. Tomlinson. 2003. The split denture: a new technique for artificial saliva reservoirs in mandibular dentures. *Aust. Dent. J.* 48:190–194.
  11. Burhanpurwala, M. A., S. Magar, A. J. Bhandari, and S. A. Gangadhar. 2009. Management of an edentulous patient having xerostomia with artificial saliva reservoir denture. *J. Indian Prosthodont. Soc.* 9:92–95.
  12. Toljanic, J. A., and T. G. Zucuskie. 1984. Use of a palatal reservoir in denture patients with xerostomia. *J. Prosthet. Dent.* 52:540–544.
  13. Hirvikangas, M., J. Posti, and E. Makila. 1989. Treatment of xerostomia through use of denture containing reservoirs of saliva substitute. *Proc. Finn. Dent. Soc.* 85:47–50.
  14. Karthikeyan V, Chander NG, Anitha KV. A salivary sensor for the management of xerostomia in edentulous patients. *The Journal of prosthetic dentistry*. 2019 Mar 1;121(3):384-6.

*For the kind attention of readers...*

*It has come to our attention that the article titled 'NON-RESTORATIVE CAVITY CONTROL (NRCC) IN PEDIATRIC DENTISTRY: A REVIEW', published in Journal of Indian Dental Association, Kochi Branch, 2020, Volume 2, Issue 3, pages 4-11, contains images that were duplicates to previously published work. Permission to reproduce was not sought nor granted and no attribution was included for the use of these figures. For this reason, the publication in the Journal has been retracted by the Chief Editor of the journal.*



**JIDAK**

JOURNAL OF INDIAN DENTAL ASSOCIATION - KOCHI