

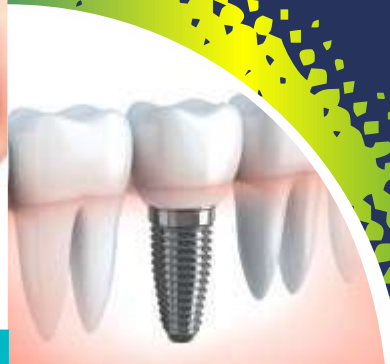

www.idakochi.org

JIDAK

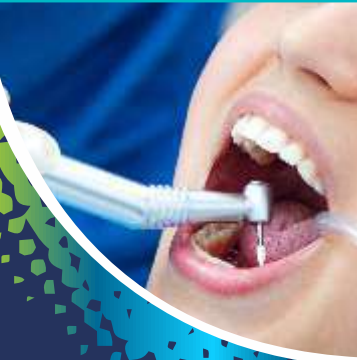July - Sept. 2019, Volume 1, Issue 3

JOURNAL OF INDIAN DENTAL ASSOCIATION - KOCHI



INDIAN DENTAL ASSOCIATION

KOCHI BRANCH





www.idakochi.org

JIDAK

July - Sept. 2019, Volume 1 , Issue 3

JOURNAL OF INDIAN DENTAL ASSOCIATION - KOCHI

Journal of Indian Association of Kochi Branch (JIDAK) is the official scientific publication of Indian Dental Association, Kochi Branch. It is a peer-reviewed journal published quarterly in e-format as well as print format.

The journal invites manuscripts from dental and other allied health sciences. It publishes manuscripts under categories of Original Research, Review and Case Reports.

{ For submission of manuscripts,
log on to www.jidakochi.org.
For communications,
mail to jidakochi@gmail.com. }

EDITORIAL BOARD

Co-editors:

Dr. Nivedita B.
Dr. Noorudeen A. M.
Dr. Prashant P. S.
Dr. Sunil M. Eraly
Dr. Pooja Latti
Dr. Vidya Parameshwaran
Dr. Esha Madhu
Dr. Sobitha G.
Dr. Radhakrishnan

Advisory Board

Dr. Anjana G.
Dr. V. I. Paul
Dr. Bindu Rachel Thomas
Dr. Siby T. Chennankara

Chief Editor

Dr. Meera Gopalakrishnan

Editor in Charge

Dr. Subramaniam R.

Chief Editors Message

Greetings from Team JIDAK

It is with immense pride and pleasure we are launching the third issue of JIDAK, the academic spearhead of IDA Kochi!!

The third issue launch of JIDAK which coincides with the auspicious 'Vijayadashami' and 'Vidyarambam' makes it even more special and we pray that it helps in sharing and spreading knowledge to all around us.

I would like to thank my entire team and the IDA KOCHI office for the continuous support in helping me take the JIDAK to greater heights of academic excellence!!

Seeking everyone's blessings and support.

Jai JIDAK

Jai IDA



Dr. Meera Gopalakrishnan
Chief Editor- JIDAK
IDA Kochi

CONTENTS

STRESS IN THE PERIODONTAL LIGAMENT DURING ORTHODONTIC RETRACTION OF POSTERIOR TOOTH: A FINITE ELEMENT ANALYSIS Dr. Arif Ismail, Dr. Asif Ismail, Dr. Hariprasad, Dr. Shaji A. P., Dr. Vaishak R.,, Dr. Sonu Thomson P.	02-05
ROOT RESORPTION AND ORTHODONTICS Dr. Swathi T., Dr. Gopi Krishnan S., Dr. Jithesh Kumar K.	06-14
WHAT'S NEW ABOUT IMPLANTS? LIGAPLANS? Dr. Madhavi T., Dr. Mathew John, Dr. Aswathy S., Dr. Ayswaria B.	15-20
INDIRECT LAMINATE VENEERS PREPARATION DESIGNS AND MATERIAL SELECTION Dr. Thushara Sudhakaran M.,,Dr. Prabath Singh V. P., Dr. Sapna C. M.	21-25
PHYTOMEDICINES - CURRENT APPLICATIONS IN ENDODONTICS Dr. Ashna Beegam K. S., Dr. Prabath Singh V. P., Dr. Asha Joseph	26-32
MANAGEMENT OF ROTARY FILE SEPARATION IN MANDIBULAR MOLAR - CASE REPORT Dr. Rohit Alapuzha Mihir, Dr. Prabath Singh V. P., Dr. Anisha E. A.	33-37
MUCOCELE ON THE VENTRAL SURFACE OF TONGUE: A RARE CASE REPORT Dr. Deepthi T. R., Dr. Sajeesh Raj A., Dr. Veena S. N., Dr. Adarsh V. J.	38-42

STRESS IN THE PERIODONTAL LIGAMENT DURING ORTHODONTIC RETRACTION OF POSTERIOR TOOTH: A FINITE ELEMENT ANALYSIS

ABSTRACT

The purpose of the study was to use the finite element method to investigate the stress related changes in periodontal ligament of the posterior segment under orthodontic force application. The three dimensional finite element models of the maxillary first molar, maxillary first premolar, bracket, arch wire and molar tube are constructed. The models of the tooth were made from CT scans of the upper dentition. Uneven distributions of the compressive and tensile stresses were seen in the PDL. This was due to the tendency of the teeth to rotate and tip instead of undergoing bodily movement.

Keywords: Orthodontic, Dentoalveolar, Archwire, FEM

Authors:

Dr. Arif Ismail¹
 Dr. Asif Ismail²
 Dr. Hariprasad³
 Dr. Shaji A P⁴
 Dr. Vaishak R⁵
 Dr. Sonu Thomson P⁶

Assistant Professor¹
 Department of Orthodontics and Dentofacial Orthopedics, Royal Dental College, Palakkad, Kerala

Reader²
 Department of Pedodontics and Preventive Dentistry, Annoor Dental College and Hospital Muvattupuzha, Kerala

Professor³
 Department of Orthodontics and Dentofacial Orthopedics, Royal Dental College, Palakkad, Kerala

Professor⁴
 Department of Orthodontics and Dentofacial Orthopedics, Royal Dental College, Palakkad, Kerala

Assistant Professor⁵
 Department of Orthodontics and Dentofacial Orthopedics, Royal Dental College, Palakkad, Kerala

Assistant Professor⁶
 Department of Orthodontics and Dentofacial Orthopedics, Royal Dental College, Palakkad, Kerala

Address for correspondence:

Dr. Arif Ismail
 Assistant Professor
 Department of Orthodontics and Dentofacial Orthopedics, Royal Dental College, Iron Hills, Chalissery, Palakkad, Kerala 679536
 E mail: dr.arif89@yahoo.in

J Ind Dent Assoc Kochi 2019;1(3)2-5.

INTRODUCTION

The study of orthodontic biomechanics requires the understanding of the nature of stresses and strain in the periodontium induced by orthodontic forces. Periodontal ligament tooth and alveolar bone are deformable entities under loads. Stress in the periodontal ligament is believed to be the initiating factor in tooth movement and a range of stresses are transmitted through alveolar bone through periodontal ligament.

Experimental techniques are limited in measuring the internal stress levels of the periodontal ligament. The major challenge comes from constructing complicated three dimensional shapes of tissues with different biomechanical properties. These characteristics of the periodontium make the finite element method (FEM) the most suitable means of analysis because of its ability to handle various shapes and material in homogeneity¹.

Finite element analysis (FEA) was introduced by R.Courant in 1943. It is a powerful computer stimulation tool in solving stress strain problems in the mechanics of solids and structures in engineering. FEM is an approximation method that divides the entire region of the structure into a set of elements the are connected by points called nodes. Element types are decided, and each element is assigned material properties to represent the physical properties of the model. The forces and boundary are defined to stimulate applied loads and constraint of the structure. The structural response is computed and presented for display.²

It is very important to keep in mind that the FEM will give results based upon the nature of the modeling systems and for that reason, the procedure for modeling is most important.

This study involves analyzing the stress related changes occurring in the periodontal ligament of the posterior segment during orthodontic force application. The direction of forces used in this study is mesial and distal. A model of 0.019 x 0.025 stainless steel arch wire was also made.

MATERIALS AND METHOD

A CT-Scan of the upper dentition and maxilla was taken of a patient in the axial direction at a distance of 1mm. The scanned images were converted into soft copy and were viewed with dental software and images were copied to modeling software.



Fig 1. FEM Model of Maxilla with brackets and archwire

Different volumes were created for all the teeth, bone, wire and PDL to study the movement of individual teeth in the alveolar bone sockets. The bracket considered for this study was of MBT, 0.022 x 0.025 inch slot with molar tubes. A complete scan 3D image replicating the exact shape and size of the brackets with tip and torque values incorporated.



Fig 2. FEM Model of Periodontal Ligament

The different structures such as alveolar bone, dentition, periodontal ligament and various wires used in the finite element model of human maxilla were assigned their respective material properties. The material data used in this study were taken from finite element studies conducted previously by Tanne K et al¹ (Table 1).

Next phase was to study the stress distribution in the periodontal ligament of the posterior

Material	Young's modulus(N/mm ²)	Poissons ratio
Tooth	20300	0.30
Periodontal Ligament	0.68000	0.49
Bone	140000	0.30
Stainless Steel	201000	0.31

Table 1. Material Properties

segment using FEA in response to Mesialising force and Distalising force.

RESULTS

The resulting stress patterns generated in the periodontal ligament were represented by different colours, from blue to red. Different colours represented different stress levels in the deformed state and expressed in Newton/mm². Positive values with red colour indicate maximum tensile stress and negative values with blue colour indicates maximum compressive stress.




Fig 3. Stress Patterns in PDL

DISCUSSION

In the present study FEM was used to analyse the stress related changes in the posterior segment, simultaneously for two teeth during application of various orthodontic forces. The two different forces, the stress related changes were represented as color-coded bands, from blue to red. Results of similar studies on maxillary first molar by Peter D. Jeon this small difference could be due to difference in the number of teeth. showed that when a distalising force of 300gm was applied a maximum compressive stress of -0.0079 and a maximum tensile stress of 0.00501 was obtained in the present study 300gm of distalising force there was a maximum of -0.077188 and a maximum tensile stress of 0.071371. During the application of mesialising and distalising forces of varying amount the PDL of the posterior segment showed an uneven distribution of compressive and tensile stresses. This suggests that the teeth were undergoing rotation and tipping instead of bodily movement.

FORCE	COMPRESSIVE STRESS (N/mm ²)	TENSILE STRESS (N/mm ²)
250 gm	- 0.045064	0.088155
300 gm	-0.054076	0.105784
350 gm	-0.06309	0.12347
400 gm	-0.072715	0.128749
450 gm	-0.08116	0.158679

Table 2
Compressive And Tensile Stress Values Seen On PDL At Different Mesial Forces

CONCLUSION

FEM has been widely used in engineering. The results of the study were obtained from a simulated model. When mesial and distal forces in the range of 250 gm to 450 gm were applied tipping and rotation movements were observed instead of bodily movement.

The limitation of our model are:

Approximation in the material behavior and shape of the tissues the PDL was modeled as a layer of uniform thickness and was treated as linear, elastic and isotropic, even though the PDL exhibits anisotropy and non linear viscoelastic behavior because of tissue fluid.

The shape of the teeth described in this study represents most common morphologic features of a maxillary first premolar and maxillary second premolar; there may be wide variations in morphologic conditions among normal individuals, which may affect the applicability of the analysis.

REFERENCES

1. Kazuo Tanne, Sakuda M, Burstone CJ, Three-dimensional finite element analysis for stress in the periodontal tissue by orthodontic forces. *Am. J. Orthod. Dentofac. Orthop*, 1987; 92:499-505.
2. McGuinness N, Wilson AN, Jones M, Middleton J, Robertson NR Stresses induced by edgewise appliances in the periodontal ligament - A finite element study. *The Angle Orthodontist* 1992 Vol.62 No.1
3. Pete G. Fotos, Constantine C. Spyarakos, and Dennis O. Bernard, Orthodontic forces generated by a simulated archwire appliance evaluated by the Finite Element Method. *The Angle Orthodontist* Vol.60 No.4.
4. M. L. Jones, J. Hickman, J. Middleton, J. Knox, C. A validated finite element method study of orthodontic tooth movement in the human subject. *Journal of Orthodontics/ Vol.28/ 2001/29-38.*

ROOT RESORPTION AND ORTHODONTICS

ABSTRACT

Orthodontic treatment and apical root resorption have been associated for many years. External root resorption is a feared complication during Orthodontic procedures. It can affect both the apex, but also the cervical zone of the roots subjected to Orthodontic forces for tooth movement and can compromise the future of the involved teeth. The detection of resorptions can occur during and/or after the active phase of Orthodontic treatment. The patient must be informed about the risks of resorption as a consequence of Orthodontic treatment. However, despite the rigorous efforts of knowledgeable individuals, the exact nature of the initiation and control of apical root resorption remains essentially unknown. Although apical root resorption may occur in individuals who have never experienced Orthodontic tooth movement, the incidence among treated individuals is quite high. These facts oblige the Orthodontist to seek a better understanding of the cause and prognosis of this phenomenon.

Key words: Orthodontic treatment, root resorption

Authors:

Dr. Swathi T¹

Dr. Gopi Krishnan S²

Dr. Jithesh Kumar K³

Post Graduate Student¹
Department of Orthodontics and
Dentofacial Orthopedics
Mahe Institute of Dental Sciences and
Hospital, Chalakkara, Mahe

Professor and Head²
Department of Orthodontics and
Dentofacial Orthopedics
Mahe Institute of Dental Sciences and
Hospital, Chalakkara, Mahe

Professor³
Department of Orthodontics and
Dentofacial Orthopedics
Mahe Institute of Dental Sciences and
Hospital, Chalakkara, Mahe

Address for correspondence:

Dr. Swathi T
Post Graduate Student
Department of Orthodontics and
Dentofacial Orthopedics
Mahe Institute of Dental Sciences and
Hospital, Chalakkara, Mahe
Contact: +91 8137092788
Email: swathiprabhakaran.sp@gmail.com

J Ind Dent Assoc Kochi 2019;1(3)6-14.

INTRODUCTION

Root resorption is the destructive process of the cementum and dentine layers of a tooth root due to clastic cell activity which leads to a subsequent loss of root structure of a tooth. This process may be physiological or pathological. Physiological root resorption of deciduous teeth naturally occurs when the permanent teeth begin to erupt. It may also occur to a small degree in the permanent dentition associated with physiological tooth movement. Pathological root resorption has been related to Orthodontic tooth movement, trauma and ectopic eruption of adjacent teeth and in association with other pathology¹. Bates was the first to describe root resorption of permanent teeth in 1856. The link between Orthodontics and root resorption was identified in 1914 by Ottolengui². Rudolph observed that resorption typically attacks the root tip and travels coronally which is termed as 'Shed roof effect'. Albert Ketcham suggested that apical resorption is a common and occasionally severe iatrogenic consequence of Orthodontic treatment³. The term "Orthodontically induced inflammatory root resorption (OIIRR)" was introduced by Brezniak and Wasserstein to describe the type of root resorption experienced during orthodontic treatment¹.

External apical root resorption (EARR) is an undesirable sequela of Orthodontic treatment that results in permanent loss of tooth structure from the root apex. This root resorption differs from other kinds of resorption. This is a sterile, local inflammatory process which is complicated and has all characteristic inflammatory symptoms and occurs when pressure on the cementum exceeds its reparative capacity and dentin is exposed, allowing multinucleated odontoclasts to degrade the root substance. Orthodontically induced root resorption begins adjacent to hyalinised zones and occurs during and after elimination of hyaline tissues³. Trauma, infectious inflammation of periapical tissues and periodontal diseases these are some of etiological factors that may induce root resorption or root shortening⁴. Root apex as well as lateral surfaces of the root can resorb however just apical root resorption can be shown by means of radiological examination. Usually Orthodontic treatment doesn't

cause clinically significant root resorption however microscopic changes appear on the teeth roots, which are difficult to detect in radiological images. Root resorption induces root shortening and weakening of teeth arch and this is very important for successful Orthodontic treatment⁴.

PREVALENCE

From the group of teeth examined, the majority of the published articles considers that teeth most prone to apical root resorption are the maxillary incisors especially the laterals, followed by the mandibular incisors and the maxillary premolars. Incidence on maxillary molars has also been observed.

TYPES OF ROOT RESORPTION

Root resorption can be classified into 3 categories: Surface resorption, Inflammatory resorption, and Replacement resorption. Surface resorption occurs constantly as microdefects on all roots and these normally repair themselves without notice. It is only consequential when lacunae in the cementum broaden and permit dentinoclasia. Surface resorption can occur anywhere on a root but is most common periapically. Surface resorption stops when the instigating agent (usually pressure) is removed and there is repair of the cementum. Inflammatory resorption occurs when root resorption progresses into the dentinal tubules to pulpal tissue that is infected or necrotic or into an infected leukocyte zone. Replacement resorption produces ankylosis of a tooth because bone replaces the resorbed tooth substance⁵. Root resorption occurring from Orthodontic treatment is either a surface resorption or transient inflammatory resorption. Replacement resorption is not normally seen after Orthodontic treatment.

Brezniak and Wasserstein suggested the term Orthodontically induced inflammatory root resorption (OIIR) to distinguish this type of resorption from others such as those caused by trauma, periapical lesions of periodontal disease. They then described three degrees of severity:

1. Cemental or surface resorption with remod-

eling - only the cemental layers are resorbed and then fully regenerated.

2. Dentinal resorption with repair - cemental and the outer layers of dentine are resorbed and usually repaired with cementum material. This process may alter the shape of the root from its original form.

3. Circumferential apical root resorption - full resorption of all hard tissues of the root apex occurs. This leads to irreversible root shortening. External surface repair and remodeling of sharp edges occurs in the cemental layer¹.

MEASUREMENT METHODS

A system of classification for the various types of resorption makes it possible to make a precise diagnosis regarding their degree of severity.

Levander and Malmgren presented a classification system for root resorption which is widely accepted in the orthodontic literature [1988]. According to this index, severity of root resorption increases from grade 1, defined as presence of irregular root contour, to grade 4, where root resorption is greater than 1/3 of the original root length^{7,8}.

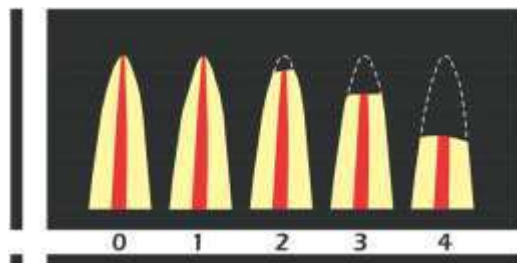


FIGURE: 1

Degree 1 – irregularity in the apical root contour, maintaining the original root length

Degree 2 – resorption of up to two millimeter of the root length

Degree 3 – resorption from 2 mm up to 1/3 of the root length

Degree 4 – severe root resorptions, above 1/3 of the root length.

For external cervical resorption, the Heither say

system of classification distinguishes four levels of cervical lesion.

Level 1- the resorption is a small invasive cervical lesion that presents a shallow dentinal erosion.

Level 2- the resorption lesion is very limited and penetrates the dentin close to the pulp chamber but does not extend as far as or only slightly onto the root dentin.

Level 3- the resorption lesion presents a deep penetration into the dentin up to the first third of the root.

Level 4- the resorption lesion is widely invasive and spreads apically beyond the first third of the coronal root.

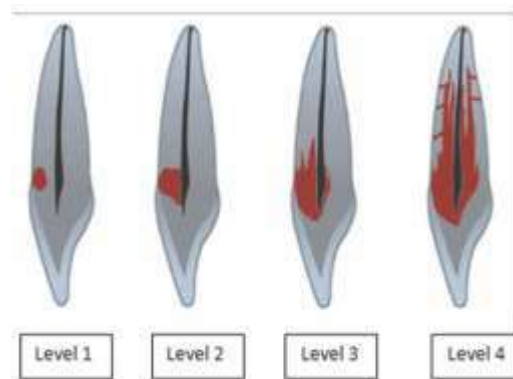


FIGURE: 2

ETIOLOGY

The etiology of apical root resorption is multifactorial. These factors consist of individual biologic characteristics, genetic predisposition and the effect of orthodontic forces. Risk factors for ARR can be categorized as patient-related and treatment-related. Patient-related factors include; genetics, systemic factors, asthma and allergies, chronic alcoholism, the severity of malocclusion, tooth-root morphology, a previous history of root resorption, alveolar bone density, root proximity to cortical bone, endodontic treatment and patient age and sex. Orthodontic treatment-related risk factors include; the treatment duration, magnitude of applied force, direction of tooth movement, amount of apical displacement, and method of force application⁶.

Genetic Factors

Predisposition to root resorption may be autosomal dominant, autosomal recessive, or hereditary determined by a few genes. Genetic factors account for at least 50% of the variation in root resorption⁴. From various studies it is clear that susceptibility does not depend on segregation of a simple Mendelian gene, either dominant or recessive. Instead, inheritance is multifactorial (polygenic), although no one has yet tested for a major gene effect. This means that about two thirds of the total variance in root resorption was accounted for by the siblings in each family sharing half of their genes in common by descent. It is then primarily biochemically based risk factors that modulate a given patient's resorption potential during treatment. This finding also absolves the Orthodontist of the bulk of responsibility for the extent of resorption. On the other hand, the clinician still bears responsibility for monitoring the teeth during the course of treatment⁵. The TNFRSF11A gene encodes the receptor activator of nuclear factor-kappa B (RANK), an essential signalling molecule in osteoclast formation and activation as a potential mechanism in pathogenesis of root resorption⁷.

Race

Sameshima et al reported that Asian patients were found to experience significantly less root resorption than white or Hispanic patients. In contrast, Smale et al recruited patients from 3 different centres in 3 countries and found no differences in resorption among the subsamples. They reported that this justified their decision to combine all patients into one group for analysis⁴.

Chronological age

The risk of root resorption increases with age because of a decrease in periodontal membrane vascularity and an increase bone density². On the other hand some authors stated that There is no significant relationship between the chronological age and root resorption⁹. Periodontal membrane becomes narrower and less vascularized, aplastic, alveolar bone becomes denser less

vascularized and cementum becomes wider with age. Through these changes adults show higher susceptibility to root resorption. When a patient is older than years, risk for root resorption increases⁴.

Dental age

Teeth with incomplete root formation undergo less root resorption than those with completely formed roots. It is stated that incompletely formed roots reach their normal root length. Some studies stated that if tooth root are not completely formed in the beginning of Orthodontic treatment, they are further developing during treatment, however remain shorter. Linge and Linge have established that Orthodontically treated teeth lose averagely 0, 5 mm of the root length⁴.

Sex

No significant relationship between sex and root resorption was found by performed studies.

Nutrition

Root resorption occurred in the animals lacking calcium and vitamin D in their foods.

Habits

Habits such as bruxism, nail biting, tongue thrust associated with open bite and increased tongue pressure are related to increased root resorption.

Anomalies of position and the number of teeth Hypodontia increases risk of root resorption. Impacted teeth may also induce occurrence of root resorption. Third molars are the most commonly Impacted teeth, which may cause Root resorption of the second molar through the cutting of the third molar, which lacks the place in the tooth arch. Maxillary Canines are the second most commonly impacted teeth. They can induce root resorption of the incisors and first premolars it is recommended annual palpation of the canine regions, Dental radiographs before 10 years of age and early extraction of deciduous canines.

Tooth structure

Root resorption most often occurs in the apical part of the root, because forces are concentrated at the root apex because Orthodontic tooth movement is never entirely translator and the fulcrum is usually occlusal to the apical part of the root, periodontal ligaments are situated in different directions in the apical part of the tooth root, the apical third of the root is covered with cellular cementum, whereas the coronary third is covered by noncellular cementum. Active cellular cementum depends on blood circulation, thus periapical cementum is more friable and easily injured in the case of trauma. Levander and Malmgren divide root forms to normal, short, blunt, dilacerated and pipette-shaped. Most authors have shown that roots with abnormal shape have a higher susceptibility to root resorption. According to the data of Sameshima and Sinclaire, normal and blunt tooth roots are resorbing the least. Pipette-shaped roots are the most susceptible root form to root resorption. Short roots have a greater risk for root resorption than average length roots. It was found that small roots resorb almost twice more than other root forms. There are controversial data about initial length of the tooth root and the amount of tooth root resorption. There is an opinion that longer roots are more likely to be resorbed than shorter ones because longer roots are displaced farther for equal torque. Tooth With longer roots need stronger forces to be moved and that the actual displacement of the root apex is greater during tipping or torquing movements. It was established that a normal root form of central incisors and wide roots are preventive factors of these teeth roots, decreasing risk of root resorption. Slightly increased root resorption is characteristic for the tooth with narrower roots⁴.

Mechanical factors

Orthodontic treatment and apical resorption have been associated for many years. Treatment-related factors that have been associated with apical root resorption include the magnitude of Orthodontic force, treatment mechanics, direction of tooth movement,

appliance type and treatment duration. These are considered as a mechanical factors associated with root resorption¹⁰. Mechanical risk factors which may possibly be preventable such as the magnitude of force used or the duration of force have been investigated¹.

Orthodontic appliances

Comparing root resorption resulting from removable and fixed appliances, it was established that root resorption more often is induced by treating it with fixed appliances. Studies of IlanaBrin showed that root resorption was diagnosed more rarely in children who have undergone 2-phase Orthodontic treatment than in children, who have undergone Orthodontic treatment with fixed Orthodontic appliances only. While assessing the influence of metal and aesthetic brackets on root resorption, it was diagnosed more often in patients treated with aesthetic brackets. This is because treatment with aesthetic brackets lasts longer. Application of an additional upper utility arch for intrusion of maxillary incisors induces root resorption of maxillary central incisors more often than by treating with straight arch. With Intermaxillary elastics greater root resorption is found on the side of tooth arch where elastics were used. Use of Class III Elastics increases root resorption of first mandibular molars distal root. Some researchers have established that use of intermaxillary Class II Elastics and type of Orthodontic arch does not have any influence on occurrence of root resorption.

Type of orthodontic tooth movement

All types of Orthodontic tooth movement induced some form of root resorption. Tipping, torque and bodily movement of teeth have been implicated as mechanical risk factors. Most Often root resorption was established after Orthodontic intrusion (anchoring of a tooth into an alveolar bone). According To Reitan, The force that distributes along the root during bodily movement is less than the one, which concentrates at the root apex resulting from tipping. Bodily Movement induces less risk for root resorption than tooth tipping.

Other Researchers state that tooth tipping induces less root resorption than bodily movement. Root Resorption occurs in cervical and apical part of the root during tipping movement. Middle Part of the root is resorbing during bodily tooth movement. This happens because of the shape of periodontal space, which is the thinnest in the middle part of the root. Comparing root resorption after application of the same magnitude continuous intrusion and extrusion forces it was established that teeth intrusion causes four times more root resorption than extrusion. Deep and extensive resorption areas, situated near the root apex foramen can be observed in the apical part of the intruded tooth root. Superficial and limited resorption cavities around the root apex foramen is characteristic for extruded teeth. Teeth rotation causes only minor injuries of periodontal tissues especially in single-root teeth. Resorption areas during the tooth rotation appear in the medial root third. Horizontal section of the root shows how prominent root zones might generate pressure areas when single-root tooth rotation is performing. The resorbed areas are consistently located at the boundaries between the buccal and distal surfaces as well as lingual and mesial root surfaces⁴. In some of the recent studies Expansion with RME has also been identified to cause root resorption¹.

Orthodontic force

Orthodontic force leads to micro trauma of periodontal ligaments and activation of inflammation related cells. According to some researches there was no root resorption difference detected while using low and high forces (50 G and 200 g). Some studies established that distribution of resorbed lacunae is directly related to the force magnitude, resorbed lacunae develops more quickly in case of higher forces. According to Schwartz, Forces increasing 20-26 g/cm, cause periodontal is chemia, Which may lead to root resorption. When Orthodontic force decreases to less than 20-26 g/cm tooth root resorption stops. Optimal force for Orthodontic tooth movement but not causing root resorption should be 7-26 g/cm on root

surface area. It was established that intermittent force causes root resorption more rarely than the continuous force because the intermittent force protects from formation of hyalinized areas or it allows reorganization of hyalinized periodontal ligaments and restoration of blood circulation at the time, when forces are not active. Continuous Force leaves no time to repair of damaged blood vessels and other periodontal tissues and this may lead to higher level of root resorption⁴.

Duration of orthodontic treatment

Duration of Orthodontic treatment is considered an important factor that may cause root resorption. Many studies show that severity of root resorption is related to duration of Orthodontic treatment. Results of other studies have shown that root resorption may begin in the early stage of Orthodontic treatment, it is especially characteristic to teeth with long, narrow and deviated roots. It was established that duration of treatment with fixed Orthodontic appliances was found to contribute to the degree of root resorption. Patients, whose Orthodontic treatment with fixed appliances lasts longer, experience significantly more grade 2 Root resorption. Average Treatment length for patients without root resorption is 1.5 years and for the patients with severe root resorption 2.3 years. Several contemporary studies have found no relation between the length of Orthodontic treatment and root resorption⁴. Since more en-masse anterior retraction is needed with miniscrew anchorage cases, treatment time increases which might increase the risk of OIIRR¹.

Influence of tooth extraction

Influence of tooth extraction on root resorption is valued controversially. Higher Root resorption rates were established in patients with several extracted teeth than in those, who haven't undergone tooth extraction. Root resorption develops more often after extraction of four first premolars if compared to the patients with non-extracted teeth or with extracted of just maxillary first premolars.

Self ligation

With the introduction of self ligating brackets, many claims have been made about the increased efficiency of tooth alignment compared to conventional brackets. This is most likely due to lower friction levels reported with the use of self ligating brackets. The use of elastics such as in the case of class II correction may be a risk factor for the teeth that support the elastics. It is due to the jiggling movements that occur on these anchor teeth¹.

MANAGEMENT

Patients must be informed of the risk of root resorption prior to starting Orthodontic treatment as a part of informed consent. In most cases, clinically significant shortening of a tooth root is rare. However, each patient must be made aware that, at present, we cannot predict which individuals will be susceptible to severe root resorption. Significant loss of tooth root structure can lead to an unfavourable crown to root ratio. Many clinicians fear that the potential consequence is an adverse effect on the long term prognosis of the affected tooth. Various methods are there to minimise OIRR. These include the use of light intermittent forces, reduction of treatment duration, habit control and prior assessment of family and medical history. Minimizing the use of inter maxillary elastics and high risk tooth movements such as intrusion and root torquing have also been recommended¹.

It is thought that active Orthodontic forces have an important role in the continuity of root resorption, therefore, the repair process begins after the release of the Orthodontic force or decrease in the magnitude of the force at a certain level. The repair is first observed around the resorption lacunae. This process shows similarity to the early cemento genesis during the development of the teeth. Resorption lacunae are recovered with the accumulation of new cementum and formation of a new periodontal ligament. Owmann-Moll et al. Stated that the possible repair level in resorption cavities that can be histologically observed can be summarized as follows:

I- Partial Repair: Part of the surface of the resorption cavity is covered with reparative cementum (cellular or acellular cementum).

II- Functional Repair: The total surface of the resorption cavity is covered with reparative cementum without the re-establishment of the original root contour (cellular cementum).

III- Anatomic Repair: The total surface of the resorption cavity is covered with reparative cementum to an extent such that the original root contour is re-established.

Studies found that resorption continued for 4 weeks after the stop of the Orthodontic force. After four-week light force application which was followed by 4-week retention, there was continuous and regular repair, while most of the repair occurred where the heavy force was applied in 4 weeks, which was followed by the 4-week retention⁹.

CONCLUSION

External apical root resorption (EARR) can be a significant sequel of Orthodontic treatment and in the most severe cases may threaten the longevity of the teeth. Identification of the factors contributing to EARR during Orthodontic treatment is therefore essential in order to minimize the incidence and severity of root resorption. The key point to take from this review is that, whilst Orthodontic treatment is associated with an increased incidence and severity of EARR, it is not currently possible to determine which patients are at particular risk. Until better evidence becomes available, all prospective Orthodontic patients should be warned of the possibility of root resorption as part of the consent process. Additionally, pretreatment radiographs should be taken for all patients, to act as a baseline against which any future resorption can be measured.

REFERENCES

1. Dr. Aakash Shah. Orthodontically Induced Root Resorption A Review. International Journal of Advance Research and Development;2017.
2. Scott McNab et al .External Apical Root Resorption Following Orthodontic Treatment. Angle Orthod 2000;70:227–232.
3. Sodawala J and Reddy. Rootresorptioninorthodontics:Areviewofliterature Indian Journal of dental research and review, Oct 2009.
4. Kristina Lopatiene, AisteDumbravaite. Risk factors of root resorption after orthodontic treatment.Stomatologija, Baltic Dental and Maxillofacial Journal, 2008, Vol. 10(3).
5. Edward F. Harris. Root Resorption during Orthodontic Therapy. SeminOrthod 2000; 6:183-194.
6. AhuTopkara, Ali I Karaman and Chung H Kau. Apical root resorption caused by orthodontic forces: A brief review and a long-term observation. Eur J Dent 2012;6:445-453.
7. Topkara A. External apical root resorption caused by orthodontic treatment: a review of the literature. European journal of paediatric dentistry, vol. 12/3-2011.
8. Pastro et al. Factors Associated to Apical Root Resorption after Orthodontic Treatment. The Open Dentistry Journal, 2018, Volume 12.
9. FurkanDindaroglu and ServetDogan.Root Resorption in Orthodontics. TurkJOrthod.2016.16021.
10. Vicki Vlaskalic, Robert L. Boyd, and Sheldon BaumrindEtiology and Sequelae of Root Resorption. SeminOrthod 1998;4:124-131.
11. Dominique lunardi, Thibaultbecavin, Alain gambiez and Etienne deveaux. Orthodontically induced inflammatory root resorption: apical and cervical complications. J Dentofacial AnomOrthod 2013; 16:102.
12. Vinod Krishna. Critical issues concerning root resorption; a contemporary review. World journal of orthod 2005; 6:30- 40.
13. Acar A., Canyurek U., Kocaaga M. Erverdi N. Continuous vs. discontinuous force application and root resorption. Angle Orthod 1999; 69:159-163.
14. Alexander S. Levels of root resorption associated with continuous arch and sectional arch mechanics. Am J OrthodDentofacialOrop 1996;110: 321-324.
15. Andreasen J.O. Review of root resorption systems and models.Etiology ofroot resorption and the haemostatic mechanisms of the periodontal ligament.
16. In: Davidovitch, Z. (ed.), Biological mechanisms of tooth eruption and rootresorption. Columbus, OH: Ohio State University; 1988: 9-22.
17. Apajalahti S, Peltola JS. Apical root resorption after orthodontic treatment – aretrospective study Eur J Orthod. 2007 Aug;29(4): 408-412.
18. Arai Y, Tammissalo E, Iwai K, Hashimoto K, Shinoda K. Development of a compact computed tomographic apparatus for dental use. DentomaxillofacRadiol 1999;28:245-248.
19. Armstrong D, Kharbanda OP, Petocz P, Darendeliler MA. Root resorption after orthodontic treatment. AustOrthod J. 2006 Nov;22(2):153-160.
20. Artun J, Smale I, Behbehani F, Doppel D, Van't Hof M, Kuijpers-Jagtman AM. Apical root resorption six and 12 months after initiation of fixed orthodontic appliance therapy. Angle Orthod 2005;75:919-926.
21. Artun J, Van't Hullenaar R, Doppel D, Kuijpers-Jagtman AM. Identification of orthodontic patients at risk of severe apical root resorption. Am J OrthodDentofacialOrthop. 2009 Apr;135(4):448-455.
22. Beck B., Harris E. Apical root resorption in orthodontically treated subjects: Analysis oedgewise and light wire mechanics. Am J OrthodDentofacialOrtop1994 105:350-361.
23. Becks H. Orthodontic prognosis: evaluation of routine dentomedical

examination to determine good and poor risks. *Am J OrthodDentofacialOrtop*1939 25:610-624.

24. Becks H., Marshall JA. Resorption or absorption? *J Am Dent Assoc* 1932;15281537 Bishara S., Vonwald L., Jakobsen R. Changes in root length from early to mid adulthood: Resorption or apposition? *Am J OrthodDentofacialOrtop*1999;115:563-568.
25. Blake M., Woodside D., Pharoah M. A radiographic comparison of apical root Resorption after orthodontic treatment with the edgewise and speed appliances. *Am J OrthodDentofacialOrtop* 1995;108:76-84.
26. Bondemark L, Lilja-Karlander E. A systematic review of Swedish research in orthodontics during the past decade. *Acta Odontologica Scand.* 2005;62:46-50.
27. Brezniak N, Goren S, Zoizner R, Dinbar A, Arad A, Wasserstein A et al. A comparison of three methods to accurately measure root length. *Angle Orthod*2004;74:786-791.
28. Brezniak N, Goren S, Zoizner R, Dinbar A, Arad A, Wasserstein A et al. The use of an individual jig in measuring tooth length changes. *Angle Orthod*2004;74:780-785.
29. Brezniak N, Goren S, Zoizner R, Dinbar A, Wasserstein A, Heller M. The accuracy of the cemento-enamel junction identification on periapical films. *Angle Orthod* 2004a;74:496-500.
30. Brezniak N, Wasserstein A. orthodontically induced inflammatory root resorption . Part 2: the clinical aspects. *Angle Orthod* 2002b;72:180-184.
31. Brezniak N, Wasserstein A. Root resorption after orthodontic treatment: Part 2. Literature review. *Am J OrthodDentofacialOrthop* 1993;103:138-146.

WHAT'S NEW ABOUT IMPLANTS? LIGAPLANTS?

Authors:

Dr. Madhavi T.¹
 Dr. Mathew John²
 Dr. Aswathy S.³
 Dr. Ayswaria B.⁴

Address for correspondence:

Post Graduate Student
 Department of Periodontics
 Sri Sankara Dental College
 Akathumuri, Varkala, Kerala

Professor
 Department of Periodontics
 Sri Sankara Dental College
 Akathumuri, Varkala, Kerala

Senior Lecturer
 Department of Periodontics
 Sri Sankara Dental College
 Akathumuri, Varkala, Kerala

Post Graduate Student
 Department of Periodontics
 Sri Sankara Dental College
 Akathumuri, Varkala, Kerala

Address for correspondence:

Dr. Madhavi T.
 Post Graduate Student
 Department of Periodontics
 Sri Sankara Dental College
 Akathumuri, Varkala, Kerala
 Contact: +91 9846601993
 Email: madhavi.thara@gmail.com

ABSTRACT

A tissue-engineered periodontal ligament (PDL) around implants would represent an important new therapeutic tool to replace lost teeth. The PDL is the key to tooth anchoring; it connects tooth root and alveolar bone, and it sustains bone formation. The implant with periodontal ligament called as 'ligaplant' is the new emerging era in the field of dentistry where tissue engineered periodontal ligament cells on the implant surface are formed thus mimicking the natural tooth. Such advancement would revolutionize implant dentistry and would be significantly beneficial to patients.

Key words: Ligapplants, Dental implants

INTRODUCTION

Dental implants have become ideal replacements for missing teeth. However, despite good success rates of osseointegrated oral implants, failures do occur, which can be attributed to the bone loss due to excessive occlusal load or infection. Hence, the focus of implant dentistry has changed from merely obtaining osseointegration to the preservation and prevention of peri-implant hard and soft tissue loss. The field of oral and periodontal regenerative medicine has recently undergone significant advancements, the presence of a periodontal ligament allow for a more dynamic role beyond the functionally ankylosed implant. Therefore, the innovative approach is the creation of “periodontio-integrated implants” i.e., an implant suspended in the socket through periodontal ligament as opposed to functionally ankylosedosseointegrated implants. Hence these implants called as ‘ligaplants’ is the new emerging era in the field of dentistry where tissue engineered periodontal ligament cells on the implant surface are formed thus mimicking the natural tooth.

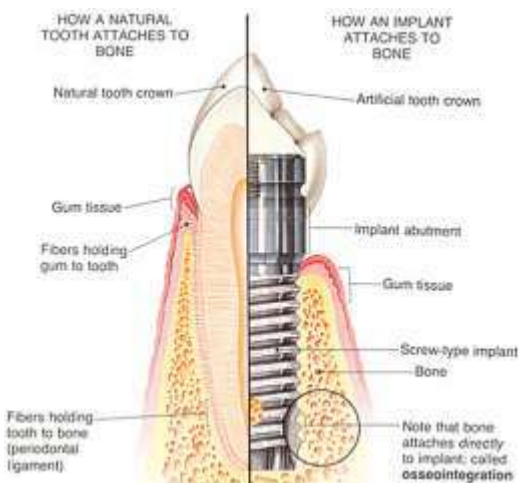


Fig 1. Interphase of Implant and bone⁵

The presence of periodontal ligament fibres around the tooth have significant role in the transmission of the masticatory forces to the surrounding bone. In case of dental implants,

due to the absence of periodontal ligament fibres, the forces are not dissipated equally and effectively as in case of natural teeth. Hence the tissue engineering process can create an environment around the implant similar to that of the natural teeth. Apart from its role in tooth anchoring, the periodontal ligament (PDL) provides progenitor cells for alveolar bone formation and remodelling; at the bone side facing the tooth root, the PDL plays the role of the periosteum. Periodontal disease with tissue destruction by inflammation often leads to resorption and loss of alveolar bone, which may be followed by tooth loss. In contrast, a functional PDL induces bone, even at ectopic sites.⁸

A possible approach to the replacement of lost teeth is tissue engineering of the PDL. In support of the feasibility of this concept, the PDL has been shown to possess a capacity for spontaneous regeneration, during which the biomechanical tissue strength is restored, and innervations is re-established. After clinical tooth transplantations, a new functional PDL can be regenerated, apparently from PDL tissue accompanying the transplanted tooth. Even after transplantation at sites with deficient bone, restoration of alveolar bone has been observed, along with the recovery of functional tooth anchoring.⁸

Currently, to replace lost teeth without considering the PDL, implants of inert biomaterial are directly inserted into jawbones. In these procedures, local bone defects and generally poor bone quality necessitate bone reconstruction before implantation, and localized bone loss around the implant fixture represents a clinical challenge. A further, commonly observed problem is gingival recession, possibly due to modified tissue architecture, which requires further surgical interventions.⁸

An implant system that would include a PDL with tissue-inducing properties might alleviate these problems. Technically, implants carrying a PDL may be installed in the extraction socket of the missing tooth, thereby facilitating the surgical procedure. Natural implant anchoring

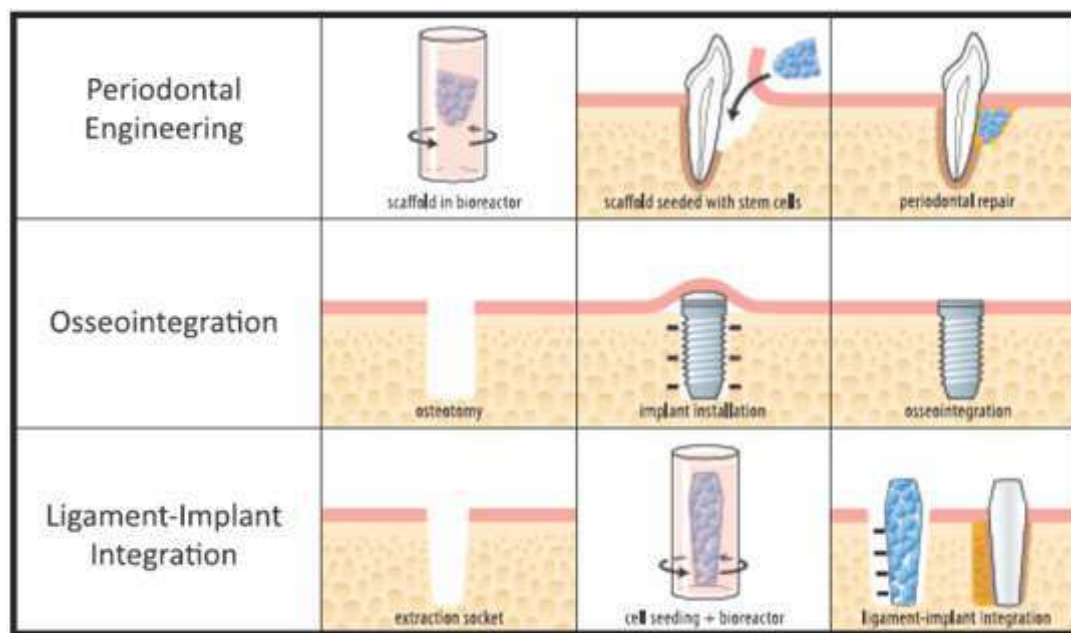


Fig 2. Interphase of Implant and ligaplant⁵

might also be compatible with further growth and development of the alveolar bone housing, and it may allow tooth movements during orthodontic therapy.⁸ Such implants are called 'ligaplants'. Ligaplants have the capacity to induce the formation of new bone, when placed insites associated with large periodontal bone defects.⁸

In the field of dental implants, tissue engineering is an innovative technique. This was proposed by Langer and colleagues in 1993 for the regeneration and restoration of the lost tissue. In 1982, Nyman et al., demonstrated that PDL cells could be used to re-establish connective tissue attachment to teeth.⁶ Tissue-specific characteristics were acquired after implantation, which includes a new cementum-like layer, typical for regenerated PDL, orientation of cells and fibres across the non-mineralized peri-implant space. PDL organization thus induced the cooperation of the tissues surrounding the liga plant site.

The fibroblasts of the periodontal ligament have the ability to proliferate and differentiate into the cementoblasts, thereby forming cementum. The alveolus surrounding ligaplants also suggests the osteogenic potential of the periodontal ligament fibres. Regeneration of the PDL likely emanates from PDL progenitor cells, which can assemble new

PDL-like structures in vivo. Regeneration proceeds with anew layer of cementum, attached to the original cementum of the tooth root, into which new transverse fibres are integrated. Importantly, if a new cementum layer were to be laid down on the surface of an engineered device, this would accommodate the integration of a properly attached PDL with the potential to stimulate the regeneration of adjacent alveolar bone.⁸ Tissue engineering helps in periodontal ligament formation, thus covering the implant surface, thereby giving rise to a new concept of oral implantology.¹¹

LIGAPLANTS

The ligaplant system mimics the natural tooth roots in alveolar bone. Without interlocking and without direct bone contacts, they become firmly integrated into the bone despite the initial fitting being loose in order to spare the PDL cell cushion. Thus, the surgical procedure for ligaplants seems to be easy. It also induces the formation of new bone even when placed in sites associated with large periodontal defects, precluding the need for bone grafting as well as eliminating other problems such as gingival recession and bone defects of the missing tooth site. Therefore, these implants could be placed where periodontal bony defects are present.⁵

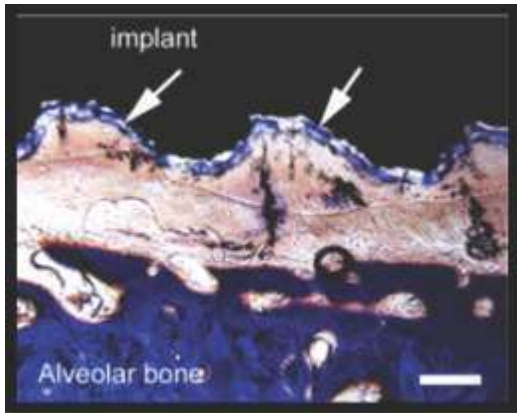


Fig 3a, Ligaplant Fig 3b, Ligaplant

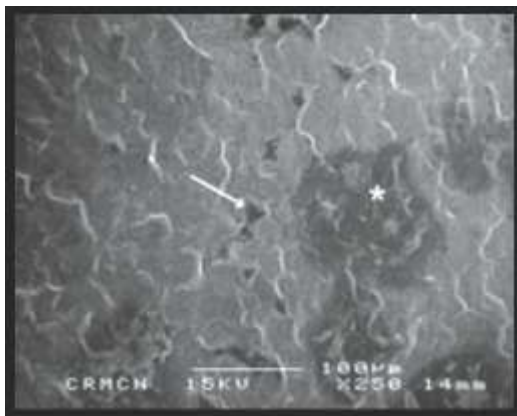


Fig 3a. Ligaplants, Masson's trichrome staining; a new layer of dense collagen covered the ligaplant (arrows), and a PDL-like tissue had been formed with perpendicular fibres between implant and alveolar bone.

Fig 3b. Ligaplants, Scanning electron microscopy of ligaplant, Overview, showing the structured ligaplant surface covered with apatite deposits (lighter) and apatite-deficient regions (darker,*), as well as minor gaps in the apatite layer (arrows).

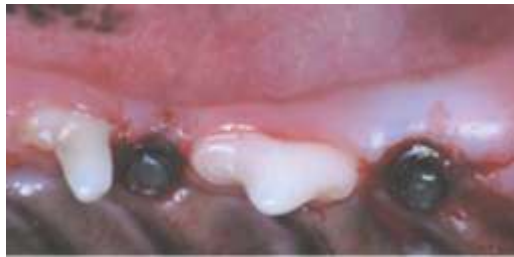


Fig 4a. Ligaplants8
Fig 4b. Periodontal tissue formation around titanium implant in dog.13

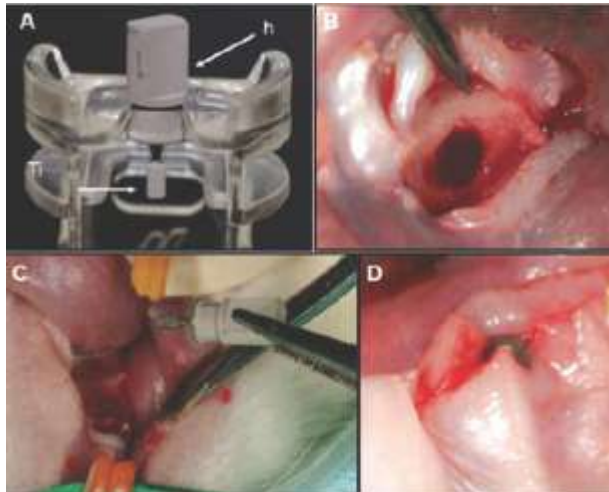


Fig 5. Rat maxillary molar titanium implant model.3
Fig 6. Ligaplant, radiography.8

Fig 5. (A) Straumann designed specialized titanium implant (Ti) and handle (h), arrows. (B) Animal preparation for implant placement. (C) Placement of cellseeded Ti implant. (D) View of implant after placement.

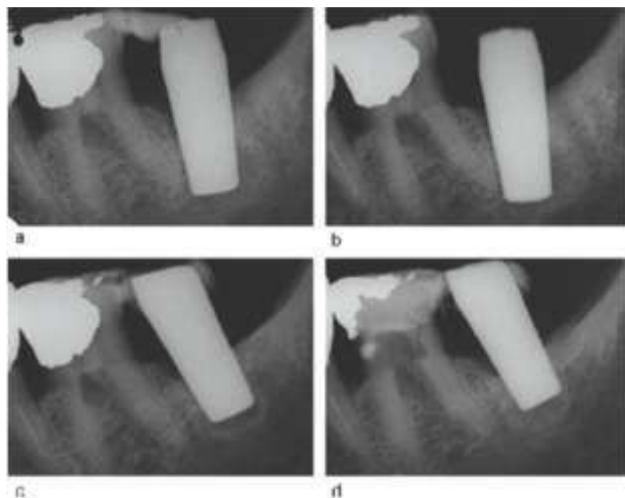


Fig 6. (a) After 2 weeks, (b) after 8 weeks
(c) after 2 years and (d) after 4 years.

Preparation of Ligaplant

Polystyrene culture dishes containing N-isopropyl acylamide monomer and 2 propanolol solution are exposed to Area Beam Electron Processing System (ABEPS). Then the ungrafted monomer is removed by rinsing culture plates with cold water. Periodontal ligament cells were scraped off using a scalpel from the middle third of an extracted tooth. These cells were inoculated in culture dishes containing Dulbecco's Modified Eagle's Minimal Essential Medium supplemented with 100 units/ml of penicillin, streptomycin and 10% fetal bovine. These cells are cultured in an environment of 5% CO₂ at 37°C for 48 hours so that the cells get attached to the dishes. The debris are washed off and the medium is changed three times a week. Harvesting of the periodontal ligament cells sheet is done on temperature responsive culture dishes at 37°C and a cell density of 1x10⁵. A hydroxyapatite coated titanium pin is placed in a hollow plastic cylinder having a 3 mm space around the pin. Plastic vessels are seeded with periodontal ligament cell suspension for 18 days under a flow of growth medium.⁹

ADVANTAGES OF LIGAPLANTS

1. It alleviates problems like gingival recession and bone defects of missing tooth.
2. Mimics natural tooth roots in alveolar process.
3. Ligaplants become firmly integrated without interlocking and without direct bone contact, despite the initial fitting being loose in order to spare PDL cell cushion.
4. Bone formation was induced and movements of ligaplants inside the bone suggests an intact communication between bone and implant surface.¹⁰

DISADVANTAGES OF LIGAPLANTS

1. The culturing of ligaplants should be done with caution, i.e. the temperature, the cells that are used for culturing, the duration of the

culturing and others. If some difficulty evokes during the culturing, the ligaplants may fail as other non-periodontal cells may develop.

2. With limited facilities and members to perform this research, the cost of this type of implant is high.
3. The factors affecting the host to accept the implant or the growth of PDL in the socket is unpredictable, which may result in failure of implant.¹⁰

CONCLUSION

Ligaplants as tooth replacement seems to be the next advancement and it is more likely to enhance the long-term stability of the implants. Tissue engineering of the PDL around implants has been a proof-of-concept, the two important inter tissue interactions: firstly, the formation of a functional PDL is dependent on the implantation site, and secondly, ligaplant can induce the formation of bone in the vicinity.

Ligaplants as tooth replacements have decisive advantages as compared with osseointegrated devices, due to their potential for periodontal tissue regeneration. It is proposed that therapeutic success requires the ability of a high proportion of the cultivated cells to organize into a new PDL. The ligaplant surgery is relatively easy, because the implant is not tightly fitted into its site. Future clinical use of ligaplants might avoid bone grafting with its expense, inconvenience, and discomfort for the patient. Further research on humans with long-term follow-up could only validate the feasibility and success of ligaplants.

REFERENCES

1. Buser, D., Warriner, K., Karring, T. & Stich, H. (1990) Titanium implants with a true periodontal ligament: an alternative to osseointegrated implants? *International Journal Oral Maxillofacial Implants* 5, 113-116.
2. Choi, B. H. (2000) Periodontal ligament formation around titanium implants

using cultured periodontal ligament cells. *International Journal Oral Maxillofacial Implants* 15, 193–196.

3. Y. Lin, G.O. Gallucci, D. Buser, D. Bosshardt, U.C. Belser, and P.C. Yelick. Bioengineered Periodontal Tissue Formed on Titanium Dental Implants; *J Dent Res* 90(2):251-256, 2011.
4. Warrer K, Karring T, Gotfredsen K. Periodontal ligament formation around different types of dental titanium implants.1. The self tapping screw type implant system. *J Periodontol* 1993; 64:29-34.
5. Giannobile WV. 2010. Getting to the root of dental implant tissue engineering. *J ClinPeriodontol*. 37(8):747–749.
6. Nyman S, Gottlow J, Karring T, Lindhe J. The regenerative potential of the periodontal ligament. *J ClinPeriodontol* 1982;9:257-65.
7. Ripamonti U. Recapitulating development : A template for periodontal tissue engineering. *Periodontal Tissue Engineering* 2007; 13(1): 51-71.
8. Gault P, Black A, Romette JL, Fuente F, Schroeder K, Thillou F, Brune T, Berdal A, Wurtz T. 2010. Tissue-engineered ligament: implant constructs for tooth replacement. *J ClinPeriodontol*. 37(8):750–758.
9. Wurtz T. Tissue-engineered ligament: implant constructs for tooth replacement. *J ClinPeriodontol* 2010; 37: 750–8.
10. Ritunja Singh, Swati Raj, Gangesh B. Singh, Anand Mohan Nikunj ,ShilpaChaurasia. Ligaplants:Periodntio – Integrated Implants. *Journal of Dental and Medical Sciences (IOSR-JDMS)* Volume 18, Issue 7 Ser. 7 (July. 2019), PP 61-64.
11. Bharathi D, Siji JT, Srinivasan, Senthil KS. Ligaplants- A review. *Annals of dental speciality* 2017; 5(2): 71-3.
12. Kiong ALS, Arjunkumar R. Tissue-engineered ligament : Implant constructs for tooth replacement (Ligaplants). *J Pharm Sci Res* 2014;6:158-60.
13. Kengo Iwasaki, Kaoru Washio, Walter Meinzer, Yuka Tsumanuma, Kosei Yano, Isao Ishikawa. Application of cell-sheet engineering for new formation of cementum around dental implants; *Heliyon* 5 (2019) e01991.

INDIRECT LAMINATE VENEERS PREPARATION DESIGNS AND MATERIAL SELECTION

Authors:

Dr. Thushara Sudhakaran M.¹
Dr. Prabath Singh V. P.²
Dr. Sapna C. M.³

Post Graduate Student¹
Department of Conservative
Dentistry and Endodontics
Amrita School of Dentistry
Amrita VishwaVidyapeetham
Ponekkara, Kochi, 682041 Kerala

Professor and Head²
Department of Conservative
Dentistry and Endodontics
Amrita School of Dentistry
Amrita VishwaVidyapeetham
Ponekkara, Kochi, 682041 Kerala

Professor³
Department of Conservative
Dentistry and Endodontics
Amrita School of Dentistry
Amrita VishwaVidyapeetham
Ponekkara, Kochi, 682041 Kerala

Address for correspondence:

Dr. Thushara Sudhakaran M
Mekkadan House
P. O. Kodaly, Thrissur 680699
Contact: +91 9846386741
Email:
drthusharasudhakaranm@gmail.com

ABSTRACT

One of the most frequent reasons that patient seeks dental care is discolored anterior teeth. Ceramic laminate veneers, also known as “contact lens,” are capable of providing an extremely faithful reproduction of the natural teeth with great color stability and periodontal biocompatibility. This review article will be discussing different preparation designs and material options of indirect veneer.

Key words: Indirect Laminate Veneers, ceramic, tooth preparation

INTRODUCTION

Aesthetics is a branch of philosophy which deals with beauty and the beautiful (Merriam Webster dictionary).¹ The goal of esthetic dentistry should be "bright, beautiful, but believable."² Charles Reade rightly said that beauty is power; a smile is its sword. Hence a confident smile is one of the most important aspects of one's personality.³ Various treatment modalities for esthetic rehabilitation exist like micro abrasion, direct composite resin restorations or combination of both, indirect composites, crowns, esthetic veneers, and so forth. Restorative aesthetic dentistry should be practiced as conservatively as possible.⁴ With the introduction of adhesive systems more conservative treatment options have emerged. One of the most minimally invasive techniques is the application of laminate veneers made of either ceramics or particulate filler composites.^{5,6} A veneer is a thin covering over another surface.⁷ A dental veneer is a thin layer of tooth colored material that is applied to a tooth to restore localized or generalized defects and intrinsic discolorations.⁸ Between the late 1920's and mid 1930's a Californian dentist called Charles Pincus created the first veneer. The Laminate veneer refers to the combination of tooth, bonding interface and veneer complex. Veneers can be fabricated as indirect restorations using porcelain or composite resin or as a direct restoration using composite resin.

The choice between direct and indirect techniques should be based on tooth vitality preservation, minimum loss of sound tissue, a minimally invasive approach toward the gingival complex, esthetic demands, patient age, financial cost, and total treatment time, the number and extent of involved teeth, type of function, antagonist teeth situation, feasibility of functional and anatomical recovery, and biomechanical resistance of the restored tooth.⁹ Direct techniques provide the maximum preservation of residual sound tissue but with this method, the restorative material must be placed and completed in one appointment and it needs a long chair side time.¹⁰ But Indirect technique provide remarkable advantages like maximum

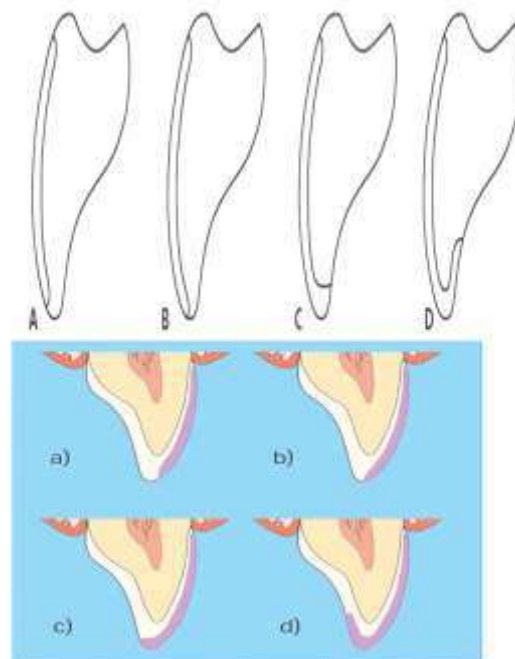
aesthetics optimal control of tooth dimensions, try-in and esthetic evaluation on the hydrated tooth prior to the start of cementation procedures.

INDIRECT VENEER

Veneer shades and contours can be better controlled when made outside the mouth on the cast. Indirect veneers are attached to enamel by acid etching and bonding with a light cured resin cement.

Preparation designs :

- Window preparation
- Feathered-edge
- Butt joint
- Incisal overlap preparation¹¹



- a) Window preparation:-Incisal edge of the tooth is preserved. In this we get ceramic thickness of 0.4 to 0.7 mm near the incisal edge. So can decrease the incidence of ceramic fracture and wear of opposing teeth. But it is difficult to mask the ceramic finish line and there is risk of chipping of

the unsupported enamel on the incisal edge.

- b) Feathered-edge preparation: - The incisal edge of the tooth is prepared buccopalatally, but the incisal length is not reduced. Indicated only in patients with normal overbite. This may be associated with weak veneer, increased risk of ceramic chipping, and difficulty in veneer placement. Poor marginal adaptation has also been reported.
- c) Butt joint or bevel preparation: - The incisal edge of the tooth is prepared labiopalatally, and the length of the incisal edge is reduced (0.5-1mm). Indicated when the incisal edges are thin buccolingually or to increase the incisal length. This design can increase the surface area and avoids sharp angles. But there is high risk of developing ceramic fractures.
- d) Incisal overlap preparations:- The incisal edge of the tooth is prepared Buccopalatally, and the length is reduced (about 2 mm), so the veneer is extended to the palatal aspect of the tooth. Indicated in cases with anterior cross bite or deep overbite. Translucency of incisal edges and a more natural appearance can be given. Palatally the finish line should be above or below the centric lingual contact.¹²

MATERIAL SELECTION

Commonly used materials include processed composites, pressed ceramics and feldspathic porcelain. Ceramic laminate veneer restorations have proven to be durable and aesthetic restorative procedure for treatment of anterior teeth. It maintains the biomechanics of an original tooth. It has got a success rate of approximately 93% over 15 years of clinical use. Several types of ceramic materials are being used now. These materials can be classified according to sinterization temperature, composition and manufacturing technique¹³.

According to composition:-

- 1) Glass based ceramics: Feldspathic

porcelain, IPS Empress, IPS Empress II, and e-max Press.

- 2) Alumina based ceramics: In-ceram Alumina, In-ceram Spinell, In-ceram Zirconia, Procera All Ceram.
- 3) Zirconia Based Ceramics.

Glass Based Ceramics:- Feldspars are mainly comprised of silica dioxide (60% - 64%) and aluminum oxide (20% - 23%) and are modified in different techniques to create glass that can be used in dental restorations.¹⁴ The ideal conditions for the bond between the feldspathic veneer and the substrate are the presence of 50% or more of the bonded substrate being enamel.¹⁵ Traditionally fabricated using layering technique so that can give a naturally looking restoration. But it takes time. With CAD/CAM technology, under precise condition can give fine crystals without pores.¹⁶ Glass ceramics are fabricated through lost wax and heat pressed techniques, or using machinable technique. They can be opaque or translucent.¹⁷ It depends on its composition. Incorporation of fillers like leucite and lithium disilicate crystals, due to their low refractive index can impart translucency.¹⁸

Leucite reinforced glass ceramics (IPS Empress-Ivoclar Vivadent)

Lithium disilicate reinforced ceramics (IPS Empress II—Ivoclar Vivadent)

IPS e-max press- Lithiumdisilicate reinforced - More translucent.

Alumina Based Ceramics:- Includes In-ceram porcelains and Procera All Ceram

In-Ceram Porcelains: These are infused ceramics processed with slip-casting technique. According to the composition In-ceram porcelain is classified into: In-ceram alumina, In-ceram spinell, and In-ceram zirconia.¹⁹

In-ceram Alumina is composed of 85% aluminum oxide particles measuring 2 - 5 µm in diameter. They have low translucency than glass ceramics. In-Ceram Spinell contains a mixture of magnesia and alumina (MgAl₂O₄) in the framework to increase translucency. In-Ceram Zirconia composed of 67% aluminum oxide and 33% partially stabilized zirconium

oxide. In-ceram zirconia has an opaque core that lacks translucency, its opacity is comparable to metal alloy.

Porcera All-Ceram:-This material is fabricated from copings that contain 99.9% high purity aluminum oxide, these copings are coated with conventional aluminum ceramic. Fabricated using dry – pressing technique. High strength and higher level of translucency than In-ceram alumina and zirconia²⁰. These ceramics are not sensitive to hydrofluoric acid etching, so an effective method to roughen the alumina based ceramics is pretreatment by airborne particle abrasion

Zirconia Based Ceramics: - Zirconia based ceramic is polycrystalline material that contain no glass. In this type of ceramic all the atoms are packed into regular crystalline arrays through which it is very difficult to drive a crack. Has three forms – cubic, tetragonal and monoclinic form. Yttrium oxide partially stabilized zirconia (Y-TZP) has got mechanical properties like chemical and dimensional stability, high mechanical strength and fracture toughness. A very high fracture toughness of zirconia even with a very thin thickness accompanied with highly glazed esthetic appearance are main advantages.²¹

CONCLUSION

The minimum-thickness anterior ceramic laminate veneers may be a conservative and esthetic alternative to reestablish the form, shape, and color of anterior teeth. Even though it is one of the most conservative of treatment options, some rules have to be followed. The case has to be carefully selected and treatment planned. Tooth reduction for any restorative technique should be as conservative as possible.

REFERENCES

1. Sowmya K, Dwijendra KS, Pranitha V, Roy KK. Esthetic Rehabilitation with Direct Composite Veneering: A Report of 2 Cases. *Case Rep Dent.* 2017;2017:1–3.
2. McLaren E. Smile Analysis and Esthetic Design: “In the Zone.” inside dentistry; 2009.
3. s DrS, Dr.Shasidhar v, N K, K P. DENTAL LAMINATE VENEERS. *Indian J Dent Sci.* 2014;6(3):59–61.
4. Pascotto R, Pini N, Aguiar FHB, Lima DANL, Lovadino JR, Terada RSS. Advances in dental veneers: materials, applications, and techniques. *Clin Cosmet Investig Dent.* 2012 Feb;9.
5. MM G. Fracture strength of direct versus indirect laminates with and without fiber application at the cementation interface. *Dent Mater;* 2007.
6. R A-H. Indirect Composite Laminate Veneers for Upper Anterior Teeth Diastema Closure: A Case Report. *Int J Dent Oral Health [Internet].* 2016 [cited 2019 May 16];1(4). Available from: <https://www.sciforschenonline.org/journals/dentistry/IJDOH-1-129.php>
7. Vafiadis DC. Smile Design Enhanced with Porcelain Veneers. *Restorative Dent.* :5.
8. Heymann HO, Jr EJS, Ritter AV. *Sturdevant’s Art & Science of Operative Dentistry - E-Book.* Elsevier Health Sciences; 2014. 756 p.
9. Veneziani M. Ceramic laminate veneers: clinical procedures with a multidisciplinary approach. *Clin Res.* 2017;24.
10. Shuman D. Go Green, Go Online to take your course. :9.
11. Chai SY, Bennani V, Aarts JM, Lyons K. Incisal preparation design for ceramic veneers. *J Am Dent Assoc.* 2018 Jan;149(1):25–37.
12. Alothman Y, Bamasoud MS. The Success of Dental Veneers According To Preparation Design and Material Type.

- Open Access Maced J Med Sci. 2018 Dec 14;6(12):2402–8.
13. Sadaqah NR. Ceramic Laminate Veneers: Materials Advances and Selection. Open J Stomatol. 2014;04(05):268–79.
 14. R G. Ceramics Overview: Classification by Microstructure and Processing Methods. Compend Contin Educ Dent. 2010;
 15. E A M. Ceramics: Rationale for Material Selection. Compend Contin Educ Dent. 2010;
 16. Giordano R. Materials for Chairside CAD/CAM-Produced Restorations. J Am Dent Assoc. 2006;
 17. F S. Which All-Ceramic System Is Optimal for Anterior Esthetics? J Am Dent Assoc. 2008;
 18. A DB. Bonding to Ceramics: Scientific Evidences for Clinical Dentistry. Artes Médicas. 2009;
 19. A W. Crowns and other extra-coronal restorations: porcelain laminate veneers. 2002;
 20. M F. Five-Year Follow-Up with Procera All-Ceramic Crowns. Quintessence Int. 2005;
 21. Abuzenada B, Alanazi A, Saydali W, et al. Current classifications and preparation techniques of dental ceramic laminate veneers. Int J Adv Res. 2017 Dec 31;5(12):1973–9.

PHYTOMEDICINES - CURRENT APPLICATIONS IN ENDODONTICS

ABSTRACT

The success of root canal depends on effective disinfection of the entire root canal system. There is no single irrigating solution that alone sufficiently covers all the functions required from an irrigant. Herbal alternatives have come into existence due to the potential side effects, safety concerns and ineffectiveness of the chemical irrigants available now. This review highlights the antimicrobial properties of commonly used herbal medicaments such as *Camellia sinensis*, *Azadirachta indica*, *Aloe barbadensis miller*, *Triphala*, *Morindacitrifolia*, *Propolis*, *Arctium lappa*, *Tachyspermum ammi*, *Curcuma longa*, *Chamomilla recutita* and *Salvadora persica* in endodontics.

Key Words: Phytomedicines, endodontics, *Camellia sinensis*, *Azadirachta indica*, *Aloe barbadensis miller*, *Triphala*, *Morindacitrifolia*, *Propolis*, *Arctium lappa*, *Tachyspermum ammi*, *Curcuma longa*, *Chamomilla recutita*, *Salvadora persica*.

Authors:

Dr. Ashna Beegam K. S.¹

Dr. Prabath Singh V. P.²

Dr. Asha Joseph³

¹Post Graduate Student
Department of Conservative Dentistry
and Endodontics
Amrita School of Dentistry
Amrita Vishwa Vidyapeetham
Ponekkara, Kochi, 682041 Kerala

²Professor and Head
Department of Conservative Dentistry
and Endodontics
Amrita School of Dentistry
Amrita Vishwa Vidyapeetham
Ponekkara, Kochi, 682041 Kerala

³Reader
Department of Conservative Dentistry
and Endodontics
Amrita School of Dentistry
Amrita Vishwa Vidyapeetham
Ponekkara, Kochi, 682041 Kerala

Address for correspondence:

Dr. Ashna Beegam K. S.
Barons 14D
Skyline Imperial Gardens
Stadium Link Road
Kaloor, Kochi 682025
Contact: +91 9846489889
Email: drashnabeegam@gmail.com

J Ind Dent Assoc Kochi 2019;1(3)26-32.

INTRODUCTION

The success, longevity and reliability of modern endodontic treatment depends on the effectiveness of mechanical instrumentation, irrigating solutions, intracanal medicaments and chelating agents to clean, shape and disinfect root canals. The role of microorganisms in the development and perpetuation of pulp and periapical diseases has clearly been demonstrated in animal models and human studies.¹

Elimination of microorganisms from infected root canals is a complicated task. Primary root canal infections are polymicrobial, typically dominated by obligatory anaerobic bacteria.² The most frequently isolated microorganisms before root canal treatment include Gram-negative anaerobic rods, Gram-positive anaerobic cocci, Gram-positive anaerobic and facultative rods, Lactobacillus species, and Gram-positive Streptococcus species. The obligate anaerobes are rather easily eradicated during root canal treatment. On the other hand, facultative bacteria such as Staphylococcus, Enterococci, once established, are more likely to survive chemo mechanical instrumentation and root canal.³ The use of chemical agents during instrumentation to completely clean all aspects of the root canal system is essential for successful outcome of endodontic treatment.²

A wide variety of synthetic antimicrobial agents have been used over the years as endodontic irrigants and intracanal medicaments. But because of their increased antibiotic resistance, toxic and harmful side effects there is a need for alternative agents which are affordable, nontoxic, and effective.⁴ The use of herbs as irrigants and intracanal medicaments is an emerging trend in endodontics.

In Indian culture, the knowledge regarding medicinal plants has been assimilated in the due course of many centuries. The Rigveda has been source of evidence of 67 medicinal plants; 81 species of medicinal plants have been recorded in the Yajurveda, 290 species of medicinal plants have been described in the Atharvaveda, 1,100 species of medicinal plants have been described in the Charak Samhita, and the Sushruta Samhita has been the source

of 1,270 species of medicinal plants and these descriptions form the basis of the classical formulations till date.⁵⁻⁷ WHO has defined herbal medicine as plant derived material or preparation which contains raw or processed ingredients from one or more plants with therapeutic values.⁸

In this review an attempt has been made to understand the role of various phytochemicals such as Camellia sinensis, Azadirachta indica, Aloe barbadensis miller, Triphala, Morinda citrifolia, Propolis, Arctium lappa, Tachyspermum ammi, Curcuma longa, Chamomilla recutita and Salvia officinalis in endodontics.

GREEN TEA

Scientific name : Camellia sinensis

Pharmacological actions : antioxidant, anticariogenic, anti-inflammatory, thermogenic, probiotic and antimicrobial.⁵



Fig. 1: Green tea (Camellia sinensis)

An in vitro study conducted to evaluate the antimicrobial efficacy of triphala, Green tea polyphenols (GTP), MTAD, and 5% sodium hypochlorite against E. faecalis biofilm formed on tooth substrate showed maximum antibacterial activity with NaOCl and statistically significant antibacterial activity with triphala, GTPs and MTAD. NaOCl and MTAD achieved 100% killing of E. faecalis at 2min, whereas triphala and GTP took 6min. The study concluded that green tea polyphenols has potential to be used as an endodontic irrigant.⁹

NEEM

Scientific name : Azadirachta indica



Fig. 2: Neem (*Azadirachta indica*)

Pharmacological actions: antihelminthic, antifungal, antidiabetic, antibacterial, antiviral, contraceptive and sedative.

The antimicrobial efficacy of 2.5% sodium hypochlorite and 0.2% chlorhexidine gluconate were compared with an experimental irrigant formulated from *A. indica* and found that neem irrigant has antimicrobial efficacy and can be considered for endodontic use.¹⁰ Another study evaluated the antimicrobial efficacy of neem against *E. faecalis* in which neem positively showed inhibitory zone comparable to sodium hypochlorite proving that it can be considered as root canal irrigating solutions.¹¹

ALOE VERA

Scientific name : *Aloe barbadensis miller*

Pharmacological actions : antibacterial, moisturizing, anti inflammatory, wound healing.



Fig. 3: Aloe vera (*Aloe barbadensis miller*)

Aloe Vera gel has inhibitory effects on *Streptococcus pyogenes* and *E. faecalis* because of anthraquinone. Its bactericidal activity is found to be less than Ca(OH)_2 .¹² Saturated hydroalcoholic extract of *A. vera* has shown highest zone of inhibition against *E. faecalis* when compared with garlic.¹ Hence *A. vera* can be said to have qualities as an endodontic irrigant and medicament.

TRIPHALA

Scientific name : consist of dried and powdered fruits of three medicinal plants - Amalaki (*Emblica officinalis*), Bibhitaki (*Terminalia bellirica*), and Haritaki (*Terminalia chebula*)

Pharmacological actions : immune system stimulation, carminative, anti diabetic.



Fig4: Triphala

Triphala has shown statistically significant antibacterial activity against 6 week biofilm of *E. faecalis* proving it to be advantageous as an endodontic irrigant.⁹ It also has been found to aid in the removal of smear layer, thereby acting as a chelating agent.¹²

NONI

Scientific name : *Morinda citrifolia*

Pharmacological actions : antibacterial, antiviral, antifungal, antitumor, anthelmintic, analgesic, hypotensive, anti-inflammatory, and immune-enhancing effects

Murray et al. (2008) compared the effectiveness of noni with NaOCl and Chlorhexidine to remove the smear layer from the root canal walls of instrumented teeth and concluded



Fig 5 : Noni (Morindacitrifolia)

that the efficacy of noni was similar to NaOCl in conjunction with EDTA as an intracanal irrigant.¹³

PROPOLIS

Propolis is a resinous yellow brown to dark brown substance which is collected by honey bees (*Apis mellifera*) from tree buds to seal their hives.

Pharmacological actions : antibacterial, antifungal, antiviral, antioxidant, anti-inflammatory properties.



Fig.6:Propolis

The antimicrobial activity of propolis with Ca(OH)₂ as intracanal medicament against *E. faecalis* found that propolis was effective in eliminating the microorganisms. Though propolis has shown very promising results, the clinician should be cautious while using this material due to its allergic reactions shown in some patients.^{14,15}

Al-Qathami and Al-Madi compared the antimicrobial efficacy of propolis, sodium hypochlorite and saline as an intracanal irrigants. Microbiological samples were taken

from the teeth immediately after accessing the canal and after instrumentation and irrigation. The results of this study indicated that the propolis has antimicrobial activity equal to that of sodium hypochlorite.¹⁶

LAPPA

Scientific name: *Arctium lappa* - native flower of Japan.

Pharmacological actions :antibacterial, antifungal, diuretic, antioxidant, anxiolytic, platelet antiaggregating effect, and human immuno deficiency virus (HIV)-inhibitory action.



Fig. 7 :Lappa (*Arctium lappa*)

An in vitro study showed that *Arctium lappa* exhibited antimicrobial potential against tested pathogens such as *Staphylococcus aureus*, *Pseudomonas aeruginosa*, *Enterococcus faecalis*, *Bacillus subtilis*, and *Candida albicans*. Thus, it opens new vistas for its use as an intra canal medicament.¹⁷

AJWAIN

Scientific name :*Tachyspermum ammi*

Pharmacological actions : antioxidant, antiseptic, carminative, antifungal, antibacterial.

Amanthi Ganapathi et al had compared the antimicrobial efficacy of ajwain on oral microbes and concluded that ajwain has very effective antimicrobial property against *E. faecalis* and *S. mutans*.¹⁸ Ajwain has potential



Fig. 8 :Ajwain (Tachyspermum ammi)

to be used as endodontic medicament and irrigant.¹⁹

TURMERIC

Scientific name :Curcuma longa

Pharmacological actions : antioxidant, anti-inflammatory, anti mutagenic, antiplatelet, antibacterial, antiparasitic.



Fig. 9:Turmeric (Curcuma longa)

Curcumin has shown to exhibit phototoxic effects against gram positive and gram negative bacteria, hence they can be used for photo dynamic therapy in root canal treatment.²⁰

Studies also have shown that curcumin inhibits E.faecalis bio film formation showing that it has potential to be used as an irrigant in endodontics.²¹

GERMAN CHAMOMILE

Scientific name : Chamomillarecutita

Pharmacological actions: anti-inflammatory, analgesic, antimicrobial, antispasmodic, sedative

Chamomile has been effective in removing the smear layer significantly when compared to distilled water and tea tree oil.²²



Fig. 10 :
German chamomile (Chamomillarecutita)

MESWAK

Scientific name :Salvadora persica

Pharmacological actions : antiplaque, antiperiopathic, anticaries, anti-inflammatory, antimycotic.



Fig. 11:Meswak (Salvadora Persica)

Al-subawi et al conducted a study to compare anti microbial activity of meswak and found that it has equal effectiveness as that of sodium hypochlorite and chlorhexidine when used as an endodontic irrigant.²³

CONCLUSION

Herbal medicines are gaining popularity as they are generally safe if used with proper knowledge. Herbal formulations are showing promising results as irrigants and intracanal medicaments and can be used for endodontic procedures with minimal risks involved. However further research is necessary to incorporate these phytomedicines into oral health care products.

REFERENCES

- Karkare S, Ahire N, Khedkar S. Comparative evaluation of antimicrobial activity of hydroalcoholic extract of Aloe vera, garlic, and 5% sodium hypochlorite as root canal irrigants against *Enterococcus faecalis*: An in vitro study. *J Indian Soc Pedod Prev Dent*. 2015;33(4):274.
- Shen Y, Stojicic S, Qian W, Olsen I, Haapasalo M. The synergistic antimicrobial effect by mechanical agitation and two chlorhexidine preparations on biofilm bacteria. *J Endod*. 2010;(36):100-4.
- Zehnder M. Root canal irrigants. *J Endod*. 2006;(32):389-98.
- Kamat S, Rajeev K, Saraf P. Role of herbs in endodontics. An update. *Endodontology*. 2011;(23):98-102.
- Seal M, Rishi R, Satish G, Divya K, Talukdar P, Maniyar R. Herbal panacea: The need for today in dentistry. *J Int Soc Prev Community Dent*. 2016;6(2):105.
- Kumar G, Jalaluddin M, Rout P, Mohanty R, Dileep CL. Emerging trends of herbal care in dentistry. *J Clin Diagn Res*. 2013;(7):1827-9.
- Taheri JB, Azimi S, Rafieian N, AkhavanZanjani H. Herbs in dentistry. *Int Dent J*. 2011;(61):287-96.
- Penumudi SM, Mandava RB, D DS, Santhi V, B S, Gandhi B. Antimicrobial Efficacy of Herbs in Endodontics. *J Adv Oral Res*. 2015 Jan;6(1):9-12.
- Prabhakar J, Senthilkumar M, Priya MS, Mahalakshmi K, Sehgal PK, Sukumaran VG. Evaluation of Antimicrobial Efficacy of Herbal Alternatives (Triphala and Green Tea Polyphenols), MTAD, and 5% Sodium Hypochlorite against *Enterococcus faecalis* Biofilm Formed on Tooth Substrate: An In Vitro Study. *J Endod*. 2010 Jan;36(1):83-6.
- Dutta A, Kundabala M. Comparative antimicrobial efficacy of Azadirachtaindicairrigant with standard endodontic irrigants: A preliminary study. *J Conserv Dent*. 2014;(17):133-7.
- Babaji P, Jagtap K, Lau H, Bansal N, Thajuraj S, Sondhi P. Comparative evaluation of antimicrobial effect of herbal root canal irrigants (*Morindacitrifolia*, *Azadirachtaindica*, *Aloe vera*) with sodium hypochlorite: An in vitro study. *J Int Soc Prev Community Dent*. 2016;6(3):196.
- Prakash S, Shelke AU. Role of triphala in dentistry. *J Indian Soc Periodontol*. 2014;(18):132-5.
- Murray PE, Farber RM, Namerow KN, Kuttler S, Garcia-Godoy F. Evaluation of *Morindacitrifolia* as an endodontic irrigant. *J Endod*. 2008;(34):66-70.
- Parolia A, Thomas MS, Kundabala M, Mohan M. Propolis and its potential uses in oral health. *Int J Med Sci*. 2010;(2):210-5.
- Propolis Extracted from the Stingless Bee *Trigonasirindhornae* Inhibited *S. mutans* Activity In Vitro. *Oral Health Prev Dent*. 2017 Jul 7;15(3):279-84.
- Al-Qathami H, Al-Madi E. Comparison of sodium hypochlorite, propolis and saline as root canal irrigants: A pilot study. *Saudi Dent J*. 2003;(5):100-2.
- Pereira JV, Bergamo DC, Pereira JO, FrançaSde C, Pietro RC, Silva-Sousa YT. Antimicrobial activity of *Arctiumlappa* constituents against microorganisms commonly found in endodontic infections. *Braz Dent J*. 2005;(16):192-6.
- AmanthiGanapathi, Anitha Roy, RV Geetha. Antimicrobial effects of *Tachyspermumammi* on oral microbes. *Int J Sci Eng Res*. 8(4):80-5.
- Kumar H. An in vitro evaluation of the antimicrobial efficacy of *Curcuma longa*,

Tachyspermumammi,
chlorhexidinegluconate, and calcium
hydroxide on *Enterococcus faecalis*.
J Conserv Dent. 2013;16(2):144.

20. PrasannaNeelakantan,
NithyaJagannathan, NabeelNazar.
Ethnopharmacological approach in
endodontic treatment: A focused review.
Int J Drug Dev Res. 2011;3(4):68-77.
21. Neelakantan P, Subbarao C, Sharma S,
Subbarao CV, Garcia-Godoy F, Gutmann JL.
Effectiveness of curcumin against
Enterococcus faecalis
biofilm. *Acta Odontol Scand*.
2013;71(6):1453-7.
22. Sadr Lahijani MS, RaoofKateb HR, Heady
R, Yazdani D. The effect of German
chamomile (*Martianthus annuus* L.) extract
and tea tree (*Melaleuca alternifolia* L.) oil
used as irrigants on removal of smear
layer: A scanning electron microscopy
study. 2006;(39):190-5.
23. Al-subawi NA, Abdull-khalik K, Mahmud
Y, Taha MY, Abdul A. The anti microbial
activity of *Salvadora persica* solution
(Miswak-siwak) as root canal
Irrigant. *Univ Sharjah J Pure Appl Sci*.
2007;(4):69-91.

MANAGEMENT OF ROTARY FILE SEPARATION IN MANDIBULAR MOLAR - CASE REPORT

Authors:

Dr. Rohit Alapuzha Mihir¹
Dr. Prabath Singh V. P.²
Dr. Anisha E. A.³

Department of Conservative¹
Dentistry and Endodontics
Amrita School of Dentistry
Amrita VishwaVidyapeetham
Ponekkara, Kochi, 682041 Kerala

Professor and Head²
Department of Conservative
Dentistry and Endodontics
Amrita School of Dentistry
Amrita VishwaVidyapeetham
Ponekkara, Kochi, 682041 Kerala

Department of Conservative³
Dentistry and Endodontics
Amrita School of Dentistry
Amrita VishwaVidyapeetham
Ponekkara, Kochi, 682041 Kerala

Address for correspondence:

Dr. Prabath Singh V. P.
Professor and Head
Department of Conservative
Dentistry and Endodontics
Amrita School of Dentistry
Amrita VishwaVidyapeetham
Ponekkara, Kochi, 682041 Kerala
Email: drprabathendo@gmail.com

ABSTRACT

Intracanal separation of endodontic instruments may hinder cleaning and shaping procedures within the root canal system, with a potential impact on the outcome of treatment. A separated instrument in the root canal interferes with root canal cleaning, shaping, filling, and negatively affects the patient's experience. The ideal solution of the problem is to remove the separated instrument without any complication. However, the retrieval of separated instruments is one of the most difficult operations in endodontic treatment, which is time consuming and requires skillful operation, advanced techniques, and professional equipment. In addition, there are considerable risks during the retrieval process, such as ledge formation, re-fracture of instruments, and perforation or vertical cracks due to over-preparation of root canals. The retrieval rate of separated instruments is affected by multiple factors such as the tooth position, the root canal curvature, the depth, length, type, and material of separated instruments. This is a clinical case report of instrument separation at orifice level in mandibular molar. Treatment consisted of retrieval of separated instrument with the aid of a dental operating microscope and completion of endodontic therapy.

Key words: Intracanal separation, root canal curvature

INTRODUCTION

Separation of endodontic instruments within the root canal is an unfortunate occurrence that may hinder root canal procedures and affect the outcome. Although many factors contribute to instrument separation, the exact mode of separation is not fully understood. It has been reported that the prevalence of separated instrument ranges from 2 to 6% by Tronstad et al and 0.5 to 5% by Iqbal et al. This reflects the complexity of the separation process, the interaction of causal forces (torsional and bending), and contributing factors. The composition and design of root canal instruments have been modified, with the aim of achieving better performance and fewer undesirable complications including instrument separation.

The advent of nickel-titanium (NiTi) alloys has not resulted in a lower incidence of instrument separation. Whereas separation rates of stainless steel (SS) instruments have been reported to range between 0.25% and 6%, the separation rate of NiTi rotary instruments has been reported to range between 1.3% and 10.0%. Even in experienced hands, this problem can still occur and frustrate both practitioners and patients.

CASE REPORT

A 34-years old male patient reported to the department of conservative dentistry and endodontics with a chief complaint of pain in the left lower molar tooth since three weeks. Clinically the tooth presented with deep dentinal caries w.r.t 37. Tooth was severely tender to percussion and vitality tests showed painful response to hot, cold and electrical pulp tests. Iopar revealed radiolucency approximating pulp chamber [Fig.1]. From clinical and radiographic findings, a diagnosis of symptomatic apical periodontitis secondary to irreversible pulpitis was made. Treatment options were discussed with the patient and endodontic therapy was the treatment of choice. The tooth was anesthetised with 1.8 ml 2% lignocaine containing 1:200,000 adrenaline followed by rubber dam isolation. Access was prepared to locate all canal orifices and four

canal orifices were found-mesiobuccal, mesiolingual, distobuccal and distolingual. All the canals were negotiated using a 10-k file. While enlarging the orifice of distolingual canal, the orifice shaper with tip diameter of 0.19 separated leaving a length of 6mm at the orifice level [Fig.2].

Since the fractured segment could be visualised and was above the root curvature, retrieval was preferred over bypassing. Exact location of separated instrument within the canal was confirmed under the Dental operating microscope. Ultrasonic tip ET25 (Acteon, Satelec) [Fig.3] in ultrasonic hand piece at a power setting of 3, was placed into the distolingual canal between the exposed end of the file and the canal wall and activated around the obstruction in a counter clockwise direction to remove dentin around the fractured instrument and loosen it. Following the ultrasonic activation, the instrument fragment floated out from the distolingual canal [Fig.4]. Working length was established with the help of an apex locator (J Morita Inc, USA). During the shaping of canals, copious irrigation with 3% sodium hypochlorite and saline was performed. Patency was kept with a 10 size K file between every instrument. Shaping of all four canals were done upto #0.06/25. Canals were irrigated with 3% sodium hypochlorite, 17% EDTA and 2% chlorhexidine. Canals were dried using paper points and a master cone radiograph [Fig.5] was taken to check the apical fit in all the four canals. Finally canals were obturated with gutta-percha and AH plus sealer (Dentsply) by warm vertical compaction [Fig.6]. The access preparation was sealed and the post endodontic composite restoration was done.

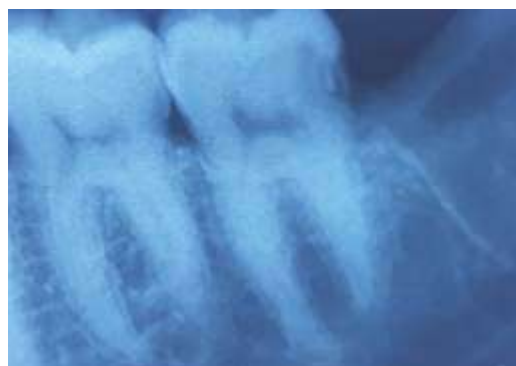

Fig.1

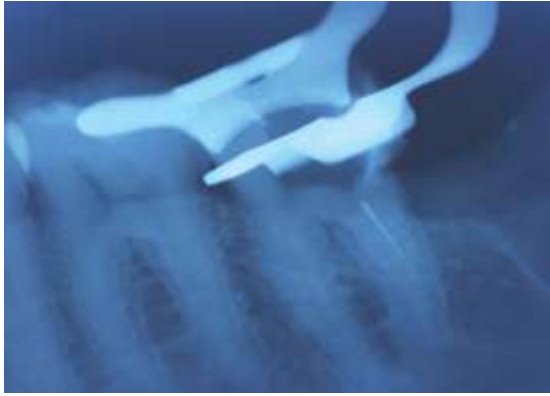

Fig.2



Fig.3

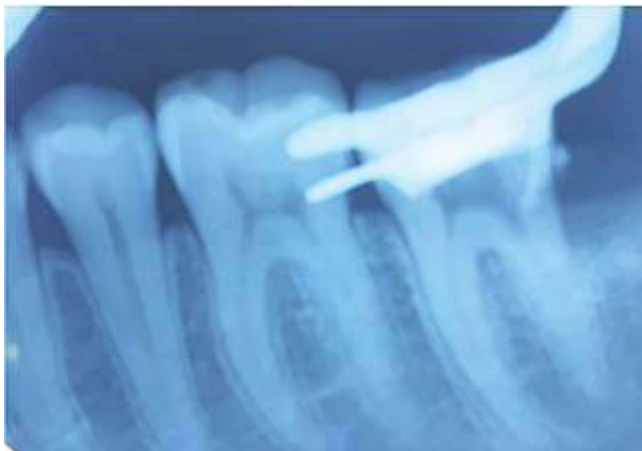

Fig.4

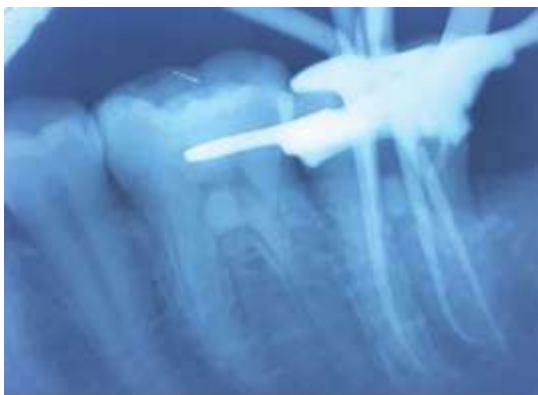

Fig.5

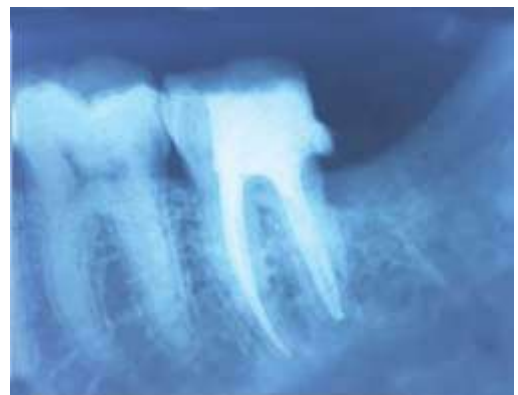

Fig.6

DISCUSSION

Separated root canal instruments are one of the most troublesome incidents in endodontic therapy, especially if the tooth is non-vital and fragment cannot be removed. In the majority of cases, the procedural mishap does not directly compromise the prognosis, unless a concomitant infection is already present. Separated fragment of instrument in root canal may be indirectly responsible for an endodontic failure by limiting the access to the apical part of the canal, compromising disinfection and obturation, but is rarely directly responsible.

The four treatment protocols have been suggested by the literature for management of fractured instruments in root canals:

1. Allowing the separated instrument to be retained in the canal and treating the remaining portion of canal.
2. Bypassing the separated fragment and treating the canal.
3. Retrieving the separated fragment and treating the canal.
4. Surgical approach for retrieval of separated fragment followed by treatment accordingly.

Favourable factors for the removal of a fractured instrument are straight canals, incisors and canines; localisation before the curvature; length of fragment of more than 5 mm; localisation in the coronal or middle third of the root canal; reamer or lentulo spirals; and hand NiTi K-files. Thermoplasticized obturation techniques were suggested in these cases since they seal the gap between the fractured fragment and canal walls better than other techniques like cold lateral compaction, single greater tapered cone obturation, because of their excellent flow.

CONCLUSION

The decision on management should consider the following.

- Constraints of the root canal accommodating the fragment.
- The stage of root canal instrumentation at which the instrument separated.
- The expertise of the clinician, armamentaria available.
- The strategic importance of the tooth involved.
- The presence/or absence of periapical pathosis.

REFERENCES

1. Torabinejad M, McDonald NJ. Endodontic surgery. In: Torabinejad M, Walton RE, eds. *Endodontics Principles and Practice*, 4th ed. St Louis: Elsevier Health Sciences; 2009:357–75.
2. Qian Yang, YaShen, Dingming Huang, Xuedong Zhou, Yuan Gao, Markus Haapasalo. Evaluation of Two Trephine Techniques for Removal of Fractured Rotary Nickel-titanium Instruments from Root Canals. *J Endod* 2017;43:116–120.
3. Iqbal MK, Kohli MR, Kim JS. A retrospective clinical study of incidence of root canal instrument separation in an endodontics graduate program: a PennEndo database study. *J Endod* 2006;32:1048–52.
4. Tuomas K. Niemi, Melissa A. Marchesan, Adam Lloyd, Robert J. Seltzer. Effect of Instrument Design and Access Outlines on the Removal of Root Canal Obturation Materials in Oval-shaped Canals. *J Endod* 2016;42:1550–1554.
5. Bahcall JK, Carp S, Miner M, Skidmore L. The causes, prevention, and clinical management of broken endodontic rotary files. *Dent Today* 2005;24. 74, 76, 78–80.
6. Di Fiore PM. A dozen ways to prevent nickel-titanium rotary instrument fracture. *J Am Dent Assoc* 2007;138:196–201. quiz 249.
7. Madarati AA, Watts DC, Qualtrough AJ.

Factors contributing to the separation of endodontic files. Br Dent J 2008;204:241-5.

8. Tzanetakis GN, Kontakiotis EG, Maurikou DV, Marzelou MP. Prevalence and management of instrument fracture in the postgraduate endodontic program at the Dental School of Athens: a five-year retrospective clinical study. J Endod 2008;34:675-87.
9. Madarati AA, Watts DC, Qualtrough AJ. Opinions and attitudes of endodontists and general dental practitioners in the UK towards the intracanal fracture of endodontic instruments: part1. IntEndod J 2008;41:693-701.
10. Madarati A.A., Hunter M.J., Dummer P.M.: Management of intracanal separated instruments. JEndod 2013; 39: pp. 569-581

MUCOCELE ON THE VENTRAL SURFACE OF TONGUE: A RARE CASE REPORT

ABSTRACT

Mucoceleles represent one of the most common lesions of the oral cavity, developing as a result of saliva accumulation. The most frequent affected area is the lower lip, followed by floor of mouth, ventral tongue and buccal mucosa. Mucoceleles originating on the ventral surface of the tongue are less common (4.9%). In this report a mucocele developed on the dorsal tongue of a 17 year-old male is described. Additionally a review of previously published mucoceleles on the ventral surface of the tongue is provided and discussed.

Keywords: Mucocele, Blandin, Nuhn, Salivary gland.

Authors:

¹Dr. Deepthi T. R.

²Dr. Sajeesh Raj A.

³Dr. Veena S. N.

⁴Dr. Adarsh V. J.

¹MDS (Oral Medicine and Radiology)
Private Dental Practitioner

²Post Graduate Student
Department of Oral and Maxillofacial Surgery
Coorg Institute of Dental Sciences
Virajpet 571218, Karnataka

³Professor and Head
Department of Oral Medicine and Radiology
Coorg Institute of Dental Sciences
Virajpet 571218, Karnataka

⁴Reader
Department of Oral Medicine and Radiology
Mahe Institute of Dental Sciences and Hospital
Chalakkara, Palloor,
Mahe 673310

Address for correspondence

Dr. Sajeesh Raj A.
Post Graduate Student
Department of Oral and Maxillofacial Surgery
Coorg Institute of Dental Sciences
Virajpet 571218, Karnataka
Email: srajkadavoor@gmail.com

J Ind Dent Assoc Kochi 2019;1(3)38-42.

INTRODUCTION

Mucoceles are one of the most common benign soft tissue masses that occur in the oral cavity. Mucoceles (muco – mucus and coele -cavity) by definition are cavities filled with mucus.^{1,2} Allcystic lesions of the minor salivary glands, collectively and clinically referred to as mucoceles, are described as either the extravasation type or the retention type. The term mucus extravasation phenomenon (or escape reaction) is used when mucus has been extruded into the connective tissue and is surrounded by a granulation tissue envelope. The term mucus retention cyst is used to describe a cyst with retained mucin, which is lined by ductal epithelium.³

CASE REPORT

A 17 year old male reported with the chief complaint of swelling on the ventral surface of the tongue. Pt had difficulty in having food. The swelling was round tooval in shape with a central bluish discoloration, measuring approximately 3×2 cm indimension with no history of bleeding or any discharge from the swelling. There was no visible pulsation. On palpation, it was fluctuant and nontender [figure1]. Diascopy test was negative (figure 2). The patient had been aware of the swelling for approximately since 15 days but denied any episodic increase or reduction in size. Rest of the medical and dental history was non contributory. Based on the clinical examination and history, a provisional diagnosis of mucocele was made. On FNAC, thick mucinous fluid was obtained. Marsupialization was performed and the wound was closed with vicryl 4-0 sutures. The biopsy sample was immediately fixed in 10% formalin and sent for histologic evaluation. Microscopy demonstrated normal looking muscle tissue with single cystic area lined by macrophage. The pathologic report suggested extravasation type mucocele [Figure 3].

DISCUSSION

Epidemiology: Mucoceles represent prevalence of 2.4 cases per 1000 people. Mucoceles appear with higher frequency in children than in

adults and are associated with traumatic injuries. Commonly seen on lower lip- lateral to midline and less common sites been anterior ventral tongue, buccal mucosa, palate and retromolar pad. Mucoceles of the anterior lingual salivary glands (glands of Blandin and Nuhn) are relatively uncommon, this type of mucocele represents an estimated 2–8% of all mucoceles. Out of the 400 cases of mucocele reviewed by Harrison only 9 cases were on the tongue. Joshi SR et al investigated the clinical and histopathologic features of 30 cases of mucocele of glands of Blandin-Nuhn. They concluded that all the lesions were located on the ventral surface of the tongue. These lesions were situated at the midline in 24 patients and laterally in 6 patients. They also found that there was a female predominance, and most patients were younger than 15 years. Histopathological examination showed extravasation type of mucocele with a prevalence of 1.4/1000 persons. In the present case series we reported 2 cases which were present on the ventral surface of the tongue and on the buccal mucosa.

Classification

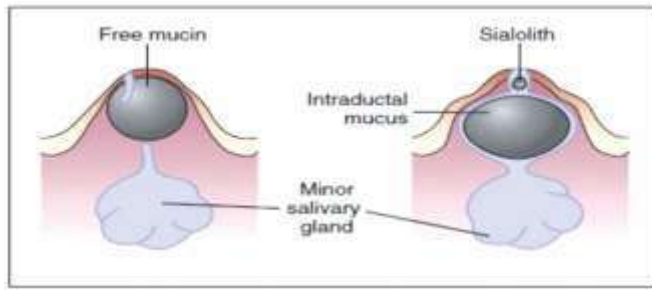
Extravasation type:

The formation of an extravasation mucocele is the result of trauma to a minor salivary gland excretory duct or laceration of the duct results in the pooling of saliva in the adjacent sub mucosal tissue and consequent swelling. Although often termed a cyst, the extravasation mucocele does not have an epithelial cyst wall.

Retention type:

The retention mucocele is caused by obstruction of a minor salivary gland duct by calculus or possibly by the contraction of scar tissue around an injured minor salivary gland duct. The blockage of salivary flow causes the accumulation of saliva and dilation of the gland / duct. These are the epithelium lined cysts arising from salivary gland tissue.

Mucous extravasation phenomenon showing free mucin in the submucosa and mucous retention cyst (right), showing mucin retrained



in the salivary excretory duct because of blockage by a sialolith.

Etiopathogenesis

The origin of mucocele remains elusive. A hypothesis suggested that obliteration of the salivary gland ducts is the cause of mucocele. However, this hypothesis has weakened against the traumatic origin of the lesions. A case series implicated trauma and nibbling of fingers in 34% of the cases as the cause for mucocele. The typical location of these lesions is in the lower lip. These areas are more susceptible to accidental trauma or nibbling and suction habits. Presence of the lesion in young patients, and the rare presence of calculi in the minor salivary glands support this etiopathogenic theory. According to another hypothesis, mucoceles may develop as a result of a traumatic defect or severance of salivary duct and escape of saliva into the tissue. Therefore, Standish and Shafer expressed the opinion that rupture of an excretory duct allows for the escape of mucus into adjacent tissues, but they also considered the possibility of dilatation of a partially occluded duct. The presence or absence of epithelium in a mucous cyst (extravasation/retention) also appears to be related to the pathogenesis. Robinson L concluded that ductal dilatation occurs consequent to ductal obstruction. The dilated ducts may then fuse together to form an epithelium lined cystic cavity.

The human tongue contains three distinct sets of minorsalivary glands, namely, the glands of vonEbner, the glands of Weber, and the glands of Blandin and Nuhn. The glands of Blandin and Nuhn are mixed mucus and serous glands that are embedded within the musculature of the ventral surface of the anterior tongue. They are not lobulated or encapsulated.

Each gland is approximately 1–8 mm wide and 12–25mm deep and consists of several small independent glands. They drain by means of 5–6 small ducts that open near the lingual frenum. These glands extend laterally and posteriorly from the midline,

forming a mass resembling a horseshoe with its opening pointing towards the root of the tongue.

They have been postulated to be the result of trauma to the ventral surface of tongue that results in rupture of the draining ducts. The solitary, smooth, nodular submucosal lesions of the tongue can be clinically differentiated as schwannoma, neurofibroma, rhabdomyoma, lymphangioma, fibroma, lipoma, leiomyomas, inflammatory lesions such as fibroepithelial polyp, and benign salivary gland tumors and mucocele.

Mucoceles on the tongue are rare and occur almost exclusively on the ventral surface where the glands of Blandin and Nuhn are located. The mucocele is located directly under the mucosa (superficial mucocele), in the upper submucosa (classic mucocele), or in the lower corium (deep mucocele). The clinical presentation of these lesions depends upon their depth within the soft tissue and the degree of keratinization of the overlying mucosa; superficial lesions present as raised soft tissue swelling that is translucent and having bluish color, whereas the deeper lesions are more nodular, lack the vesicular appearance, and have a normal mucosal color¹. Palpation can be helpful for a correct differential diagnosis. Lipomas and tumors of minor salivary glands present no fluctuation whereas cysts, mucoceles, abscess, and hemangiomas. Presence of mucoceles on the dorsal surface of the tongue is not yet reported. Regarding superficial mucoceles, trauma does not always appear to play an important role in pathogenesis. In many cases, mucosal inflammation that involves the minor gland duct results in blockage, dilatation, and rupture of the duct with sub epithelial spillage of fluid. Changes in minor salivary gland function and composition of the saliva may contribute to their development. Histologically, mucoceles are classified as retention and extravasation

types. Mucocele involving the glands of Blandin and Nuhn are often histologically diagnosed as being extravasation type. Mucoceles can easily traumatize and become a strong source of irritation and annoyance to the patient. These lesions are often asymptomatic, however, as they grow in size, they can cause discomfort, external swelling, and interfere with speech and mastication. Thus, surgical excision is the treatment of choice. Usually, the surgical excision includes the servicing mucous glands with evacuation of its contents. Healing without complication or recurrence should follow.

In small mucocele cases, they are completely excised with primary closure, with rapid and uneventful healing. On the other hand, larger lesions may also be managed by marsupialization, cryosurgery¹⁰, laser ablation, and micromarsupialization.

CONCLUSION

In these case reports we describe the

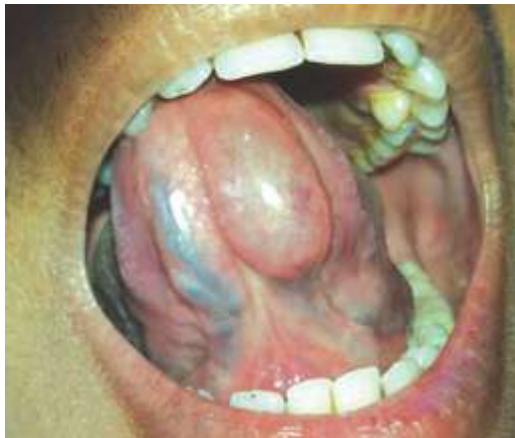

Figure 1: Mucocele on the ventral surface on the tongue.

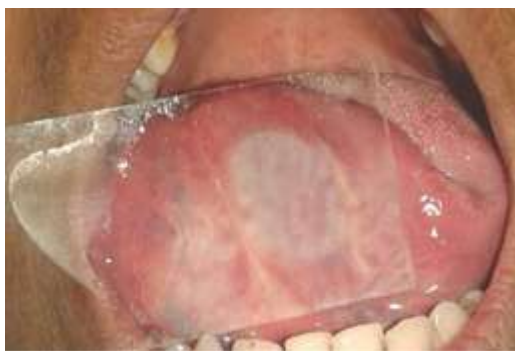

Figure 2: Diascopy test negative

mucoceles of the oral cavity which is located on the rare sites on the buccal mucosa and ventral surface of the tongue.

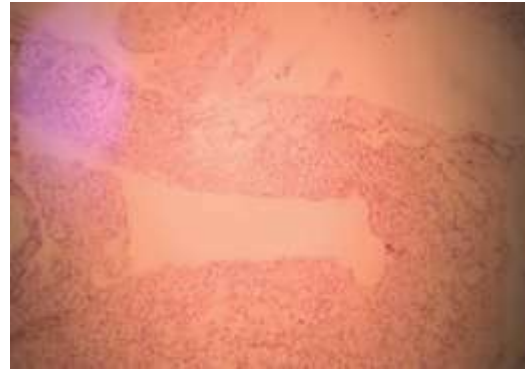
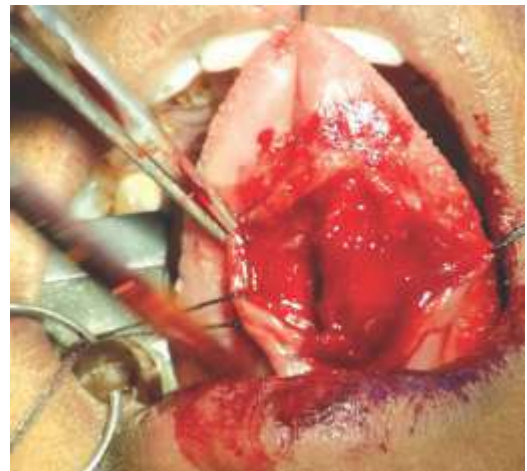
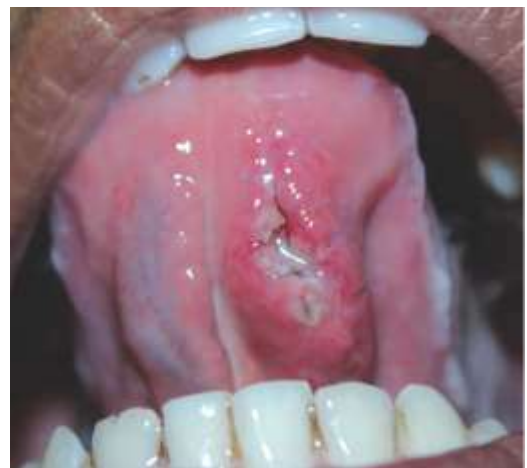
Fig 3: Histopathological picture

The histopathological picture showed fibrous connective tissue with foci of pooled mucin along with muciphages and neutrophils. Associated minor salivary gland acini and ducts were also seen.



INTRA OPERATIVE PHOTOGRAPH



POST OPERATIVE PHOTOGRAPH

REFERENCES

1. Shafer's Textbook of oral pathology. 5th ed. New Delhi; Saunders; 1993.
2. Burket's. Textbook of oral medicine. 12th ed. New Delhi: BC Decker; 2013.
3. Cecconi DR, Achilli A, Tarozzi M, Lodi G, Demarosi F, Sardella A, Carrassi A. Mucoceles of the oral cavity: A large case series (1994–2008) and a literature review. *Med Oral Pathol Oral Cir Bucal*. 2010 Jul 1;15(4):e551-6.
4. Joshi SR, Pendyala GS, Choudhari S, Kalburge J. Mucocele of the glands of Blandin–Nuhn in children: a clinical, histopathologic, and retrospective study. *N Am J Med Sci* 2012 Sep;4(9):379..
5. Ata-Ali J, Carrillo C, Bonet C, Balaguer J, Peñarrocha M, Penarrocha M. Oral mucocele: review of the literature. *J Clin Exp Dent*. 2010 Feb;2(1):e18-21.
6. Cecconi DR, Achilli A, Tarozzi M, Lodi G, Demarosi F, Sardella A, Carrassi A. Mucoceles of the oral cavity: A large case series (1994–2008) and a literature review. *Med Oral Pathol Oral Cir Bucal*. 2010 Jul 1;15(4):e551-6..
7. Khalekar YJ, Sande AR, Zope A, Suragimath A. Mucocele of tongue: A rare case report. *J Indian Acad Oral Med Radiol*. 2016 Oct 1;28(4):462.
8. Sugerman PB, Savage NW, Young WG. Mucocele of the anterior lingual salivary glands (glands of Blandin and Nuhn): Report of 5 cases. *Oral Surg Oral Med Oral Pathol Oral Radiol Endo* 2000;90:478-82.
9. Poker ID, Hopper C. Salivary extravasation cyst of the tongue. *Br J Oral Maxillofac Surg* 1990;28:176-7.
10. Kopp WK, St-Hilaire H. Mucosal preservation in the treatment of mucocele with CO2 laser. *J Oral Maxillofac Surg* 2004;62:1559-61.



JIDAK

JOURNAL OF INDIAN DENTAL ASSOCIATION - KOCHI