

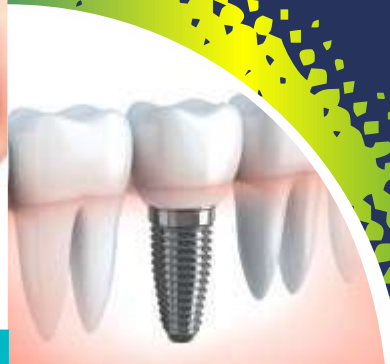

[www.idakochi.org](http://www.idakochi.org)

# JIDAK

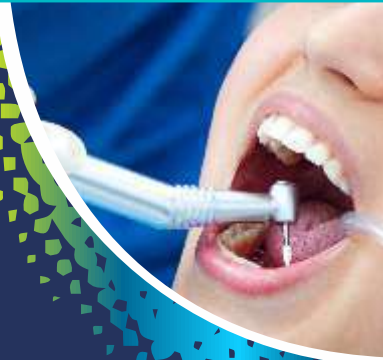April - June 2019, Volume 1, Issue 2

JOURNAL OF INDIAN DENTAL ASSOCIATION - KOCHI



INDIAN DENTAL ASSOCIATION

KOCHI BRANCH





[www.idakochi.org](http://www.idakochi.org)

# JIDAK

April-June 2019, Volume 1, Issue 2

**JOURNAL OF INDIAN DENTAL ASSOCIATION - KOCHI**

Journal of Indian Association of Kochi Branch (JIDAK) is the official scientific publication of Indian Dental Association, Kochi Branch. It is a peer-reviewed journal published quarterly in e-format as well as print format.

The journal invites manuscripts from dental and other allied health sciences. It publishes manuscripts under categories of Original Research, Review and Case Reports.

For submission of manuscripts,  
log on to [www.jidakochi.org](http://www.jidakochi.org).  
For communications,  
mail to [jidakochi@gmail.com](mailto:jidakochi@gmail.com).

## EDITORIAL BOARD

### Co-editors:

Dr. Nivedita B.  
Dr. Noorudeen A. M.  
Dr. Prashant P. S.  
Dr. Sunil M. Eraly  
Dr. Pooja Latti  
Dr. Vidya Parameshwaran  
Dr. Esha Madhu  
Dr. Sobitha G.  
Dr. Radhakrishnan

### Advisory Board

Dr. Anjana G.  
Dr. V. I. Paul  
Dr. Bindu Rachel Thomas  
Dr. Siby T. Chennankara

### Chief Editor

Dr. Meera Gopalakrishnan

### Editor in Charge

Dr. Subramaniam R.

## *Chief Editors Message*

Greetings and Onam wishes from Team JIDAK!

It is with almost pride and satisfaction we are releasing the second issue of JIDAK which coincides with the Grand festival Onam!!

We assure you our continuous commitment towards academic enrichment and awareness among the dental fraternity and we vouch that we will fiercely stick on to that motto of JIDAK.

In this endeavour to make JIDAK the most sought after dental reference journal, we request everyone's support and blessings!

Thank u

Jai JIDAK

Jai IDA



**Dr. Meera Gopalakrishnan**  
Chief Editor- JIDAK  
IDA Kochi

# CONTENTS

|   |       |
|---|-------|
| COMPARATIVE EVALUATION OF SHEAR BOND STRENGTH OF GLASS IONOMER CEMENT AND COMPOSITE RESIN TO MINERAL TRIOXIDE AGGREGATE<br>Dr. M. A. Shreya, Dr. Sunil M. Eraly, Dr. Priya R.,<br>Dr. Renjith Raj, Dr. Anju N. V., Dr. Sajana Rajan | 02-05 |
| RISK FACTORS AND TREATMENT MODALITIES FOR MANAGEMENT OF OBSTRUCTIVE SLEEP APNEA<br>Dr. Parvathy Ghosh, Dr. Pillai Devu Radhakrishnan  | 06-12 |
| SMART MATERIALS IN PEDIATRIC DENTISTRY - A REVIEW<br>Dr. Malini Venugopal   | 13-20 |
| DENTAL MIMICRY - AN EMERGING CONCEPT IN DENTAL THERAPY<br>Dr. Vinutha Manjunath, Dr. Natasha Habib  | 21-31 |
| THE WONDERLIGHT: PHOTOBIO-MODULATION IN THE MANAGEMENT OF RECURRENT APHTHOUS STOMATITIS<br>Dr. Esha Nausheen, Dr. Madhu Hariharan,<br>Dr. Kaushik Haridas, Dr. Ravikant   | 32-36 |
| MANAGEMENT OF BILATERALLY MISSING MAXILLARY LATERAL INCISORS WITH STRATEGIC IMPLANTS - A CASE REPORT<br>Dr. Prasanth Pillai, Dr. Bobby Antony   | 37-43 |
| CRUCIAL RADIOGRAPHIC APPRAISAL OF ROOTS - A KEY TO ENDODONTIC SUCCESS<br>Dr. Ravindra Jagannath Jadhav, Dr. Sudha Mattigatti<br>Dr. Lygi C. John, Dr. Prachi Ingale   | 44-50 |

# COMPARATIVE EVALUATION OF SHEAR BOND STRENGTH OF GLASS IONOMER CEMENT AND COMPOSITE RESIN TO MINERAL TRIOXIDE AGGREGATE

## ABSTRACT

**Aim:** To evaluate the shear bond strength of glass ionomer cement (GIC) and composite resin (CR) to Mineral trioxide aggregate (MTA).

**Methodology:** Twenty acrylic blocks, having a central cavity with 4 mm diameter and 2 mm depth were prepared. MTA Angelus was mixed and placed in the prepared cavity after the setting times of 15 minutes. The specimens were then randomly divided into 2 groups. GROUP A: GIC – Glass ionomer cement and GROUP B: CR-Composite resin. The specimens were tested for shear bond strength using universal testing machine and readings were statistically analyzed.

**Result:** The shear bond strength of CR (0.5357) with MTA was significantly better than GIC with MTA.

**Conclusion:** Composite resin is preferred material over MTA as it has higher bond strength when compared to GIC.

**Keywords:** Mineral trioxide aggregate, Glass ionomer cement, Composite Resin, Shear bond strength.

## Authors:

Dr. M. A. Shreya<sup>1</sup>  
Dr. Sunil M. Eraly<sup>2</sup>  
Dr. Priya R.<sup>3</sup>  
Dr. Renjith Raj<sup>4</sup>  
Dr. Anju N. V.<sup>1</sup>  
Dr. Sajana Rajan<sup>1</sup>

Post Graduate Student<sup>1</sup>  
Department of Conservative Dentistry and Endodontics,  
Malabar Dental College and Research Centre,  
Edappal, Kerala.

Professor and Head<sup>2</sup>  
Department of Conservative Dentistry and Endodontics,  
Malabar Dental College and Research Centre,  
Edappal, Kerala

Professor<sup>3</sup>  
Department of Conservative Dentistry and Endodontics,  
Malabar Dental College and Research Centre,  
Edappal, Kerala

Senior Lecturer<sup>4</sup>  
Department of Conservative Dentistry and Endodontics,  
Malabar Dental College and Research Centre,  
Edappal, Kerala

## Address for correspondence:

Dr. M. A. Shreya  
Amarsamrat, Flat No. 5D  
Pullepady, Kathrikadavu, Cochin  
Contact: +91 8089513261,  
Email: shreyama95@gmail.com

J Ind Dent Assoc Kochi 2019;1(2)2-5.

## INTRODUCTION

Vital pulp therapy is a ministration begun to conserve the tissue that has been compromised by caries, trauma, or restorative procedures<sup>1</sup>. Which aims at stimulation of reparative dentin formation to retain the tooth as a functional unit.<sup>2</sup>

Various materials such as calcium hydroxide, zinc oxide eugenol, calcium phosphate, glass ionomer, resin modified glass ionomers, emdogain, bioglass, biodentine and MTA have been used as pulp capping materials.<sup>3</sup>

MTA after being introduced as a retrograde filling material in 1993 by Torabinejad has gained popularity over other pulp capping materials due to its excellent biocompatibility and in vivo biological performance.<sup>4</sup>

MTA induces dentinogenesis, cementogenesis and hence the pulp heals faster.<sup>5</sup> MTA also has an ability to set in the presence of moisture. Despite several advantages, prolonged setting time, and a need to place wet cotton pellet over MTA to complete the setting reaction is a major drawback that necessitates second visit and increased chair side time.<sup>6</sup>

In order to overcome this drawback a new material MTA Angelus(Angelus, Brazil) with a faster setting time of 15 minutes was used. MTA Angelus contains tricalcium silicate, dicalcium silicate, tricalcium aluminate, calciumsulfate, bismuth oxide.<sup>7</sup>

Since MTA has been commonly used in vital pulp therapy its bond strength to the final restorative material is of prime importance.

Composite Resins and glass ionomer cements (GICs) are very popular in restorative dentistry because of their esthetic and adhesive qualities hence the aim of this study is to compare and evaluate the bond strengths of GIC and composite restorative materials to MTA.

## MATERIALS AND METHODS

### PREPARATION OF MTA SAMPLES

Twenty acrylic blocks with a central cavity of 4mm diameter & 2mm depth were prepared. MTA Angelus powder (Angelus, Brazil) was mixed with distilled water according to manufacturer's instruction and placed into the prepared cavity. The specimens were then randomly divided into 2 groups: GROUP A: GIC and GROUP B: CR.

To standardize the size, GIC and CR were placed over the MTA surface using cylindrical plastic tubes with an internal diameter of 3mm & height 4mm. In GROUP A GIC (GC corporation, Tokyo) was mixed according to the manufacturer's instruction and placed over MTA and allowed to set. In GROUP Bafter etching with 37% phosphoric acid gel, the bonding agent (Adper Single Bond 2 Adhesive, 3M ESPE) was applied & light cured. CR (3M ESPE Filtek Z250 XT) was placed over MTA and light cured for 30 seconds. Plastic tubes were carefully removed after the material was allowed to set. All specimens were stored at 37°C & 100% humidity for 24 hours in an incubator.

### SHEAR BOND STRENGTH MEASUREMENT

The specimens were mounted in a universal testing machine. A crosshead speed of 1 mm/min was applied between the restorative material and MTA using a sharp edged steel rod until the bond between the restorative materials and MTA failed. The peak at which the failure of bond occurred was noted. The shear bond strength in Mega Pascal (MPa) was calculated from the peak bond at failure divided by the specimen surface area. Mean and standard deviations for GIC and composite materials were calculated and compared.

| GROUPS                  | MEAN   | STANDARD DEVIATION |
|-------------------------|--------|--------------------|
| Max Force<br>COMPOSITE  |        |                    |
| GIC                     | 6.7292 | 3.79941            |
|                         | 2.8906 | 2.07397            |
| Max Stress<br>COMPOSITE |        |                    |
| GIC                     | 0.5357 | 0.30250            |
|                         | 0.2301 | 0.16512            |

#### INDEPENDENT SAMPLE t TEST

|                         | t     | df | Sig(2-tailed) |
|-------------------------|-------|----|---------------|
| Max Force               |       |    |               |
| Equal variances assumed | 2.536 | 15 | 0.023         |
| Max Stress              |       |    |               |
| Equal variances assumed | 2.535 | 15 | 0.023         |

## DISCUSSION

According to AAE, pulp cap is defined as a treatment of an exposed vital pulp by sealing the pulpal wound with a dental material such as calcium hydroxide or mineral trioxide aggregate to facilitate the formation of reparative dentin and maintenance of a vital pulp.<sup>8</sup>

Materials recommended for pulp capping such as calcium hydroxide, MTA simulate growth factors and are used in direct pulp capping of carious and non-carious pulp exposures in asymptomatic teeth.<sup>8,9</sup> The growth factor stimulation can lead to dentin regeneration.<sup>10</sup>

The success of pulp cap procedures with MTA is due to the calcium ions from the MTA.<sup>(11)</sup> MTA during its setting reaction has shown to release large numbers of calcium ions, which increases dentin regeneration.<sup>9</sup>

The long term prognosis of pulp capping is based on a well-sealed restoration immediately placed after pulp capping as this will provide protection against microleakage and bacterial contamination that can compromise the success of the pulp cap.<sup>11</sup>

In the present study shear bond strength test was used to evaluate the adhesive properties of MTA with conventional glass ionomer cement and composite resin.

In this study GIC was immediately placed over the MTA surface. The porous surface of MTA could be a factor that increases the strength of the MTA-GIC bond. This was in accordance with a study done by Patil A in 2016 who evaluated the interface between the conventional GIC and resin modified GIC over MTA and concluded that GIC when applied over freshly mixed MTA had minimal effects on the MTA.<sup>12</sup> Possible reactions which may occur

when a GIC is applied on the surface of MTA are: (a) The COO- of the polyacrylic acid could interact with the calcium of the MTA to form calcium salts (b) the silicate hydrate gel of the MTA could condense with the silicate hydrate gel of the GIC to form by-products.<sup>13</sup>

Following pulp capping procedures in areas where esthetics is of concern composite restorations are advocated. The bonding between composite resin and the pulp capping biomaterial hence has an important role in quality of fillings and treatment outcomes.<sup>14</sup>

In this study composite had shown better bond strength with MTA than with GIC. The results of a study by Tyagi et al in 2016 had shown that superior MTA-composite bond strength can be achieved with etch and rinse adhesives in comparison with one-step self-etch systems.<sup>15</sup>

Lee Seok-Ryun et al.<sup>16</sup>, studied the effect of acid-etch procedure on the bond between composite resin and mineral trioxide aggregate. The results showed that acid-etch procedure improved the wettability of MTA surface and the bond strength between MTA and composite resin. The study concluded that acid-etch procedure is essential for a better bond between MTA and composite resin.

Kayhan et al observed that acid etching created surface changes that might have potential to enhance bonding of resinous materials. Phosphoric acid etching significantly enhances the surface energy of the substrate, thereby provides significantly more microretention and potentially increases the bonding effectiveness of resinous materials.<sup>17</sup>

This might be the reason for the superior bond strength of CR with MTA in the present study.



## CONCLUSION

In this study we observed that composite resin showed higher bond strength to MTA when compared to GIC.

Within the limitations of this study we conclude that composite resin (CR) is a preferred restorative material over MTA as compared to GIC.

## REFERENCES

- Ingle, Ingle's endodontics. 6th ed. Hamilton: BC Decker; 2008. p. 1310.
- Quresh A, Soujanya E, Nandakumar, Pratapkumar, Sambashivarao. Recent Advances in Pulp Capping materials: An Overview. JCDR. 2014 Jan; 8(1):316-21.
- Patil A, Kumar T, Bhargava K, Rai Vinay. The evaluation of interfaces between MTA and two types of GIC (conventional and resin modified) under an SEM: An in vitro study. J Conserv Dent 2016 May Jun; 19(3):254-58
- Pariokh M, Torabinejad M. Mineral Trioxide Aggregate: A Comprehensive Literature Review-Part I: Chemical, Physical, and Antibacterial Properties. J Endod 2010; 36(1):16-27.
- Napte BD, Raghavendra SS. Evaluation of Shear Bond Strength of Conventional Glass Ionomer Cements Bonded to Mineral Trioxide Aggregate: An in vitro study. J Dent Allied Sci 2015; 4(2):73-77
- Torabinejad M. Clinical applications of mineral trioxide aggregate. Alpha Omega 2004; 97:23-31
- <https://www.angelusdental.com>
- Aguilar P, Linsuwanont P. Vital pulp therapy in vital permanent teeth with cariously exposed pulp: A systematic review. J Endod 2011; 37:581-7.
- Murray PE, Windsor LJ, Smyth TW, Hafez AA, Cox CF. Analysis of pulpal reactions to restorative procedures, materials, pulp capping, and future therapies. Crit Rev Oral Biol Med 2002; 13:509-20.
- Schmalz G, Galler KM. Tissue injury and pulp regeneration. J Dent Res 2011; 90:828-9
- Keys to clinical success with pulp capping: A Review of the literature. Operative Dentistry 2009.
- Anuradha Patil, Shalini Aggarwal, Tanaya Kumar, Karan Bhargava, Vinay Rai. The evaluation of interfaces between MTA and two types of GIC (conventional and resin modified) under an SEM: An in vitro study 2016 ; 19(3):254-258.
- Asgary S, Parirokh M, Eghbal MJ, Brink F. Chemical differences between white and gray mineral trioxide aggregate. J Endod 2005; 31:101-3.
- Tunc ES, Sonmez IS, Bayrak S, Egilmez T. The evaluation of bond strength of a composite and a compomer to white mineral trioxide aggregate with two different bonding systems. J Endod. 2008; 34:603-5.
- Nimish Tyagi, Chandrakar Chaman, Shashi Prabha Tyagi, Udai Pratap Singh, Apoorv Sharma. The shear bond strength of MTA with three different types of adhesive systems: An in vitro study. 2016. 19(2)130-133.
- Lee Seok Ryun, Moon Young Mi, Hwang Soo Jeong, Seo Min Seock. The effect of acid-etch procedure on the bond between composite resin and mineral trioxide aggregate. Korean Journal of Dental Materials. 2014; 41:53-7.
- Kayahan MB, Nekoofar MH, Kazanda M, Canpolat C, Malkondu O, Kaptan F, et al. Effect of acid-etching procedure on selected physical properties of mineral trioxide aggregate. Int Endod J 2009; 42:1004-14.
- Siavash Savadi Oskee, Mahmoud Bahari, Soodabeh Kimyai, Paria Motahhari, Mohammad Jafar Eghbal, Saeed Asgary. Shear bond strength of Calcium Enriched Mixture Cement and Mineral Trioxide Aggregate to Composite Resin with Two different Adhesive Systems. JDT 2014.



# RISK FACTORS AND TREATMENT MODALITIES FOR MANAGEMENT OF OBSTRUCTIVE SLEEP APNEA

## ABSTRACT

Obstructive sleep apnea is characterized by repeated airway collapse during sleep. Gold standard for diagnosis of OSA is using Polysomnography (PSG). Routine clinical examination of anthropometric and radiographic variables helps to identify the high risk subjects for sleep apnea. Among the sleep medicine team, the role of dentist has become more significant especially in managing the patients with mild to moderate OSA. Treatment method should be based on the severity of the condition, etiology and patient preferences. This review focuses on the risk factors associated with OSA and different treatment methods for managing these patients.

**Key words:** Obstructive sleep apnea, Behavioral modifications, Rapid maxillary expansion.

## Authors:

Dr. Parvathy Ghosh<sup>1</sup>  
Dr. Pillai Devu Radhakrishnan<sup>2</sup>

Assistant Professor<sup>1</sup>  
Department of Orthodontics and  
Dentofacial Orthopedics  
Amrita School of Dentistry  
Amrita Vishwa Vidyapeetham  
Kochi, Kerala

Assistant Professor<sup>2</sup>  
Department of Orthodontics and  
Dentofacial Orthopedics  
Amrita School of Dentistry  
Amrita Vishwa Vidyapeetham  
Kochi, Kerala

## Address for correspondence:

Dr. Parvathy Ghosh  
Assistant Professor  
Department of Orthodontics and  
Dentofacial Orthopedics  
Amrita School of Dentistry  
Amrita Vishwa Vidyapeetham  
Ponekkara,  
Kochi, 682041 Kerala  
Contact: +91 484 2858901, Email:  
parvathyghosh08@gmail.com

J Ind Dent Assoc Kochi 2019;1(2)6-12.

## INTRODUCTION

Obstructive sleep apnea (OSA) is a highly prevalent condition resulting in increased collapsibility of upper airway during sleep, leading to reduced or absolute cessation of airflow. Recurrent periods of complete or limited pharyngeal obstruction causing nocturnal hypoxemia, and excessive daytime sleepiness. Symptoms include snoring, witnessed apnea, excessive daytime sleepiness, morning headache, restless sleep, insomnia, nightmares, irritability, memory loss, decreased attention and concentration, performance deficiencies. OSA thus leads to functional impairment, decreased quality of life and increased risk for road traffic accidents.

According to the International Classification of Sleep Disorders<sup>1</sup>, alternate names include OSA syndrome, sleep apnea, sleep apnea syndrome, obstructive apnea, sleep-disordered breathing (SDB), sleep hypopnea syndrome and upper airway obstruction.

The gold- standard in diagnosing OSA is by polysomnography (PSG)<sup>2</sup>. Severity of OSA is determined by Apnea Hypopnea Index (AHI), which measures the average number of apneas and hypopneas per hour of recorded sleep.

This review focuses on the risk factors associated with OSA, diagnosis and treatment modalities.

### Types of Sleep apnea

The types of sleep apnea are central, obstructive and mixed<sup>3</sup>:

- Central sleep apnea is the condition in which the neural drive to all respiratory muscles are abolished resulting in apnea
- Obstructive sleep apnea is the condition in which there is an occlusion of the oropharyngeal airway for more than ten seconds during sleep
- Mixed sleep apnea is a combination of both component.

OSA can occur at one or more "levels" of the nasopharyngo-tracheal airway<sup>4</sup>.

- Type I disease involves narrowing or collapse of the retropalatal region.

- Type II disease involves narrowing or collapse of both the retropalatal and retrolingual areas.
- Type III disease involves collapse in the retrolingual area (tongue base).

## EPIDEMIOLOGY

OSA is highly prevalent disorder. Many previous population studies conducted globally reported 0.3-5.1% prevalence for OSA. However, these data are predominantly from Caucasian population and so may not be valid to others. A population based study in Delhi, India reported 2.4-4.96 % of prevalence of OSA among men and 1-2% among women<sup>5</sup>. Men are more predisposed to OSA than women<sup>6</sup>. The male-to-female ratio for prevalence of OSA among general population ranges between 2:1 and 4:1.

## RISK FACTORS

Obesity is the main risk factor for the development and progression of OSA and different parameters such as altered body mass index (BMI), neck circumference, waist circumference and waist to hip ratio (WHR) are all considered as risk factors for OSA<sup>7</sup>. However, this relationship appears to be varied by social, environmental and different ethnic backgrounds. Hence, there is an increased attention in identification of the role of these risk factors which leads to sleep disorders so that useful interventions can be used to reduce the obligation of these conditions.

Peppard et al<sup>8</sup> found that 10% increase in body weight caused six times higher risk for developing OSA. Smith et al also have distinctly shown that a high BMI was an important risk factor for OSA, and longitudinal studies have shown that weight loss significantly improves the AHI in obese individuals, suggesting that obesity plays a causative role.

OSA is marked by recurrent collapses of the upper airway during sleep that occur due to reduced airway dilator muscle tone. Obesity may alter the normal upper airway mechanics and contribute to the development of OSA<sup>10</sup>. Fat deposition around neck region can result in change in shape of the upper airway promoting collapsibility<sup>11</sup>. Neck circumference measured

at the level of cricothyroid membrane also forms another parameter for determining obesity<sup>12</sup>. Svensson et al<sup>13</sup> based on a population study showed that increased neck circumference was associated with increased risk of snoring. Central obesity was estimated using waist circumference and waist hip ratio, Suwanprathes et al<sup>14</sup> identified that greater waist circumference increases the risk for developing OSA.

Craniofacial and upper airway morphology is also increasingly accepted as an important interacting factor in OSA pathogenesis<sup>15</sup>. The most frequently reported abnormalities include, a posteriorly placed maxilla and mandible, an enlarged tongue and soft palate, an inferiorly positioned hyoid bone and a reduced velopharyngeal cross-sectional area<sup>16</sup>. In children, enlarged tonsils and adenoids causes abnormal facial growth pattern (adenoid faces) leading to increased risk for developing OSA.<sup>7</sup>

Smoking and alcohol consumption are also possible risk factors for OSA but only few stud-

ies have been reported. Wetter et al<sup>18</sup> showed that smoking causes three times more risk for OSA than non-smokers. Nagayoshi et al<sup>19</sup> also supported that alcohol consumption, and cigarette smoking were positively associated with habitual snoring for both men and women.

Comorbid conditions associated with OSA include hypertension, diabetes, coronary heart disease, congestive heart failure and stroke<sup>20</sup>.

## DIAGNOSIS

Berlin questionnaire helps to predict sleep apnea and has a sensitivity of 86% in the detection of OSA. Excessive Daytime sleepiness is evaluated using Epworth Sleepiness Scale (ESS)(21). This is a simple questionnaire measuring the general level of daytime sleepiness, called the average sleep propensity. This measures the probability of falling asleep in a variety of situations. ESS scores distinguished patients with primary snoring from those with obstructive sleep apnea syndrome (OSAS), and

### EPWORTH SLEEPINESS SCALE

#### Chance of dozing

- 0 - Would never doze
- 1 - Slight chance of dozing
- 2 - Moderate chance of dozing
- 3 - High chance of dozing

#### Situations

- 1. Sitting + Reading
- 2. Watching TV
- 3. Sitting inactive in a public place (eg. Theatre or a meeting)
- 4. As a passenger in a car for an hour without having a break
- 5. Lying down to rest in the afternoon
- 6. Sitting + Talking to someone
- 7. Sitting quietly after lunch when you have had no alcohol
- 8. In car, while stopped in a traffic


Figure 1- Epworth sleepiness scale

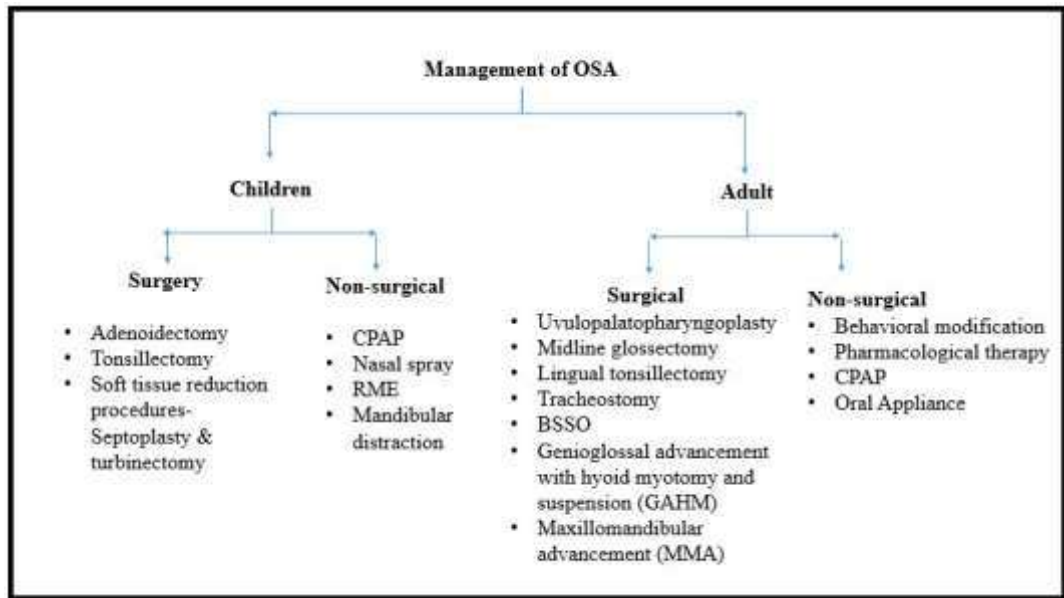


Figure2- flowchart

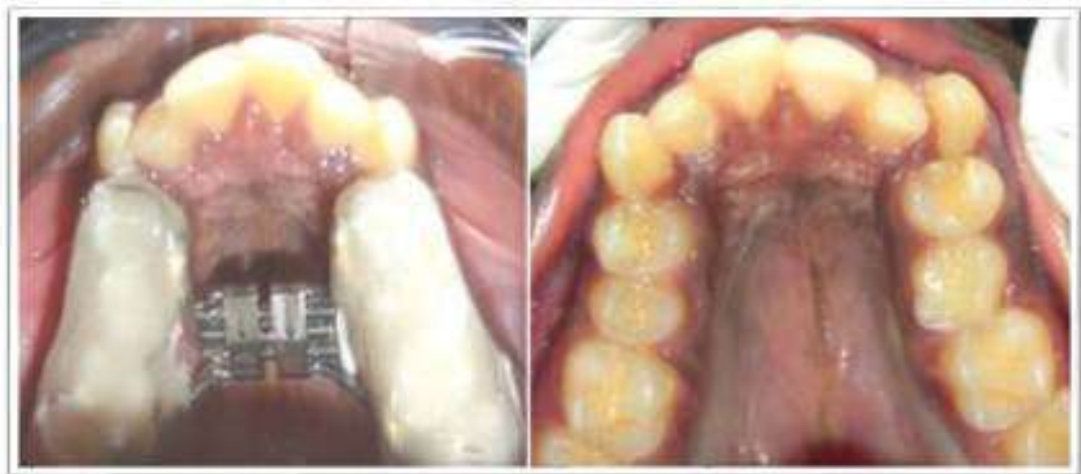

Figure 3-RME - before expansion

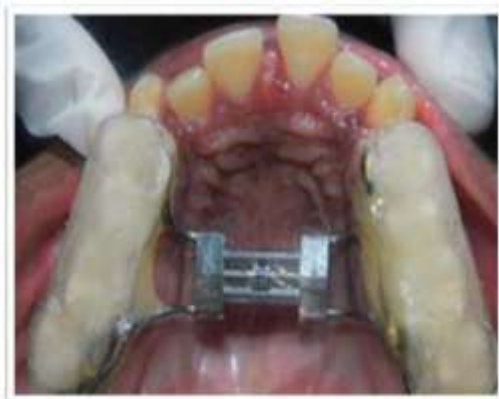

Figure 4- RME- after expansion

ESS scores increased with the severity of OSAS. (fig 1)

The most widely used technique is polysomnography (PSG), which monitors the sleeping state, respiration, electrocardiogram, movements of the legs, oximetry and snoring. In addition, PSG records the distribution of the stages of sleep, the number of awakenings, the number of apneas or hypopneas, the starting time of sleep, and the hours of efficient sleep(hours asleep/hours in bed). PSG also provides the apnea / hypopnea index (AHI)

AHI >30 -severe OSA,

AHI 15-30 - moderate OSA

AHI < 15 - mild OSA

The various anthropometric measurements of obesity, like BMI, waist and neck circumference, can be used as clinical predictors in routine clinical examination for suspecting high risk candidates for OSA. Radiographic examination of upper airway and craniofacial features can be evaluated using lateral cephalograms (2D), computed tomography (CT), cone beam computed tomography, Magnetic resonance imaging (MRI).

Thus during routine clinical examination, these anthropometric as well as radiographic variables help us to identify the high risk subjects for sleep apnea.

## TREATMENT

Based on the severity of sleep apnea, the sleep medicine team describes the different treatment options to patients with OSA. (fig 2) summaries the It includes behavioral modifications, Continuous positive airway pressure (CPAP) and surgical option for moderate to severe OSA cases, Oral Appliance for mild to moderate cases and for patients who are non-compliant to CPAP or refuses surgery.

In children with OSA, Rapid maxillary expansion (RME) is considered as an effective treatment method (fig 3& 4). According to American Academy of Sleep medicine, the PSG diagnosis of OSA in children is defined as apnea hypopnea index  $AHI > 1/h$ . Clinically these patients have long and narrow face, constricted maxilla, enlarged tonsils, narrow upper airway and retrognathic mandible leading to unfavourable facial growth and dental malocclusion. RME helps in the expansion of maxilla by splitting midpalatal suture leading to the correction of posterior crossbite and nasal stenosis<sup>28</sup>. Asok et al showed an improvement in sleep parameters with an increase in sleep efficiency, decreased in arousal and desaturation index after expansion in children<sup>29</sup>.

Among adults,

### A. Behavioural Modification

- Weight loss
- Positional therapy
- Avoid smoking and alcohol

### B. Continuous Positive airway pressure

The ideal treatment of OSA should be capable of reducing excessive daytime sleepiness by normalizing the breathing pattern during sleep. The first line choice of treatment is CPAP. It is often associated with numerous problems like nasal congestion, discomfort secondary to air leak and pressure sensation, mask intolerance, claustrophobia, and issues relating to prolonged use in younger and less severe patients<sup>22</sup>.

### C. Oral Appliance (OA)

In 1990, mandibular advancing oral appliance was the most popular treatment for OSA. Clinically, OA is considered as an effective and low risk alternative for CPAP. According to American Academy of Sleep Medicine (AAOSM), OA is recommended for patients with mild to moderate OSA and also to patients who are intolerant to CPAP and refuses surgery<sup>23</sup>. OA helps to advance the mandible, thus, modifying the posture and their by enlarging the airway leading to reduced upper airway collapsibility.

Numerous designs are available which include

- Mandibular advancing device
- tongue protrusion devices
- tongue repositioning or retaining devices
- soft-palate lifters, tongue trainers
- combination of OA and CPAP(24)

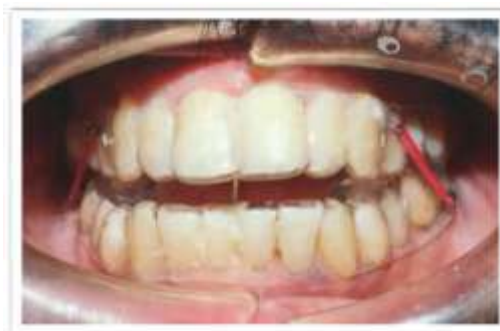

Figure 5- Custom made Oral appliance

Custom made OA (fig 5) are fabricated using thermoplastic material in the vacuum pressure molding device. Posterior bite blocks are made similar to twin block on the upper and lower thermoplastic material. In the lower



incisal lingual area ball end hooks are placed that engages into the acrylic trough in the upper anterior palatal region while closing. Hooks are also placed in the lateral side on to which interarch elastics are engaged which prevents mouth opening during sleep. Various studies have evaluated the efficiency of OA. Cilil et al showed that the custom made OA showed significant improvement in sleep parameters using PSG indicating reduced upper airway collapsibility.<sup>25</sup> Bonham et al also advocated an increase in velopharyngeal area following the use of OA.<sup>26</sup>

#### D. Surgical Method

- Uvulopalatopharyngoplasty
- Midline glossectomy
- Lingual tonsillectomy
- Tracheostomy
- Bilateral sagittal split mandibular ramus osteotomy
- Genioglossal advancement with hyoid myotomy and suspension (GAHM)
- Maxillomandibular advancement (MMA)

MMA increases the retropalatal and retroglossal portion of upper airway, preventing its collapse. MMA advances both maxilla and mandible forward along with its muscle attachments. Prinsell et al suggested 10-15mm advancement of maxilla for lefort I and BSSO mandible with 50% decrease in the AHI index in post-operative patients<sup>27</sup>.

#### CONCLUSION

Undiagnosed OSA represents a major health problem for the public. Disturbed sleep often leads to weakened neurocognitive function, predisposes to motor vehicle and workstation accidents and poor quality of life. Nevertheless, the condition still remains mostly undiagnosed. It is very important to spread alertness not only among the general public but also to physicians of developing countries, regarding the common clinical features, risk factors and different treatment options associated with OSA.

#### REFERENCES

1. American Academy of Sleep Medicine: International Classification of Sleep Disorders: Diagnostic and Coding Manual, ed 2. Westchester, American Academy of Sleep Medicine, 2005, pp 35–77.
2. Health Quality Ontario HQ. Polysomnography in patients with obstructive sleep apnea: an evidence-based analysis Vol. 6, Ontario health technology assessment series 2006. p 1-38
3. Lam JCM, Sharma SK, Lam B. Obstructive sleep apnoea: definitions, epidemiology & natural history. *Indian J Med Res.* 2010 ;131:165–70.
4. Pérez M. Obstructive Sleep Apnea Treatment. *United Healthcare Community Plan Med Policy* 2017;1–25.
5. Reddy E V., Kadiravan T, Mishra HK, Sreenivas V, Handa KK, Sinha S, et al. Prevalence and risk factors of obstructive sleep apnea among middle-aged urban Indians: A community-based study. *Sleep Med.* 2009;10(8):913–8.
6. Lin CM, Davidson TM, Ancoli-Israel S: Gender differences in obstructive sleep apnea and treatment implications. *Sleep Med Rev* 2008;12:481–496.
7. Leong WB, Arora T, Jenkinson D, Thomas A, Punamiya V, Banerjee D, et al. The prevalence and severity of obstructive sleep apnea in severe obesity: The impact of ethnicity. *J Clin Sleep Med.* 2013;9(9):853–8.
8. Peppard PE, Young T, Palta M, et al. Longitudinal study of moderate weight change and sleep-disordered breathing. *JAMA* 2000;284:3015-21.
9. Smith PL, Gold AR, Meyers DA, Haponik EF, Bleecker ER. Weight loss in mildly to moderately obese patients with obstructive sleep apnea. *Ann Intern Med* 1985;103:850–5.
10. Punjabi NM. The epidemiology of adult obstructive sleep apnea. *Proc Am Thorac Soc* 2008;5:136-43.
11. Schwartz AR, Patil SP, Squier S et al. Obesity and upper airway control during sleep. *J Appl Physiol.* 2010;108:430-5.

12. Davies RJ, Stradling JR. The relationship between neck circumference, radiographic pharyngeal anatomy, and the obstructive sleep apnoea syndrome. *Eur Respir J Off J Eur Soc Clin Respir Physiol* 1990;3(5):509-14.
13. Svensson M, Lindberg E, Naessen T, et al. Risk factors associated with snoring in women with special emphasis on body mass index: a population-based study. *Chest* 2006;129:933-41.
14. Suwanprathes P, Won C, Komoltri C, Nana A, Kotchabhakdi N, Guilleminault C: Epidemiology of sleep-related complaints associated with sleep-disordered breathing in Bangkok, Thailand. *Sleep Med.* 2010, 11:1025-1030.
15. Sutherland K, Schwab RJ, Maislin G, Lee RWW, Benediktstsdottir B, Pack AI, et al. Facial phenotyping by quantitative photography reflects craniofacial morphology measured on magnetic resonance imaging in Icelandic sleep apnea patients. *Sleep* 2014;37(5):959-68.
16. Maltais F, Carrier G, Cormier Y, Series F. Cephalometric measurements in snorers, non-snorers, and patients with sleep apnea. *Thorax* 1991;46:419-23.
17. Riley RW, Powell NB, Li KK, et al. Surgery and obstructive sleep apnea: long-term clinical outcomes. *Otolaryngol Head Neck Surg.* 2000;122:415- 421.
18. Wetter DW, Young TB, Bidwell TR, et al. Smoking as a risk factor for sleep-disordered breathing. *Arch Intern Med.* 1994;154:2219-2224.
19. Nagayoshi M, Yamagishi K, Tanigawa T, Sakurai S, Kitamura A, Kiyama M, Imano H, Ohira T, Sato S, Sankai T, Iso H: Risk factors for snoring among Japanese men and women: a community-based cross-sectional study. *Sleep Breath* 2011, 15:63-69.
20. Young T, Peppard PE, Gottlieb DJ. Epidemiology of obstructive sleep apnea. *AmJ Respir Crit Care Med.* 2002;165:1217-1239.
21. M.W. Johns, A new method for measuring daytime sleepiness: the Epworthsleepiness scale, *Sleep* 1991,14 (6): 540-545.
22. Menn SJ, Loube DI, Morgan TD, MitlerMM, Berger JS EM. The mandibular repositioning device:Role in the treatment of OSA. *Sleep* 1996;19:794-800.
23. Practice parameters for the treatment of snoring and obstructive sleep apnea with oral appliances. American Sleep Disorders Association. *Sleep* 1995;18:511-3.
24. M Y. An overview of oral appliances and managing the airway in obstructive sleep apnea. *Semin Orthod* 2009;15:88-93.
25. Cilil VR, Sapna Varma NK, Gopinath S AV. Efficacy of custom made oral appliance for treatment of obstructive sleep apnea. *Contemp Clin Dent* 2015;6(3)341-7.
26. Bonham PE, Currier GF, Orr WC, Othman J, Nanda RS. The effect of a modified functional appliance on obstructive sleep apnea. *Am J Orthod Dentofacial Orthop.* 1988;94:384-92.
27. Prinsell JR. Maxillomandibular advancement surgery in site specific treatment approach for obstructive sleep apnea in 50 consecutive patients. *Chest* 1999;116:1519-29.
28. Pirelli P, Saponara M GC. Rapid maxillary expansion in children with obstructive sleep apnea syndrome. *Sleep* 2004;27:761-6.
29. Navya Ashok, Sapna Varma N. K., Ajith V. V. SG. Effect of rapid maxillary expansion on sleep characteristics in children. *Contemp Clin Dent* 2014;54:89-94.



# SMART MATERIALS IN PEDIATRIC DENTISTRY - A REVIEW

## Authors:

Dr. Malini Venugopal  
Consultant Pedodontist

## Address for correspondence:

Dr. Malini Venugopal  
Consultant Pedodontist  
MMRA 265, Nereveetil Lane  
Moolepadam Road  
Vazhakkala, Kochi 682 030  
Contact: +91 9840228216  
Email: mailtomalu85@gmail.com

## ABSTRACT

Till date there is no single material in dentistry that fulfills all the requirements of an ideal material. Hence there has been continuous search for newer materials which has led to the discovery of smart materials in the field of dentistry. Smart materials are called so as they can be altered in a controlled fashion by different stimulus like temperature, moisture, pH, stress and also with the use of smart materials conservative cavity preparation can be carried out and hence stepping into minimum invasive dentistry. Some of them are biomimetics and can mimic the natural tooth structures such as enamel and dentin. These materials hold a promising future in terms of improved efficiency and reliability and mark the beginning of a new era that is Smart Dentistry. This paper showcases different smart materials and its use to achieve minimum invasive dentistry.

**Key Words:** Smart Composites, Glass Ionomer Cement, Resin Sealant, Ceramic, Impant, Laser

## INTRODUCTION

Traditionally inert or passive materials which have no interaction with their environment were considered ideal for long-term use in the mouth. Materials such as amalgams, composites and cements were considered highly successful because of their ability to survive without interacting with the oral environment.<sup>1</sup> This is actually a different approach to material tolerance and biocompatibility and with smart materials there possibility that some positive gains can be achieved by using materials which behave in a more dynamic fashion in the environment in which they are placed. With increased knowledge of benefit of fluoride release from materials the idea of use of an active rather than passive material came in. This lead to the invention of smart materials. A key feature of smart behaviour includes an ability to return to the original state after the stimulus has been removed.<sup>2</sup>

## CLASSIFICATION OF SMART MATERIALS<sup>3</sup>

- The materials which respond to external change without external control were considered Passive materials They also possess self repairing characteristics.

Ex: Resin-modified glass ionomer, Compomer, Dental composites,

- The materials which sense a change in the environment and respond to these changes were considered Active materials.

Ex: Smart composites, Smart ceramics

### Smart materials

#### SELF REPAIRING /SELF HEALING COMPOSITES

Self-healing composite are inspired by biological system such as bone. After the fracture of the bone, for the bone to heal, nutrients and undifferentiated stem cells must be delivered to the fracture site and sufficient healing time must elapse. In recent research, White et al. have developed a self-healing

polymer. It is first self-healing synthetic material. This was an epoxy system which contain resin filled microcapsule Dicyclopentadiene (DCPD), a highly stable monomer with excellent shelf life, was encapsulated in thin shell made of urea formaldehyde.

If crack occur in epoxy composite material, some of microcapsules rupture and release resin. These resin fills the crack by reacting with Grubbs catalyst in epoxy composite, resulting in opening metathesis polymerization (ROMP) reaction and repair the crack. Different studies showed that dental composites with this technology have a significantly longer duty cycle and enhanced clinical performance. The main problems may occur from the potential toxicity of the resins in the microcapsules and from the catalyst. However, seem to be rather small, and may well be below the toxicity threshold.<sup>4,5</sup>

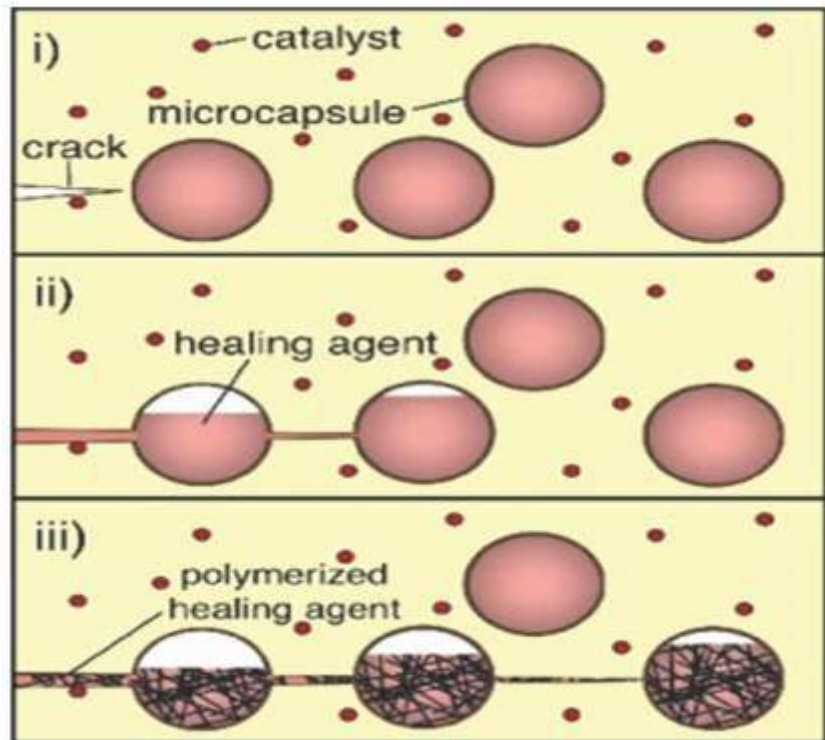
### Smart composites

Smart composites have the property of RELEASE ON COMMAND. They release antimicrobial compounds or fluoride to fight microbes or secondary caries respectively when needed.

Smart composites contain Amorphous Calcium Phosphate (ACP), one of the most soluble of the biologically important calcium phosphates. When pH values falls below 5.8 ACP converts in to hydroxyapatite crystals and precipitates, thus replacing the hydroxyapatite crystals lost to the acid. Within seconds of pH fall below critical value these ions merge to form a gel. In less than 2 minutes, the gel becomes amorphous crystals, resulting in calcium and phosphate ions.<sup>6,7</sup>

### Smart GIC

Glass Ionomer Cements (GIC) have shown a potential thermo-responsive smart behavior .The main advantage of GICs is that it has a coefficient of thermal expansion close to that of dental hard tissues. It was seen that there was not much of dimensional changes in GICs



in terms of heating (expansions) and cooling (contractions) in wet conditions but the materials demonstrated a marked contraction when heated at 50° C in dry conditions.

This action was due to the movement of water in or out of the structures which mimic the behavior of human dentin and indirectly shows the behavior of smart features.

The smart behavior of materials containing GIC is due its salt phases. There is evidence that the fluoride released from salt phases can be replaced when the material is bathed in a high concentration of fluoride. In the long term, the fluoride re-released after recharging may be much more important than the initial 'burst' which is sustained only for a short time.

With the depletion of inherent fluoride there is spikes of fluoride in the 24h period after recharging which was seen to increase slightly with age. This implies that the more inherent fluoride lost the greater capacity for uptake through re-charging. The levels of fluoride release maintained can be increased by beginning the recharging process as soon as possible after setting.

Mahmoud GA et al 2007 concluded that the use of fluoride releasing cements can minimise the

demineralisation around orthodontic brackets and that this effect is not simply dependent upon the extent of the initial fluoride release.

## BIOMIMETIC ENDODONTICS

### Smartseal Obturation System

The main objective endodontics is three-dimensional filling of the instrumented canal, accessory canals, and dead spaces.

The main reason behind the failure of treatment using Gutta-percha was the leakage between sealer and dentin and gutta-percha and sealer and presence of voids. To overcome these problems and improve the treatment outcome, a root canal obturating system called Smartseal™ (known as Prosmart™ outside UK) was developed.<sup>8</sup>

It is hydrophilic endodontic point and an accompanying sealer. It has two components

- 1) propoint
- 2) smart paste/smart paste bio.

They are available in different tip sizes and tapers. The main advantage is the with a single propoint all the tip sizes are covered.

Propoint is called as C points have two parts:

Central Core: Provides the flexibility and hence



very advantageous in case of curved canals.

It is formed by the combination of Trogamid T and TrogamidCX which are two proprietary nylon polymers.

**Outer Polymer Layer:** Polymer acrylonitrile and vinylpyrrolidone has been cross-linked using allyl methacrylate and a thermal initiator. This hydrophilic, hydrogel layer allows the point to swell and adapt the canal wall and expand laterally without expanding axially by absorbing residual water from instrumented canal space and from naturally occurring intraradicular moisture.

The lateral expansion of C Point is claimed to occur nonuniformly, with the expandability depending on the extent to which the hydrophilic polymer is prestressed. Eventhough C Point can achieve a relative good fit of an irregular canal space, gaps may still remain between the walls of the canal and the expanded point hence a sealer must be used to seal those areas.<sup>5</sup>

### Smartpaste Bio

Smartpaste bio is a resin based sealant designed to swell through the addition of ground polymer. The addition of bioceramics, increases the dimensional stability of the sealer exceptionally and makes it non-resorbable inside the root canal.

Smartpaste bio produces calcium hydroxide and hydroxyapatite as byproducts of the

setting reaction, rendering the material both anti-bacterial while setting and very biocompatible once set. The setting time ranges from 4-10 hr and because of the hydrophilic nature, the propoint hydrate and swell to fill any voids.

The sealant is delivered in a pre-mixed syringe and does not require mixing as it can be applied directly into the canal using an intra-canal tip minimising wastage of material. The cement absorbs water from within the canal and once set smartpaste bio produces a radiopaque biocompatible cement. Lesser formation of voids and improved efficiency in lateral canals fillings and homogeneity of obturation made using Smart Seal system comparable over Gutta-percha.

Eidet al. (2013) evaluated the biocompatibility of C Point and commercially available gutta-percha points using a rat odontoblast-like cell line (MDPC-23) by measuring cell viability and mineralization potential of MDPC-23 cells. The study showed that the biocompatibility of C Point is comparable to gutta-percha with minimal adverse effects on osteogenesis after elution of potentially toxic components.

The single cone technique utilizing matched taper Propoint PT combined with Smartpastebio showed the lowest amount of glucose leakage.<sup>5,8,9</sup>

### Smart Ceramics

The first "all ceramic teeth bridge" was

invented at ETH Zurich based on a process that enabled the direct machining of ceramic teeth and bridges. Since then the process and the materials were tested and introduced in the market as CERCON – Smart Ceramics. The strength and technology of Cercon allows bridges to be produced without stainless steel or metal and deliver outstanding aesthetics.

Zirconium oxide (ZrO<sub>2</sub>) is a highly stable ceramic oxide, typically used in industrial applications requiring high strength and stability, and has a history as a biomaterial dating back to the 1970s.

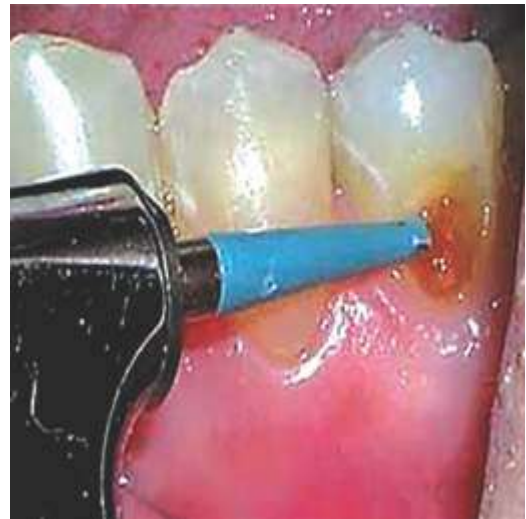Zirconia have significantly high fracture toughness and flexural strength and is much higher than that of alumina or any other currently available all ceramic.

The Cercon system offers a comprehensive solution to these needs by taking advantage of the strength, toughness, reliability, and biocompatibility of zirconium oxide. So the Cercon ceramics are said to be smart material as they are bioresponsive.<sup>10,11,12</sup>

### Smart Prep Burs

These were designed keeping in mind minimally invasive dentistry. They are made of polymers. They cut only the infected dentin and hence keeping the tooth loss to minimal and also the affected dentin which has the ability to remineralize is left intact. Removal of tooth structure is minimal by the use of these smart preparation burs when compared to the conventional burs.

Ex: SS White (145 Towbin Avenue, Lakewood, Newjersey, 08701, USA) diamond and carbide preparation kit.<sup>13</sup>

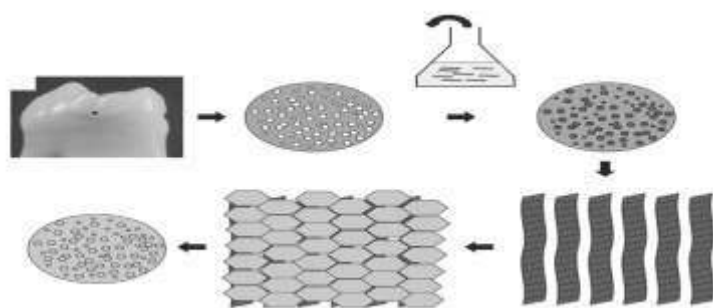


### Smart Sutures

The property that makes these suture materials smart is its shape memory and biodegradable properties. They are thermoplastic polymers. These polymers are broken down in the body hydrolytically to produce lactic acid and glycolic acid. They are applied loosely in its temporary shape and the ends of the suture were fixed. When the temperature is raised above the thermal transition temperature, the suture would shrink and tighten the knot, applying the optimum force. Smart sutures made of plastic or silk threads covered with temperature sensors and micro-heaters can detect infections. Ex: Novel MIT Polymer (Aachen, Germany).<sup>14</sup>

### Biomimetic Self-assembling Peptides:

P11-4 is a rationally-designed self-assembling





peptide. Self-assembling peptides undergo well-characterized hierarchical self-assembly into three-dimensional fibrillar scaffolds in response to specific environmental triggers, offering a new generation of well-defined biopolymers with a range of potential applications.

P11-4 switches from a low viscosity isotropic liquid to an elastomeric pneumatic gel at pH <7.4 and in the presence of cations, conditions assumed to be found within a caries lesion. In a number of in vivo and in vitro experiments, the assembled P11-4 fibers were shown to be highly biocompatible with low immunogenicity. Following P11-4 self-assembly, the anionic groups of other P11-4 side chains would attract Ca<sup>++</sup> ions, inducing de novo precipitation of hydroxyapatite.

White spot is considered to be the first clinical sign of dental caries. At this stage, clinicians generally lesion appearance is monitored and topical fluorides application is done. The case is reviewed to determine whether the lesion will progress or not, in which case restoration would then be placed. Non-surgical intervention promoting defect biomineralization or regeneration at the white spot lesion stage would remove the need to 'wait and see' and avoid the ultimate excavation of the tooth to place a restoration.

Infiltration of early ('white spot') caries lesions using low viscosity monomeric P11-4 would result in triggered self-assembly within the lesion, generating a subsurface bioactive scaffold capable of recapitulating normal histogenesis by inducing mineral deposition in situ.

Peptide treatment significantly increased net mineral gain due to a combined effect of increased mineral gain and inhibition of mineral loss.<sup>14,15</sup>

## Biomimetic Principles In Dental Implant

Biomimetic dental implants may be the next

development in the field. There are various biomimetic coatings that may prove helpful for application in individual patients.

Development of SMART COATING by the researchers at North Carolina State University has proven to be helpful in bonding the surgical implants to the bone more closely thus warding off infection. This has provided with harmless hip, knee, and dental implants.

This coating alleviates the hazard by promoting bone growth into the implant. The coating produces a crystalline layer beside the implant and frequently an amorphous outer layer that touches the surrounding bone. Calcium phosphate hydroxyapatite and various types of aluminum oxides are proved to be bio compatible and they are coated to implant which increases osteointegration.<sup>16,17</sup>

## Smart Fibres For Laser Dentistry

Transmission of high- energy laser pulses capable of ablating dental tissues is a crucial issue in laser dentistry. Flexible and convenient circuits for the delivery of laser radiation are needed to make the solution technologically attractive.

Through Hollow-core Photonic-Fibers (PCFs) high fluency laser radiations are delivered which can easily pass through the body using this Hollow-core Photonic fibres. These photonic fibers are known as SMART FIBRES.

Laser radiation which are transmitted through the Hollow-core PCF are focused upon the surface of a dry carious human tooth (in-vitro) induces an optical breakdown, resulting in plasma formation and dental tissue ablation. The laser breakdown was visualized as optical characterization of the ablated enamel surface. Emission from laser produced plasmas transmitted through the Hollow core PCF in the backward direction and analysed with a Monochromator and a CCD camera. Thus, Photonic Crystal Fibre are not only to transport the high power laser pulse to a tooth surface, but also to transmit plasma emission to the

system for detection and optical diagnosis. While using these fibers we ought to be very careful because there is a risk factor that in some cases the fiber walls fail and the laser light may escape and harm the healthy tissue.<sup>18</sup>

### Smart Toothbrush

This toothbrush offers a multitude of brush-head options for daily brushing and for specific dental considerations (e.g. sensitivity, orthodontics, implants). A red light illuminates at the backside of the toothbrush when pressure exceeds the needed. This red light is visible while brushing to remind the brusher to adjust the pressure applied to the tooth.

The smart toothbrush has inbuilt Bluetooth and various applications with multiple features:

**Timer:** The brushing time can be monitored. The time required for each quadrant is shown and reminds the user to brush longer if the set time is not reached. Longer brushing time can also be set. Various instructional videos about proper usage of the brush is included. While brushing, the user can focus on the diagram of the section of the mouth to be brushed or read a newsfeed or oral care tips. These features encourage longer brushing times

**Professional Guidance:** The user's dental professional can set up Focused Care. Focused Care reminds the user to focus on a specific area in the mouth. The user may be reminded to spend more time brushing in a specific area, and the dental professional can add notes to further educate the patient. Product recommendations and appointment reminders can be set here.

**Activity:** This portion of the app is a report of the user's history of brushing times and frequency.

**Dental Care Journeys:** This section of the app guides the user to a desired outcome with proper brushing, flossing, rinsing, and tongue-brushing habits.

**Achievements:** This portion of the app encourages the user to develop optimal brushing habits by recording the user's personal bests.<sup>19,20</sup>

### CONCLUSION

Our field of dentistry is completely dependent on the use of different materials, the use of smart materials promises improved reliability and long-term efficiency because of their potential to select and execute specific functions intelligently in response to various local changes in the environment, thereby significantly improving the quality of dental treatment. The numerous applications of smart materials have revolutionized many areas of dentistry and there is no doubt that "smart materials" hold a real good promise for the future.

### REFERENCES

1. JF McCabe, Z Yan, OT Al Naimi, G Mahmoud, SL Rolland. Smart materials in dentistry. Australian Dental Journal 2011;56:(1 Suppl): 3–10.
2. Mangaiyarkarasi S P, Manigandan T, Sivagami S, Rajendran Vijayakumar, Nagarjuna Chowdary. Biosmart Dentistry. Annals and Essences of Dentistry 2013;4: 34-38.
3. Gupta V. Smart materials in dentistry: A review. International Journal of Advance Research and Development. 2018;3:89-96.
4. Shanthi.E, Soma Sekhar.V, Ankireddy.S Smart materials in dentistry: Think smart Journal of Pediatric Dentistry 2014; 2 (1):1-4.
5. Baig .RA, Navid Ali. S, Saoji.H . Smart seal: Unique obturation system in dentistry International Journal of Applied Dental Sciences 2016; 2(1): 01-02.
6. Purva. S, Mantri V, Palekar A, Syed G.A Smart composite: a review article.2016. njdsr; 1( 4):57-62.



7. Magne.P.Composite Resins and Bonded Porcelain: The Postamalgam Era? CDA.JOURNAL2006;34(2):136-7.
8. Economides, N., Gogos, C., Kodonas, K., Beltes, C., &Kolokouris, I. (2012). An ex vivo comparison of the push-out bond strength of a new endodontic filling system (Smartseal) and various gutta-percha filling techniques. *Odontology*, 100(2), 187-191.
9. Kottoor J. Biomimetic Endodontics. Barriers and Strategies'. *Health Sciences* 2013; 2(1).
10. Gautam P, ValiathanA.Bio-smart dentistry:Trends Biomater2008; 21(2):94-7
11. J.R. Kelly and I. Denry, Stabilized zirconia as a structural ceramic: an overview, *Dental Materials* 2008;24:289–298
12. 15. J.R. Kelly and P. Benetti, Ceramic materials in dentistry: historical evolution and current practice, *Australian Dental Journal* 2011;56:84–96
13. Dammaschke T, Schafer E. Efficiency of the polymer bur smart prep compared with conventional carbide bud bur in dentin caries excavation. *Operative Dentistry*.2006; 31(2): 256-60
14. Smart dental materials: a review of the current literature. Dr.Riyas Ahamed K ,Dr.Prathap M.S and Dr. K Harish S Shetty.
15. Brunton P A, Davies R ,Burke. Treatment of early caries lesions using biomimetic self-assembling peptides – a clinical safety trial. *British dental journal* 2013; 215:1-6.
16. Junker.R, Dimakis.A. Effects of implant surface coatings and composition on bone integration: a systematic review. *Clinical oral implants research* 2009;20(4):185-206.
17. Lin.X , De Groot.K, Wang Q. Hu. A Review Paper on Biomimetic Calcium Phosphate Coatings .*The Open Biomedical Engineering Journal* 2015; 9: 56-64.
18. Konorov SO, Mitrokhin VP, Fedotov AB, BiryukovDAS et al. Hollow-core photonic-crystal fibers for laser dentistry. *PhysMed. Biol.* 2004; 49(7): 1359-1368.
19. Kim KS, Yoon TH, Lee JW, Kim DJ. Interactive toothbrushing education by a smart toothbrush system via 3D visualization. *Computer methods and programs in biomedicine*. 2009 Nov 1;96(2):125-32.
20. Lee JW, Lee KH, Kim KS, Kim DJ, Kim K. Development of smart toothbrush monitoring system for ubiquitous healthcare. In2006 International Conference of the IEEE Engineering in Medicine and Biology Society 2006 Sep (pp. 6422-6425). IEEE.

# DENTAL MIMICRY - AN EMERGING CONCEPT IN DENTAL THERAPY

## Authors:

Dr. Vinutha Manjunath<sup>1</sup>

Dr. Natasha Habib<sup>2</sup>

Reader<sup>1</sup>

Department of Conservative Dentistry  
and Endodontics  
JSS Academy of Higher Education  
and Research  
JSS Dental College and Hospital,  
Mysuru, Karnataka

Post Graduate Student<sup>2</sup>

Department of Conservative Dentistry  
and Endodontics  
JSS Academy of Higher Education  
and Research  
JSS Dental College and Hospital,  
Mysuru, Karnatak

## Address for correspondence:

Dr. Natasha Habib  
Hyder Dental Speciality Centre  
No. 26, HUDCO Main Road  
Bannimantap, Mysuru, 570015,  
Karnataka  
Contact: +91 8329807387  
Email: tashv20@gmail.com

## ABSTRACT

The requirements of dental materials have changed over time with the evolution of bioactivity and biomimicry. The newer materials possess bioactive and biomimetic properties and have varied applications in literally every field of dentistry today. The tooth constitutes of enamel, dentin-pulp complex, cementum and the surrounding periodontal ligament and bone and these can be mimicked via the bioactive and biomimetic approaches. Bioactive/ biomimicking materials are an interactive approach to restoring teeth. This article summarizes these restorative materials

**Keywords:** Biomimetic materials, biomimicry, bioactive materials, bioactivity

## INTRODUCTION

Fundamental requirements of dental materials have changed over time with the evolution of bioactivity and biomimicry. Earlier, a material was considered to be ideal if it exhibited bioinert properties. This concept has undergone a huge metamorphosis over the years.

In the light of current technology, a dental material should ideally be

- Biocompatible.
- Bioactive.
- Biomimetic.
- Moisture tolerant.
- Stable.
- Possess good physical properties .
- Inexpensive.

Most of the materials used in dentistry have bioactive properties which help them give rise to a structure that closely resembles a tooth; thereby mimicking natural dentition. Hence, it can be stated that all materials exhibiting bioactivity are biomimetic in nature, but not all biomimetic materials possess bioactive properties.

## TERMINOLOGIES/ DEFINITION

### Osteoinduction

is the process by which osteogenesis is induced. It means that primitive, undifferentiated and pluripotent cells are somehow stimulated to develop into bone forming cell lineage.<sup>1</sup>

### Osteoconduction

It means that the bone grows on a surface. Wilson-Hench has suggested that it is a process by which bone is directed so as to conform to a material's surface.<sup>1</sup>

### Bioactive Material

A bioactive material is one that elicits a specific biological response at the interface of the material which results in the formation of a bond between the tissues and the material

Biomimetics can be defined as the study of the structure, formation, and function of biologically produced materials and also

mechanisms and processes especially for the purpose of synthesizing similar products by artificial mechanisms which imitate/mimic natural ones. Biomimetics is the field of science that uses the natural system of synthesizing materials through biomimicry.

Biomimetic Material is the material formed by biomimetic technique based on the natural process. The material should be in some way reproducing one or more natural phenomenon within a biological situation

Biomimetic Dentistry is the biomimetic reproduction of the original performance of the intact tooth that is about to be restored

- Magne et al

It is the use of dental materials and technologies that mimic tooth structure and function and help maintain as much natural tooth structure as possible<sup>2,3,4,5</sup>.

## BIOMIMETICS IN DENTISTRY

When restoring damaged, broken and decayed teeth, the goal is to attain full structure and function of the damaged tooth. Unfortunately, there is no such biomaterial that has the same mechanical, physical and optical properties as that of tooth structure. The aim is to mimic materials that will have aesthetic and functional properties closer to that of tooth structure

### Goal

To return the tooth to its form, function, aesthetics and strength

This method can be widely used in dentistry for replacement of lost dental tissues and for regeneration of dental structures. Bioactive/ biomimicking materials are an interactive approach to restoring teeth. These materials have diverse applications, both in the field of conservative dentistry and endodontics

## CONSERVATIVE DENTISTRY APPLICATIONS

### For Restoration

- a. As Enamel and Dentin substitutes

For Replacement

#### Direct Restorative Materials

- GIC
- Calcium Aluminate GIC/Ceramir
- Glass Carbomer
- Hainomers
- Resin Based Composites
  - Smart Composites
  - ACTIVA BioActive
  - ACP filled Composites
  - Giomer

#### Indirect Restorative Materials

- Ceramic
- Indirect Composites

#### For Regeneration

- MTA
- CaOH
- Biodentine

#### b) As Cementum/ Bone substitutes

For Replacement

- Glass Ionomer
- Composites

For Regeneration

- Calcium sulphate
- Calcium phosphate
- BMP
- BioActive Glass

### ENDODONTIC APPLICATIONS

#### a. For Root filling

Obturator material

- Core material
- Bioceramic coated GP point
- C points
- ActiV GP
- Sealers
- Bioceramic sealers
- CaOH sealers
- MTA based sealers

#### b) For Repair and Root end filling

- MTA
- Biodentine

- Bioceramics
- Calcium phosphate

#### c) For Regeneration

- BMP2, BMP4
- Stem Cells from human exfoliated deciduous teeth (SHED)
- Dental pulp stem cells (DPSCs)
- Stems cells from apical papilla (SCAP)
- Hydrogels
- Plasmids, peptides, DNA-ligand complex
- PRP's

### IMPLANT APPLICATIONS

- Bioactive Coated Implants<sup>6</sup>

### GLASS IONOMER CEMENTS

They play a "bioactive" role due to the following properties

- Chemical bond to enamel and dentin
- Fluoride releasing property

### Adhesion

GIC bonds chemically to tooth structure

- The adhesive mechanism of GIC primarily involves chelation of carboxyl groups of the polyacids with the calcium in the hydroxyapatite of the enamel and dentin.
- Resulting in the formation of the interfacial calcium polyalkenoate salt bridges between the cement and the tooth.

### Fluoride release

Fluoride ions in the set glass ionomer replace the hydroxyl ions of enamel hydroxyapatite (HA) crystals resulting in fluorapatite crystals<sup>7,8,9</sup>.

Fluoride ion release is known to stimulate apatite deposition in bone as well as osteoblast mitosis<sup>9</sup>. Thus making the tooth more resistant to demineralization and promoting remineralization.

### Properties of GIC similar to tooth structure

Coefficient of Thermal expansion

Very close to that of tooth structure

|        | CTE in $\times 10^{-6}/^{\circ}\text{C}$ |
|--------|--|
| Enamel | 11.4                                     |
| Dentin | 8.3                                      |
| GIC II | 11                                       |

- Modulus of elasticity ( $10.4 \pm 1.3$  GPa)  
Similar to dentin (18.3 GPa)
- Thermal diffusivity/Thermal conductivity  
Close to that of tooth structure  
Protects the pulp from thermal trauma

| Type of material          | Thermal diffusivity ( $\times 10^{-6} \text{mm}^2/\text{sec}$ ) |
|---------------------------|---|
| Dentin                    | 0.18  |
| Type I GIC (luting)       | 0.15  |
| Type II GIC (restorative) | 0.19  |

## RESIN BASED GLASS IONOMER

Fluoride release levels are comparable to those of conventional.<sup>9</sup>

## CALCIUM ALUMINATE GIC/ CERAMIR

The most recent modification in bioactive chemically bonded dental cements is calcium aluminate-glass ionomer luting cement (CM Crown and Bridge, originally named XeraGem)

The luting agent is intended for permanent cementation of crowns and fixed partial dentures, gold inlays and onlays, prefabricated metal and cast dowel and cores, and high strength all zirconia and all-alumina crowns.

<sup>10,11,12</sup>

## CPP-ACP CONTAINING GIC

Incorporation of 1.56% casein phosphopeptide-

amorphous calcium phosphate into a glass-ionomer cement. CPP-ACP has synergistic remineralization potential and enhances the release of calcium, phosphate and fluoride ions

E.g.: Fuji VII TMEP

## HYDROXYAPATITE CONTAINING GIC

- Nano Bio Ceramic modified GIC

Nano hydroxyapatite / fluorapatite particles added to conventional GIC

Superior bonding to tooth surface (formation of linkage between HA and  $\text{Ca}^{+2}$  in tooth)

- Hainomers

These are newer bioactive materials developed by incorporating hydroxyapatite within glass ionomer powder. They have fluoride releasing properties. Promising future during clinical trials as a retrograde filling material. Studies have shown that they have a role in bonding directly to bone and supports its growth and development, biomineralization.<sup>8</sup>

- Glass Carbomer

A novel commercial material of the glass ionomer type, which has enhanced bioactivity compared with conventional glass ionomer cement.<sup>13</sup> The matrix is same as the conventional glass ionomer, the only difference being that glass carbomer constitutes polydimethylsiloxane oil and a bioactive component (hydroxyapatite)

## RESIN BASED COMPOSITES

- Ability to mimic the natural tooth in appearance
- acceptable level of biocompatibility
- added advantage of fluoride release comparable to glass ionomers hence bioactive

Table 2: Mean Fluoride Release ( $\mu\text{g}/\text{dl}/\text{mm}^2$ ) During the First Week

| Group           | Day 1             | Day 2            | Day 3            | Day 4            | Day 5            | Day 6            | Day 7            |
|-----------------|-------------------|------------------|------------------|------------------|------------------|------------------|------------------|
| GIC             | $11.5 \pm 1.70^a$ | $7.7 \pm 0.07^a$ | $6.6 \pm 0.21^a$ | $6.3 \pm 0.05^a$ | $4.5 \pm 0.09^a$ | $3.1 \pm 0.06^a$ | $1.5 \pm 0.21^a$ |
| RMGIC           | $7.2 \pm 0.62^b$  | $5.8 \pm 0.06^b$ | $6.1 \pm 0.06^b$ | $7.1 \pm 0.12^b$ | $7.1 \pm 0.09^b$ | $5.1 \pm 0.24^b$ | $2.1 \pm 0.12^b$ |
| Nano-ionomer    | $7.9 \pm 0.11^b$  | $6.7 \pm 0.23^b$ | $6.6 \pm 0.08^b$ | $7.3 \pm 0.19^b$ | $7.6 \pm 0.07^b$ | $5.4 \pm 0.18^b$ | $2.9 \pm 0.15^b$ |
| Compomer        | $4.2 \pm 0.21^c$  | $2.1 \pm 0.04^c$ | $2.5 \pm 0.10^c$ | $2.4 \pm 0.19^c$ | $1.8 \pm 0.08^c$ | $1.5 \pm 0.09^c$ | $1.5 \pm 0.08^c$ |
| Resin Composite | $1.5 \pm 0.08^d$  | $1.1 \pm 0.06^d$ | $0.9 \pm 0.06^d$ | $0.9 \pm 0.12^d$ | $1.0 \pm 0.11^d$ | $0.9 \pm 0.10^d$ | $0.7 \pm 0.11^d$ |

<sup>a</sup>Different letters (for each day) imply significantly different groups ( $p < 0.05$ ).

They include

- Smart Composites<sup>14</sup>
- ActivaBioACTIVE
- ACP-filled composites
- Giomer
- Cention N
- Compomer

### ActivaBioACTIVE

First dental resins with a bioactive ionic resin matrix, shock absorbing rubberized resin component, and reactive ionomer glass fillers that mimic the physical and chemical properties of natural teeth

Actively participate in the cycles of ionic exchange that regulate the natural chemistry of our teeth and saliva and contribute to the maintenance of tooth structure and oral health.

### ACP-filled Composites

Inclusion of amorphous calcium phosphate into composite resins results in release of Ca and PO<sub>4</sub> ions for an extended period of time and remineralizes the demineralized dentin<sup>14</sup>.

### Giomer

Giomer utilizes the hybridization of GIC and composite by using a unique technology called the pre-reacted glass ionomer technology (Pre reacted glass is mixed with the resin) [15]

Depending on the amount of glass which is reacted,

F- PRG = fully pre reacted

S- PRG = Surface pre reacted

Eg. Beautiful II, Fl Bond II

### Fluoride release

Study by Itota et al. has shown that the amount of total and free fluoride release from Giomer was higher than Compomer and resin composite.

Also it has been shown that Gomers and

compomers do have the initial fluoride burst effect of the glass ionomer cements.<sup>15</sup>

### Fluoride recharge

Preston and Han reported that the ability of a material to exhibit fluoride recharge depends on its ability to retain fluoride. From previous studies, it was reported that the fluoride release and recharge was maximum for Giomer products when compared to Glass ionomer and its derivatives.

### Cention N

It is a tooth coloured direct aesthetic resin based restorative material. It is a subgroup of composites named alkasites. The material has high flexural strength and fluoride releasing properties. The patented alkaline filler increases the release of hydroxide ions and regulates the pH value during acid attacks. Hence preventing demineralization

### Compomer

They are poly acid modified composites have a resin matrix of dimethacrylate monomer with carboxylic group and partially silanised ion leachable glass fillers.

E.g.: Dyract, Compoglass, F2000

Release of fluoride: less than 10% of the release of glass ionomers

### CALCIUM HYDROXIDE

Calcium hydroxide has good biological properties such as an antibacterial effect, and the capacity to reduce osteoclastic activity and promote mineral tissue formation. Its basic pH (close to 12) is due to the liberation of hydroxyl ions and is responsible for its biological properties.

### Mode of Action

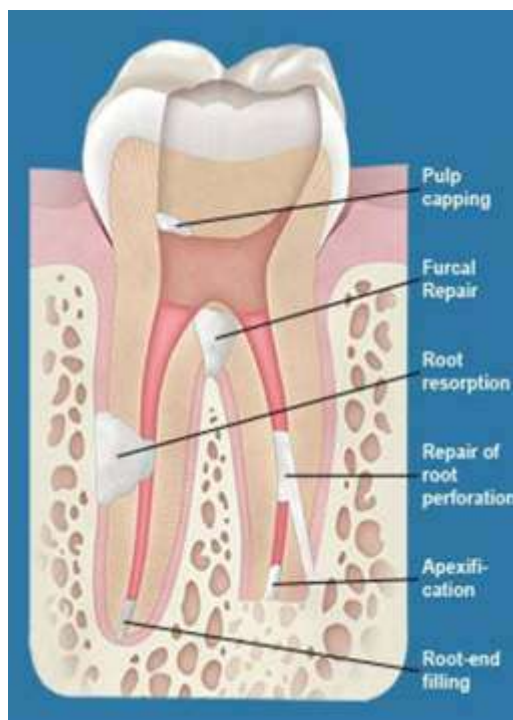
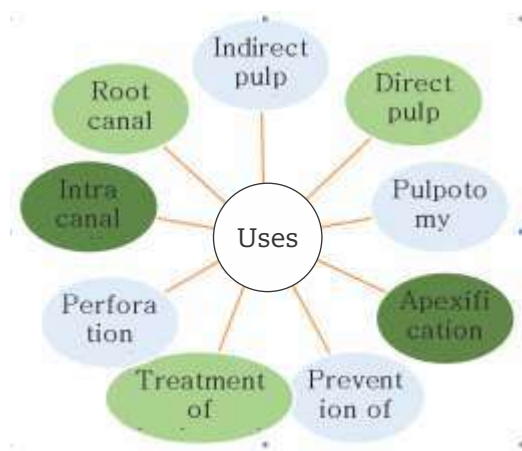#### Mineralization activity

- Calcium hydroxide has the unique potential to induce mineralization, even in tissues which have not been programmed to mineralize



- It activates alkaline phosphatase activity which is postulated to play an important role in the hard tissue formation
- Also, a mineralized barrier or dentin bridge is usually produced following its application to a vital pulp
- Placed in direct contact with connective tissue, it promotes the formation of a cementoid barrier.
- MTA undergoes hydrolysis and produce calcium silicate hydrate (C-S-H) and calcium hydroxide.
- Set MTA can be described as calcium hydroxide contained within a silicate matrix.

## Applications



## PORTLAND CEMENT

Hydraulic cement containing primarily calcium silicate derivatives (tricalcium and Dicalcium silicates) with decreasing proportions of tricalcium aluminate and Tetracalciumaluminoferrite. Used as a root end filling material

### Mineral Trioxide Aggregate

- Developed by Dr. Mahmoud Torabinejad.
- MTA is a derivative of the ordinary Portland cement with 4:1 proportions of bismuth oxide added for radiopacity. Portland cement is the active ingredient in white MTA.
- Facilitates the regeneration of cementum and PDL.

### Setting Reaction

On hydration calcium silicates present in

### Interaction of MTA with dentin and pulp

Leads to early dentin formation when used as a pulp capping agent

- After placement into the root canals, and its gradual dissolution, hydroxyapatite crystals nucleate and grow, filling the microscopic space between MTA and the dentinal wall

### Interaction of MTA with Peri radicular tissues

The cellular response to MTA is important for repair and regeneration of peri radicular tissues. MTA induces osteogenic phenotype in PDL fibroblasts, with induction of alkaline phosphatase activity as well as production of osteopontin and osteonectin.



## BIODENTINE

Developed by Septodont's Research Group  
Made up of tri-calcium and di-calcium silicates with calcium chloride as an accelerator

Suitable as a dentin replacement material whenever original dentin is damaged, hence termed as Biomimetic

### Properties

- Compressive strength: 300 MPa after 1 month (Dentin 297 Mpa)
- Good marginal integrity (ability to form hydroxyapatite crystals at the surface)
- Highly biocompatible

### Bioactive properties

- Induces mineralised foci formation early after its application
- The mineralization is in the form of osteodentin and expresses markers of odontoblasts
- It significantly increases TGF-  $\beta$ 1 secretion from pulp cells
- Hence induces an early form of reparative dentin synthesis
- It increases OD-21 cell proliferation and

biomineralization

- Can be used for dentin-pulp complex regeneration

### Clinical applications

- Ultimate Dentinal Substitute

## CERAMICS

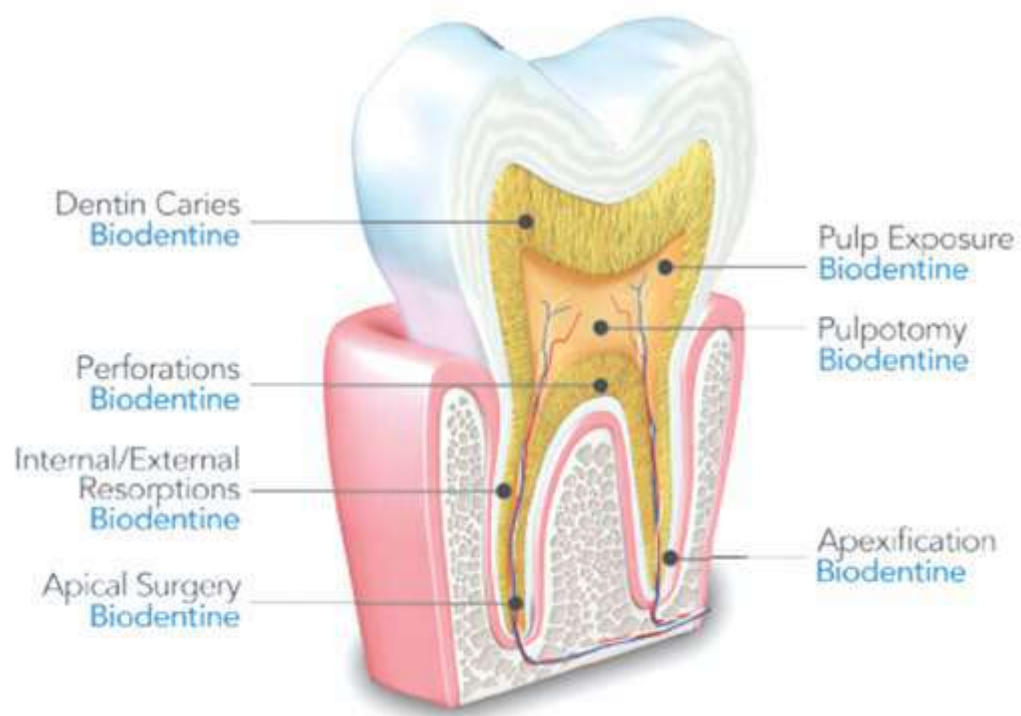
Dental material commonly used for replacement of lost tooth structures (crowns, bridges, veneer fabrication) [17]

### Biomimetic

- Unmatched Aesthetics
- Excellent biocompatibility
- Good strength
- Chemical stability in oral environment

## CALCIUM PHOSPHATE

Calcium phosphates are minerals composed of calcium cations and phosphorus anions and make up for 60% of human bones.[18] Since the 1990's, synthetic calcium phosphate have been used for bone regenerative applications such as bone cements, scaffolds and in an injectable form as a bone substitute.[19] Calcium



|                             | Compressive Strength<br>Mpa | Modulus of Elasticity<br>Gpa |
|-----------------------------|-----------------------------|------------------------------|
| Enamel                      | 384                         | 83.4-105.2                   |
| Lithium disilicate ceramics | 450-500                     | 82.3                         |
| Zirconia based ceramics     | around 2000                 | 205                          |
| Feldspathic ceramics        | 149                         | 69                           |

phosphate, an osteoconductive material has unique bioactive properties and bone regeneration effectiveness by allowing colonization of either bone or the dental pulp implantation site by osseous cells such as osteocytes and osteoblasts. It is also used in endodontic therapy as a scaffold for inducing mineralised tissue formation<sup>19</sup>.

### CALCIUM SULPHATE

- Introduced into periodontology and implantology and endodontics for the treatment of bone lesions
- A thick apatite layer is formed over the surface of calcium sulphate, indicating the high bioactivity of this material
- Induces first intention bone regeneration and facilitates migration and adhesion of gingival fibroblasts<sup>20</sup>.
- It is an outstanding bone substitute ensuring bone formation and giving results comparable with autogenous bone<sup>20</sup>.

### BONE MORPHOGENIC PROTEINS

Discovered by Marshall Urist in 1964

There are at least 20 BMP like molecules. The important ones being

- BMP 2,4- Stimulate differentiation of attached cells into odontoblasts, formation of dentin-pulp complex
- BMP 3- Induce cartilage formation
- BMP 5,6,7- Augment the capacity of BMP 2
- Clinical application: Direct Pulp Capping (BMP 7), Pulpotomy, Guided bone regeneration, Furcation repair.

### BIOACTIVE GLASS

- BAG's first introduced by Hench et al are surface active glasses that bond chemically to tooth structure
- They are 100% synthetic bone restorative and regenerative materials
- They Used as bone substitutes - promote osteogenesis
- Two commercially available glasses:
  - Bioglass (300-355µm)
  - Perioglass (90-710µm)

### CORE MATERIALS FOR OBTURATION

A 3-dimensional filling of the root canal is the key to a successful endodontic treatment as it provides a fluid tight seal and prevents residual bacteria and their toxins from affecting the periapical tissues<sup>21, 22</sup>. In order to improve the marginal sealing properties of the root canal system, hydrophilic root canal obturating systems have been introduced.<sup>23</sup> They consist of hydrophilic sealers and hydrophilic substance coated core materials, which reduce the number of interfaces and improve bonding<sup>23</sup>.

These sealers bond to the dentinal walls as well as the hydrophilic core materials thereby creating a gap free single-cone sealer-based obturation technique with better seal and reduced microleakage<sup>24</sup>.

The recent obturating systems are

- ActiV GP Precision Obturating System (Brasseler USA) consists of an ActiV GP point with a 2µm coating of GI particles on its surface and GI-based sealer<sup>25</sup>.

- Endosequence (Brasseler USA) which consists of bio ceramic coated GP points and bio ceramic BC sealer.
- Smart-Seal System (Prosmart-UK) which is composed of C-Points (active polymer coated) and Smart-paste Bio-sealer.<sup>22,23</sup>

## COATED IMPLANTS

Surface modification of titanium and its alloys have been proposed from the view point of improving bioactivity. The technique involves coating of titanium implants with bioactive materials such as calcium phosphates like hydroxyapatite, polyether ether ketone and Nano diamonds. The most common being, coating with hydroxyapatite, an osteo conductive compound<sup>26,27</sup>.

Hydroxyapatite ( $\text{Ca}_{10}(\text{PO}_4)_6(\text{OH})_2$ , HA) has been used for many years as a bioactive implant coating to improve osseointegration. It has a large capacity for adsorbing proteins, improves osteoblast proliferation, enhances bone formation and reduces bone loss. These properties induce a more rapid fixation and stronger bonding between the host bone and the implant, and are conducive to uniform bone ingrowth at the bone-implant interface.

The most common method of applying the hydroxyapatite coating onto endosseous implants is the plasma spraying technique<sup>26,27</sup>.

## PLATELET RICH PLASMA (PRP)

Regenerative endodontic procedures (REP's) are a feasible option for the repair of periapical tissues in teeth with open apex and in non surgical endodontic retreatment

In REPs, a matrix is necessary to provide a physicochemical and biological microenvironment that supports the growth, migration, and differentiation of dental stem cells.

PRP's can be used as a matrix for REPs as

- It is versatile
- Easy to prepare
- Stable
- It is both inductive and conductive

## Conduction

The PRP matrix helps for the placement of MTA

## Induction

Supplies growth factors and bioactive molecules like transforming growth factor beta, bone morphogenic proteins, insulin like growth factors, and angiogenetic growth factors, which stimulate collagen production, angiogenesis, and cell differentiation.<sup>28</sup>

Anti-inflammatory and antibacterial properties have also been reported for this preparation, which are involved in all processes of repair.

## BIOMIMETIC/ BIOACTIVE APPROACHES FOR REGENERATION

### • Pulp implantation

Generation of pulp tissue is possible in laboratory by tissue engineering using DPSCs, dentin matrix protein I, and an injectable collagen hydrogel scaffold which has shown to induce an organized matrix similar to pulp tissue which may lead to hard tissue formation.<sup>30</sup>

### • Gene Therapy

It is a method of delivering genes with viral vectors like adenovirus, retrovirus, lentivirus, and Herpes simplex virus or nonviral vectors like plasmids, peptides, cationic liposomes, DNA-ligand complex, gene guns, electroporation.

The gene delivery system in endodontics aims to deliver mineralizing genes into pulp tissue to induce mineralization<sup>30</sup>

## Stem Cell Therapy

Stem cell therapy involves administering cells of definite regenerative potential into the disinfected root canal system. The most commonly used stem cells in regenerative endodontics are stem cells from human exfoliated deciduous teeth (SHED), dental pulp stem cells (DPSCs), and stem cells from the apical papilla (SCAP). These cells are able to regenerate dentin-pulp complex like natural human tooth.<sup>30</sup>

## CONCLUSION

The concept of biomimetics has increased the scope of dentistry to a great extent.

Further, Bioactivity has facilitated regeneration of the lost dental tissue rather than replacement which is a paradigm shift in tissue restoration concept thus ensuring better prognosis, excellent biocompatibility through a minimal invasive approach.

## REFERENCES

1. Albrektsson et al. Osteoinduction, Osteoconduction and osteointegration. *Eur Spine J*, 2001; 10:S96-101.
2. Afzal Ali et al. Biomimetic Materials in Dentistry, Research and Reviews. *Journal of Material Sciences*, August 2017; 5(4), 1-8.
3. Vishal Mahajan et al. Biomimetic Materials in Dentistry: An Overview. *IOSR Journal of Dental and Material Sciences*, November 2016; 15(11), 127-30.
4. Deepak et al. Biomimetics in Dentistry - a review. *Indian Journal Of Research in Pharmacy and Biotechnology*, 2014; 2(5):1384-88.
5. Steven et al. Bioactive and Biomimetic Restorative Materials: A comprehensive Review, Part 1. *Journal of Aesthetic and Restorative Dentistry*, 2014; 26(1): 14-26.
6. Magdalena Łukaszewska-Kuska et al. Hydroxyapatite coating on titanium endosseous implants for improved osseointegration: Physical and chemical considerations. *Advances in Clinical and Experimental Medicine*, 2018; 27(8): 1-6.
7. Srikumar GPV et al. Newer Advances in Glass Ionomer Cement: A Review. *Annals and Essences of Dentistry*, 2016; 8(4): 19-23.
8. Nagaraja et al. Glass Ionomer Cement - The different generations. *Trends Biomater. Artif. Organs*, 2005; 18(2), 158-65.
9. Neelakantan et al. Fluoride Release from a New Glass-ionomer Cement. *Operative Dentistry*, 2011; 36(1): 80-5.
10. Steven et al. Bioactive and Biomimetic Restorative Materials: A comprehensive Review, Part II. *Journal of Aesthetic and Restorative Dentistry*, 2014; 26(1): 27-39.
11. Doxa Dental AB. 510(k) Summary, XeraCem™, K081405, August 21, 2008.
12. Doxa Dental AB. 510(k) Summary, Ceramir Crown and Bridge, K100510, March 25, 2010.
13. Nicholson et al. A review of Glass-Ionomer Cements for Clinical dentistry. *Journal of Functional biomaterials*, September 2016; 7(3): 1-16.
14. Gupta et al. Smart Materials in dentistry: A review. *International Journal of Advance Research and Development*, 2018; 3(6): 89-96.
15. NajmaHajira NSW et al. Giomer-The intelligent particle. *International Journal of Dentistry and Oral Health*, 2015; 2(4): 1-5.
16. Shetty S, MK Manjunath. Biomimetic materials: A review. *International Journal of Medical Research and Review*, 2015; 3(9).
17. Phillip's Science of Dental Materials, First South Asian edition, Chapter 13, 18.
18. Jeong et al. Bioactive Calcium phosphate materials and applications in bone regeneration, *Biomaterials Research*, 2019; 23(4):1-11.
19. Jeong et al. bioactive calcium phosphate materials and applications in bone regeneration. *Biomaterials Research*, 2019; 23(4): 1-11.
20. Martin's et al. Studying the behaviour of Calcium Sulfate: bioactivity and solubility in simulated body fluid. *Dental press Implantol*, 2015; 9(1): 58-65.
21. B. Celikten et al. Evaluation of Root Canal Sealer Filling quality Using a Single-Cone Technique in Oval Shaped Canals: An In Vitro Micro-CT Study. *Scanning Volume*, 2016; 38: 133-40.
22. Polineni, et al. Marginal Adaptation of newer root canal sealers to dentin: A SEM study. *J Conserv Dent*, 2016; 19(4): 360-63.
23. Hegde and Arora et al. sealing ability of three hydrophilic single-cone obturation systems: An in Vitro glucose leakage study.

- ContempClinDent, 2015; 6(1): 86-9.
24. Hegde and Arora et al. sealing ability of a novel hydrophilic vs. conventional hydrophobic obturation systems: A bacterial leakage study. *J Conserv Dent*, 2015; 18(1): 62-5.
  25. Fransen et al. Comparative Assessment of ActiV GP/ Glass Ionomer Sealer, Resilon/Epiphany, and GuttaPercha/ Ah plus Obturation: A Bacterial Leakage study. *J Endod*, 2008; 34(6): 725-27.
  26. Enkel, Dupas, Armengol et al. Bioactive materials in Endodontics. *Expert Rev. Med.Devices*, 2008; 5(4): 475-94.
  27. Muhammad Zafar et al. Bioactive Surface coatings for enhancing osseointegration of dental implants, 2019; 313-29.
  28. Gavino Orduna et al. Endodontic Therapy with PRP. *Journal of Endodontics*, June 2017; 43(8): 1-5.
  29. P.Jithendra Babu et al. Dental Ceramics: Part 1 -An Overview of Composition, Structure and Properties. *American Journal of Materials Engineering and Technology*, 2015; 3(1), 13-18.
  30. Goswami et al. Biomimetic Dentistry, *Journal of Oral Research and Review*, 2018; 10(1), 28-32.

# THE WONDERLIGHT: PHOTOBIMODULATION IN THE MANAGEMENT OF RECURRENT APHTHOUS STOMATITIS

## ABSTRACT

One of the most vague and confusing mucosal conditions in general practice is Recurrent aphthous stomatitis otherwise called canker sores, characterized by painful multiple recurrent ulcers of the oral mucosa. Not only is the etiopathogenesis of RAS unclear, the management of the same remains to be confusing for a general practitioner. The usual modalities of treatment are topical analgesics and anti-inflammatories as well as topical corticosteroids with varied results. The ulcers invariably return. Systemic correlation of the condition is a must. In this paper we attempt to show the effectiveness of Low Level Laser Therapy/ LLLT as an effective management tool in a female patient.

**Key words:** Aphthous ulcers, Diode Lasers, Menstrual cycle, Photobiomodulation

## Authors:

Dr. Esha Nausheen<sup>1</sup>  
Dr. Madhu Hariharan<sup>2</sup>  
Dr. Kaushik Haridas<sup>3</sup>  
Dr. Ravikant<sup>4</sup>

<sup>1</sup>Private Practitioner  
Dr. Madhu's Centre for Laser Dentistry  
and Endodontics  
Kochi, Kerala

<sup>2</sup>Reader  
Department of Conservative Dentistry  
and Endodontics  
Amrita School of Dentistry  
Amrita Vishwa Vidyapeetham  
Kochi, Kerala

<sup>3</sup>Assistant Professor  
Department of Conservative Dentistry  
and Endodontics  
Amrita School of Dentistry  
Amrita Vishwa Vidyapeetham  
Kochi, Kerala

<sup>4</sup>Private Dental Practitioner  
Varma Hospital  
Kochi, Kerala

## Address for correspondence:

Dr. Esha Madhu  
Private Dental Practitioner  
Dr. Madhu's Centre for Laser Dentistry  
and Endodontics  
Kochi, Kerala  
Contact: +91 9895541308  
Email: eshamadhu83@gmail.com

J Ind Dent Assoc Kochi 2019;1(2)32-6.



## INTRODUCTION

Recurrent aphthous stomatitis is a debilitating disease of the oral mucosa affecting not only the physical health but causing psychological stress as well. Repeated occurrence of the same condition hugely effects the life style of the patient. Aphthous ulcers are the most common ulcerative lesion of the oral mucosa effecting almost 25% of the general population.<sup>1</sup> The term aphthae is derived from a Greek work aphthi meaning 'to set on fire'<sup>2</sup> which aptly describes what the patient feels in this condition.

Recurrent aphthous stomatitis as the name suggests is a condition characterized by recurrent bouts of multiple aphthous ulcers in the oral mucosa. The ulcers are oval/round, small in size and extremely painful. The exact etiology still remains unknown although a number of predisposing factors seem to contribute to the pathogenesis of this condition.<sup>3,4</sup> It is commonly seen in female patients falling in the age group of 10-40 years.<sup>5,6</sup> It has also been said that this condition is commonly seen in individuals belonging to the higher socio-economic levels.<sup>7</sup> The most common predisposing factors include hormonal changes, stress, trauma, drugs, nutritional deficiency, food allergies, tobacco and gastrointestinal disorders like Celiac disease, Cronh's disease, and ulcerative colitis.

RAS presents itself in mostly on non-keratinized mucosa but it is occasionally seen on keratinized mucosa as well<sup>8</sup>. Clinically RAS is characterized by well defined round/oval shaped small multiple ulcers surrounded by erythematous halo and covered by fibrous coating. Three main types of RAS can be distinguished clinically: Minor RAS (Mikulicz's

disease), Major RAS (Sutton's aphthae), Herpetiform aphthae.<sup>9</sup>

## CASE REPORT

A 40 year old female patient came to our center with reluctantly complaining of multiple ulcers in her mouth since 10 years. She was not a cooperative patient, thinking these ulcers are a part of her life. She has visited a number of doctors over the past and has tried topical anesthetics, topical corticosteroids, oral corticosteroids to no avail. She visited our center on the insistence of her husband. She gave a history of recurrent painful ulcers all over her lip, under her tongue, floor of the mouth and gingiva which stays for more than 2 weeks and slowly heal followed by pain-free period of around a week. The ulcers start to appear again. This cycle revolves around her menstrual cycle with the peak painful time being a few days post-menstruation.

The ulcers are associated with inability to eat even slightly spicy food, weight loss and mood swings. She was finding it difficult to brush even with a soft bristled tooth brush.

On examination multiple small pale ulcers with an erythematous halo seen on the mucosal surface of lower lip, lateral border of the tongue and floor of the mouth.

Marginal gingivitis was seen with presence of calculus.

Mandibular anterior segment shows inflamed gingiva involving the attached gingiva.

This was her fist visit to our center 5 days after her menstrual cycle.

The pain was measure using the Visual Analogue scale. (Figure 1)

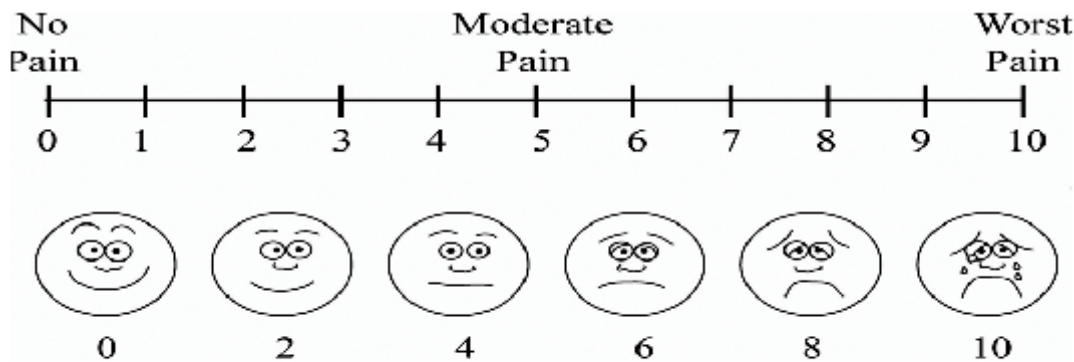


Figure 1: VAS used to quantify the pain.

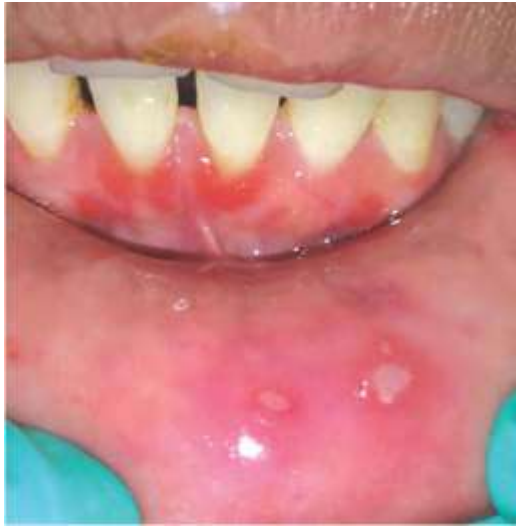

Figure 2

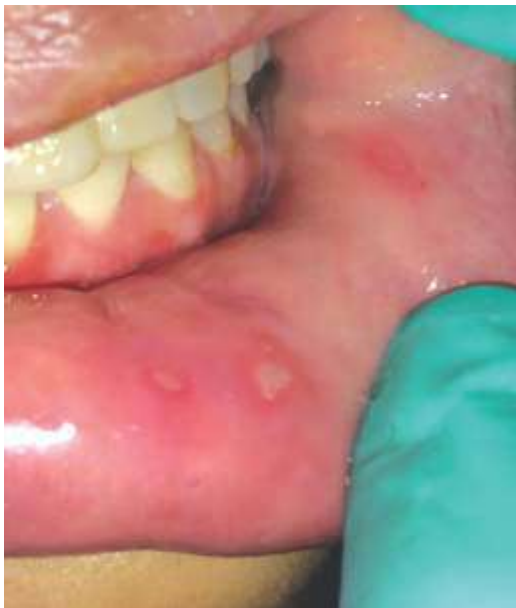

Figure 3

The ulcers on her lower lip (Figure 2,3) were reported to be most painful with a VAS score of 8.

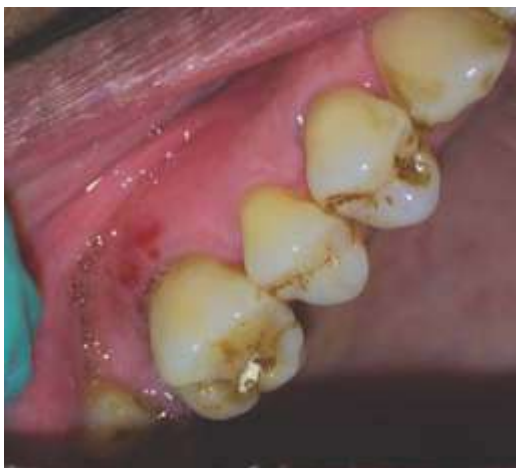

Figure 4

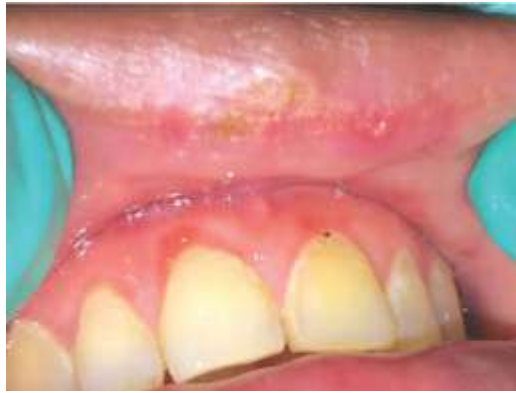

Figure 5

The rest of the ulcers (Figure 4,5) had a score of 4-7 with ulcers on the floor of the mouth and lateral border of the tongue (Figure 6,7,8) being 7.

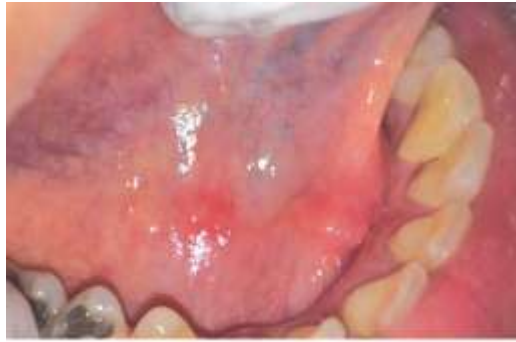

Figure 6

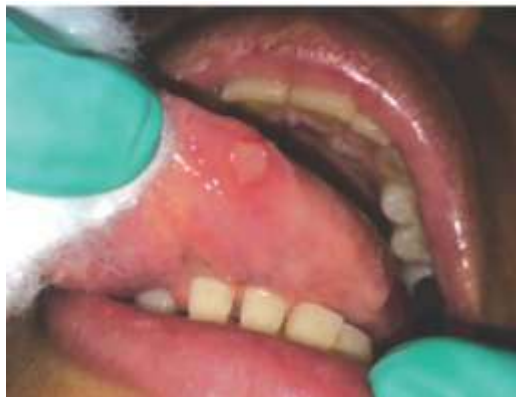

Figure 7

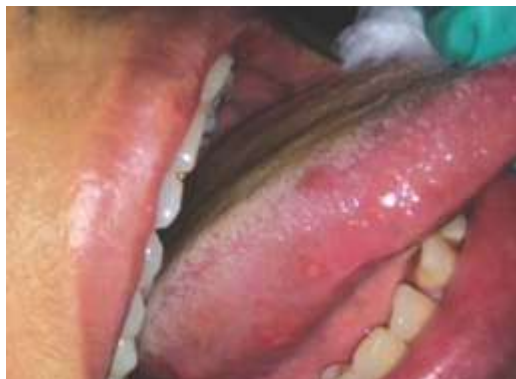

Figure 8

The patient gave a score of 5 for mandibular anterior gingivitis.

Since the patient had already undergone most of the conventional mode of treatment, we decided to manage the symptoms using Diode laser with 980nm wavelength in the Low Level Laser Therapy/Biomodulatory mode.

The ulcers were irradiated with 3Joules per cm square every alternate days for a week. Total of 3 sessions were given during the first week. Reduction in symptoms as well as the intensity of the inflammation was seen after the 2nd session itself.

Supragingival scaling was done which was well tolerated.

4th session onwards the ulcers were irradiated once in 3 days for 3 sessions. By then the number of ulcers had significantly reduced. The patient was on her first day of the next menstrual cycle by then.

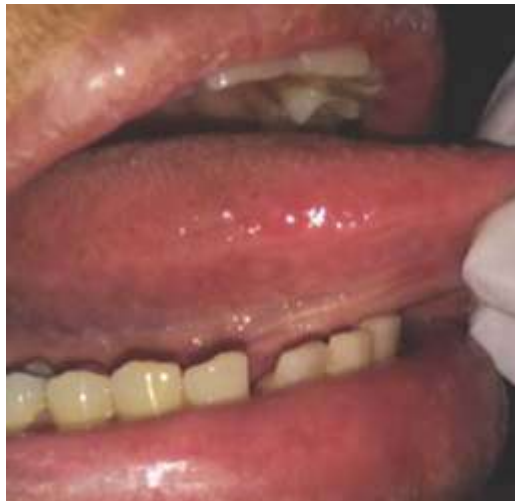

Figure 9

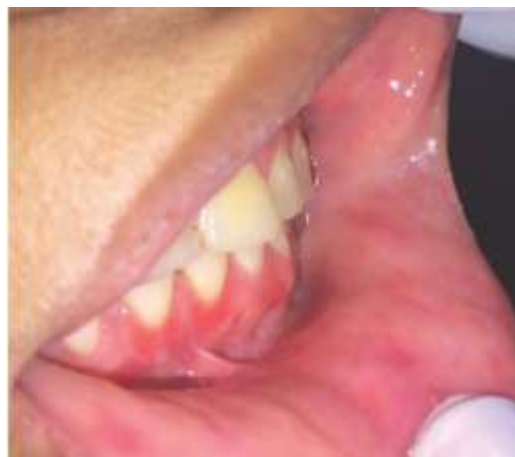

Figure 10

There was no increase in number of ulcers seen after the laser session. (figure 9,10)

The patient rated the pain score on VAS as none of the ulcers having a score of more than 2.

The mandibular anterior gingiva still appeared inflamed (Figure11) but the patient was comfortable with no issues during brushing

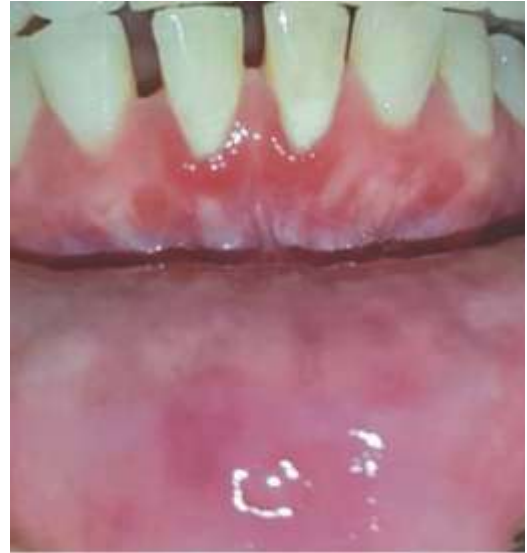

Figure 11

her teeth. The patient was pain free for most of the days during the next one month with mildly painful ulcers 3-4 in numbers at any given time.

The patient was motivated by her spouse to undergo the treatment and once the patient reached a comfortable stage she stopped her laser sessions. If continued complete eradication of the condition could have been possible.

No other medication; topical or otherwise was prescribed during the laser sessions.

## DISCUSSION

Low Level Laser Therapy, also called Photobiomodulation, is an extremely useful light therapy which uses low intensity light to cause cellular level changes in the tissues. It acts by causing photo chemical changes in the tissues rather than thermal changes.<sup>10</sup>

In RAS, the immune response is triggered against factors any of the predisposing factors and thereby initiate an abnormal cascade of cytokine response. Both humoral as well as acquired immune system appear to be



activated. The main cells which play a role in the development of ulcers are cytokines especially IL-2,IL-12,TNF-a which in turn cause the secretion of IgE.<sup>8</sup> TGF-b secreted by T-regulatory lymphocytes also appear to play a role.

Once the immune response is altered, the concentration of NK cells, B lymphocytes increases along with disruption of CD4: CD8 ratio. This in turn results in all the inflammatory symptoms seen in RAS.

In this case we used a 980nm diode laser in 0.1W power. How did this help in improving the symptoms associated with RAS? Lasers have been proved to reduce pain associated with inflammation by lowering the levels of IL-1, TNF-a, prostaglandins etc.<sup>11</sup> It also increases the production of ATP in the mitochondria and changes the capillary hydrostatic pressure there by reducing edema.

Lasers at the appropriate dosage cause reversible changes in the voltage-gated Na-K channels which reduces the pain in RAS. (11) Multiple exposure to the low intensity light is required to bring about long lasting results.

Being a vague and generally confusing condition, management of RAS is tricky. LLLT is an excellent mode of managing the symptoms, if not the predisposing factors, which ultimately results in better life style.

Low level laser have a plethora of applications in dentistry, right from wound healing post extraction/surgery, correction of neurological conditions to TMJ pathologies. The future lies in the hands of dental lasers.

## REFERENCES

1. Bassel Tarakji, Giath Gazal, Sadeq Ali Al-Maweri, Saleh Nasser Azzeghaiby, Nader Alaizari. Guidelines for the Diagnosis and Treatment of Recurrent Aphthous Stomatitis for Dental Practitioners. *Journal of International Oral Health* 2015; 7(5):74-80
2. Natalie Rose Edgar, Dahlia Saleh, Crichard A. Miller. Recurrent Aphthous Stomatitis: A Review. *J Clin Aesthet Dermatol.* 2017;10(3):26-36
3. Narjiss Akerzoul & Saliha Chbicheb. Low laser therapy as an effective treatment of recurrent aphthous ulcers: a clinical case

reporting two locations. *Pan African Medical Journal.* 2018; 30:205

4. Fernandes R, Tuckey T, Lam P, Sharifi S, Nia D. The best treatment for aphthous ulcers: an evidence based study of literature. *J Am Dent Ass.* 2008; 134: 200-7.
5. Chavan M, Jain H, Diwan N, Khedkar S, Shete A, Durkar S. Recurrent aphthous stomatitis: a review. *J Oral Pathol Med.* 2012;41:577- 83.
6. Baccaglioni L, Lalla RV, Bruce AJ, Sartori-Valinotti JC, Latortue MC, Carrozzo M, et al. Urban legends: recurrent aphthous stomatitis. *Oral Dis.* 2011;17:755-70.
7. Treatment of recurrent aphthous stomatitis. A literature review Irene Belenguer-Guallar<sup>1</sup>, Yolanda Jiménez-Soriano<sup>2</sup>, Ariadna Claramunt-Lozano *J Clin Exp Dent.* 2014;6(2):e168-74.
8. Etiopathogenesis of Recurrent Aphthous Stomatitis and the Role of Immunologic Aspects: Literature Review Zuzanna S lebioda • Elz bieta Szponar • Anna Kowalska *Arch. Immunol. Ther. Exp.* (2014) 62:205-215.
9. Tappuni AR, Kovacevic T, Shirlaw PJ et al (2013) Clinical assessment of disease severity in recurrent aphthous stomatitis. *J Oral Pathol Med* 42:635-641.
10. Cotler HB, Chow RT, Hamblin MR, Carroll J (2015) The Use of Low Level Laser Therapy (LLLT) For Musculoskeletal Pain. *MOJ Orthop Rheumatol* 2(5).
11. Kohale BR, Agrawal AA, Sope AB, Pardeshi KV, Raut CP. Low-level Laser Therapy: A Literature Review. *Int J Laser Dent* 2015;5(1):1-5.

# MANAGEMENT OF BILATERALLY MISSING MAXILLARY LATERAL INCISORS WITH STRATERGIC IMPLANTS - A CASE REPORT

## Authors:

Dr. Prasanth Pillai<sup>1</sup>  
Dr. Bobby Antony<sup>2</sup>

Oral and Maxillofacial<sup>1</sup>  
Surgeon and Director  
The Smile Centre  
Subash Bose Road  
Kadavantra  
Kochi, Kerala

Associate Dental Surgeon<sup>2</sup>  
The Smile Centre  
Subash Bose Road  
Kadavantra  
Kochi, Kerala

## Address for correspondence:

Dr. Bobby Antony  
Associate Dental Surgeon  
The Smile Centre  
Subash Bose Road  
Kadavantra  
Kochi, Kerala  
Contact: +91 9400326184  
Email: bobzant@gmail.com

## ABSTRACT

Bilaterally missing permanent laterals is a phenomenon which causes much distress to the patient due to aesthetic issues and also discomfort while speaking. Though several treatment modalities have been developed to treat the edentulous areas, implants and in particular strategic implants have been found to be better option due to its immediate functional loading quality and avoidance of periimplantitis, because of smooth surface crestal microthreads which does not allow bacterial invasion. This article out line a case report of a young male patient with bilaterally missing laterals and subsequent treatment with strategic implants with three year follow up.

**Key words:** Bilaterally Missing permanent lateral incisors, strategic implants

## INTRODUCTION

Congenital bilaterally missing maxillary laterals occurs in almost 2% of the population in the world in the permanent dentition phase<sup>1</sup>. Except for the third molars, agenesis of the maxillary lateral incisor has been the most frequent kind among different populations. Dental agenesis in the maxillary anterior region compromises smile balance and symmetry and compromises the self-confidence of the patient in social situations where they have to smile or speak publicly<sup>2</sup>.

Treatment modalities for bilaterally missing lateral incisors is dependent on the space that is present between the canines and the central incisors. If there is insufficient space (less than 4mm) then the canines are orthodontically moved into the space of the lateral and the premolar to space of the canine and the canine is crowned to look like an incisor.

If there is sufficient space, a removable partial denture may be provided in the traditional fashion to replace the laterals, but this option is un-acceptable to most patients as the denture can turn loose within a short span of time in addition to causing hindrances in mastication and phonation. Maintenance of the removable denture also turns out to pose problems along with issues of food entrapment around the denture leading to further dental issues. The fixed replacement options are bridgework and the implant supported crowns. The bridgework needs to be fabricated over the canine and the central incisor as abutments and the lateral incisor as the pontic. This involves unnecessary reduction of the adjacent teeth which may require root canals later on.

The best option available today is to replace the missing teeth with the help of dental implants. Through this option, the patient is able to procure a solution closest to natural teeth and today with keyhole implant surgery approaches, this option turns out to be the least invasive option available. Conventional two-piece implants have been used to replace missing laterals. However, the open surgical approach and the need for bone augmentation

to compensate for the labial defects which are very often found in cases of congenitally missing laterals, pose additional surgical steps. The delayed loading protocols followed with conventional two piece implants and the predisposition to peri implantitis due to the rough surface design adds to the complexity in offering solutions<sup>5</sup>.

In recent times, with the introduction of minimally invasive designs offered in strategic implantology, we are able to provide the patient with immediate load implant supported prostheses which can be placed employing key-hole surgical methods without the need for bone augmentation procedures. Strategic implantology is immediate functional loading implantology based on the principles of orthopedic traumatology<sup>3</sup>. A unique feature of Strategic Implants is that no bone augmentation procedures are required<sup>5</sup>. This is because the system has a wide variety of designs which can be used depending on the quality, width and height of bone available.

The KOC Implant design available in Strategic Implantology is of compressive screw design and is a rough surface implant with the revolutionary “no-it is” surface which reduces the possibilities for peri-implantitis to develop<sup>4</sup>. It's unique compression screw design helps in expanding bone even in thin ridge situations thereby helping avoid bone augmentation procedures<sup>6</sup>.

## CASE REPORT

A patient reported to our center with a complaint of missing upper lateral incisors, and an unsightly smile. The patient was wearing a hawley's appliance with two acrylic lateral teeth attached to the plate. Clinical examination was done and patient was sent for radiographic diagnosis. Third molars of all the quadrants had been already extracted. Different treatment modalities to replace the missing teeth was discussed with the patient. The patient chose to go for dental implants as it would give a long lasting fixed teeth solution without compromising the health of the adjacent teeth as against bridges.



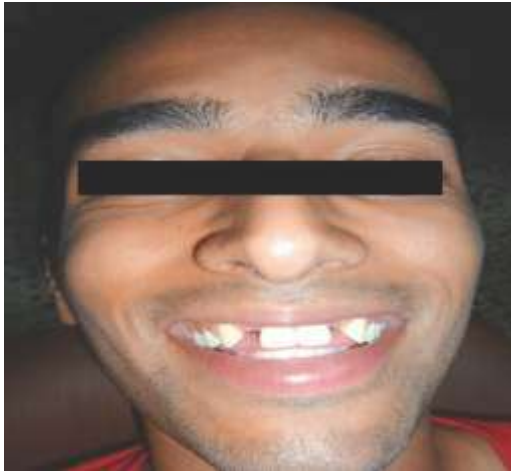

Fig 1: Extraoral view

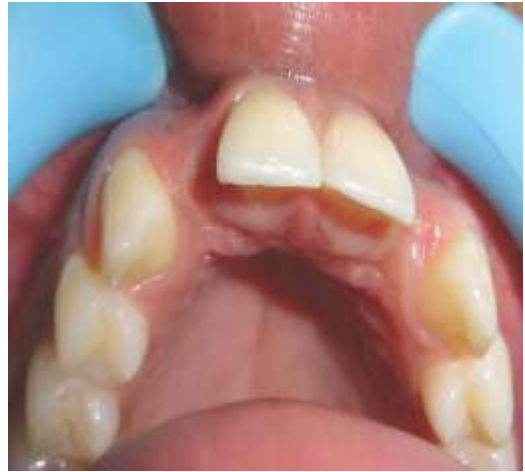

Fig 3: Intraoral view

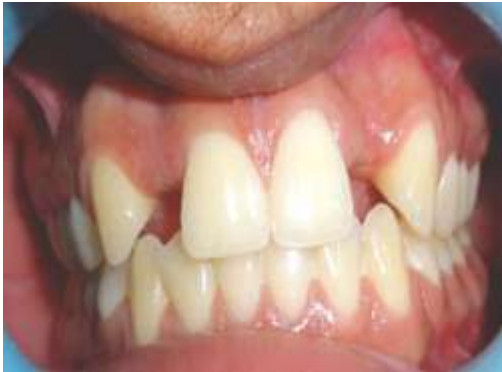

Fig 2: Intraoral view

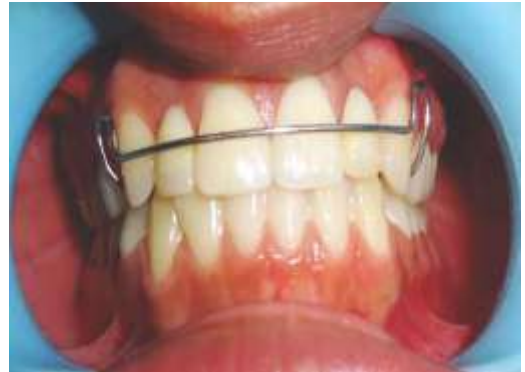

Fig 4. Hawley's appliance with acrylic teeth

Different treatment modalities to replace the missing teeth was discussed with the patient. The patient chose to go for dental implants as it would give a long lasting fixed teeth solution without compromising the health of the adjacent teeth as against bridges.

A CBCT of the maxilla was done to assess the bone height and width in both areas.

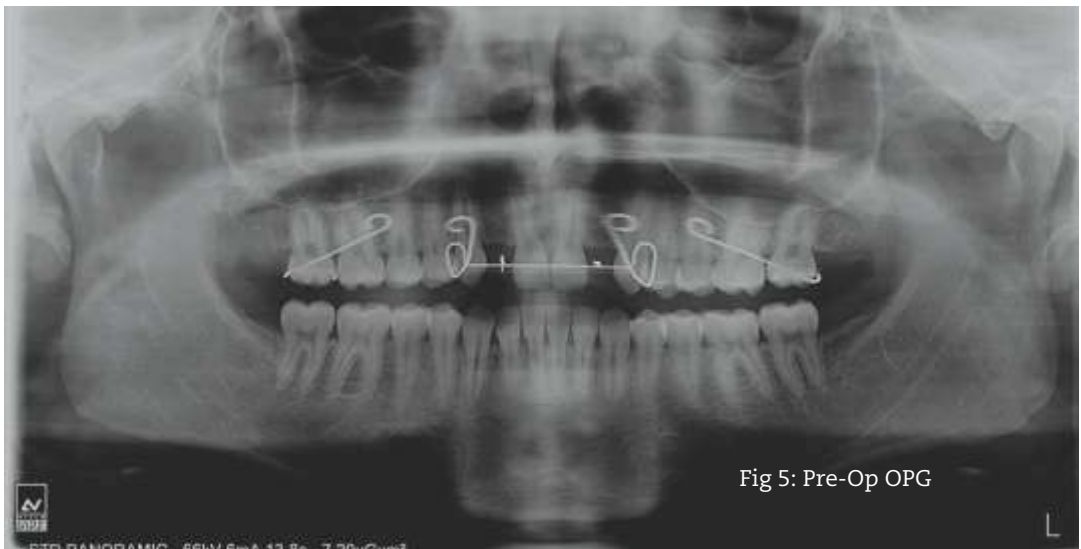

Fig 5: Pre-Op OPG

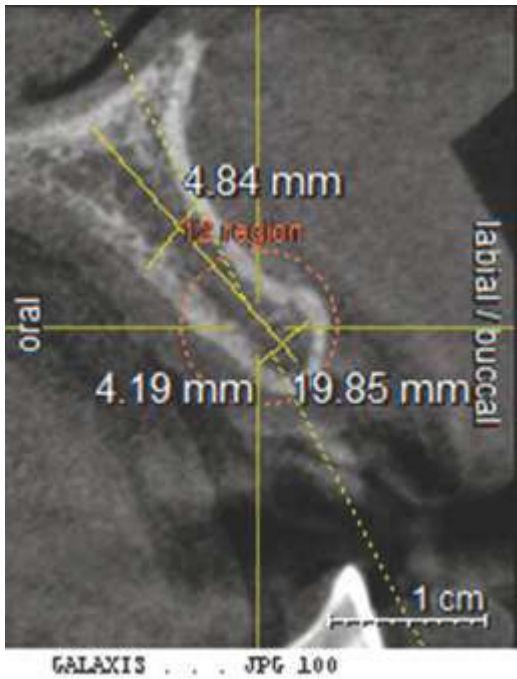


Fig 6 : CBCT [Rt]

In the right lateral incisor:

Mesiodistal width from the distal aspect of 11 to mesial aspect of 13 = 4.64 mm

Total length from alveolar crest to nasal floor = 19.85 mm

Palatal – labial width at alveolar crest = 4.19 mm

Palatal – labial width at alveolar base = 4.84 mm

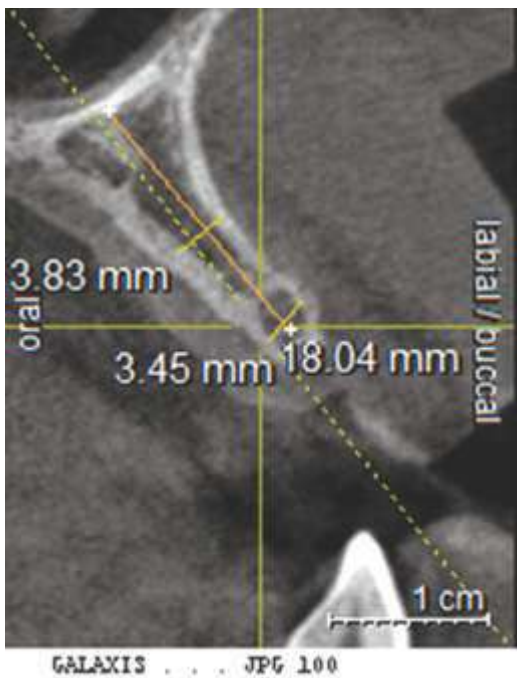


Fig 7: CBCT [Lt]

In the left lateral incisor:

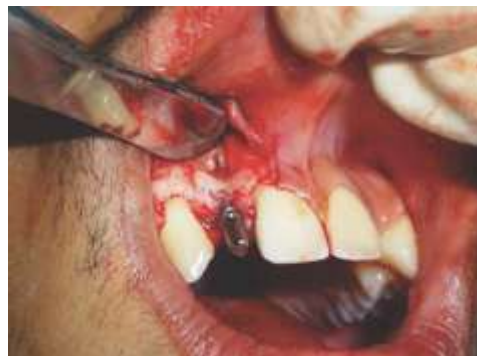Mesiodistal width from the mesial aspect of 23 to distal aspect of 21 = 5.05 mm

Total length from alveolar crest to nasal floor = 18.04 mm

Palatal – labial width at alveolar crest = 3.45 mm

Palatal – labial width at alveolar base = 3.83 mm

It was decided to use the KOC implant in both left and right laterals to facilitate their replacement. The patient was given local anesthesia in both the planned areas of implant placement. A flap was opened on the right side due to very deficient bone width to properly ascertain the purchase point as the bone thickness was less. Initial osteotomy was done with the BCD 1 pilot drill followed by the DOS 1 drill up to half the length of the proposed implant size. Two KOC 3.7mm X 15 mm implants were placed.



ig 8 : Intra op KOC implant[Rt]

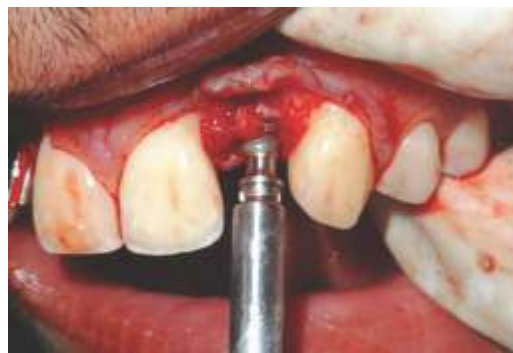

Fig 9: Intra op KOC implant[Lt]

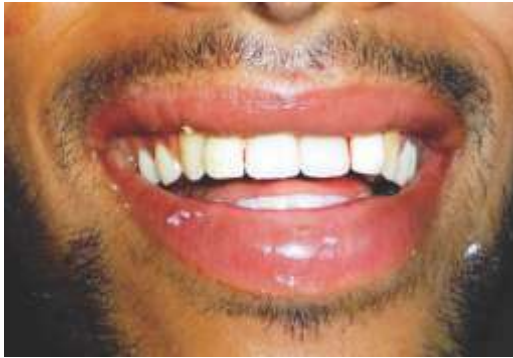

Fig 10: After placement of temporary

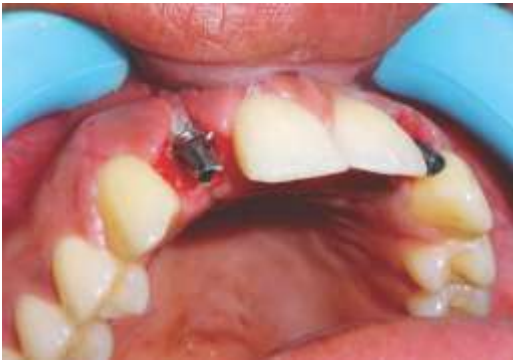

Fig 11: Three days after healing of implants

An immediate Post Op CBCT was taken to assess the position of the implant in the coronal and sagittal sections which confirmed optimal positioning of the implant both mesio-distally and bucco-lingually. NSAIDs were given to control post op edema and pain. Impression was taken and temporary acrylic crowns were cemented by the second day of implant surgery. The patient returned after three years to replace the acrylic crowns. Clinical examination of the patient revealed that the excellent peri-implant gingival profile.

A CBCT was done to assess the status of the peri implant bone at the crestal levels. The bone levels were found to be excellent without any drop in bone height. After minimal preparation and adjustment of the abutment of the single piece KOC implant, Zirconia Crowns were fabricated and cemented over the implants with GIC luting cement.

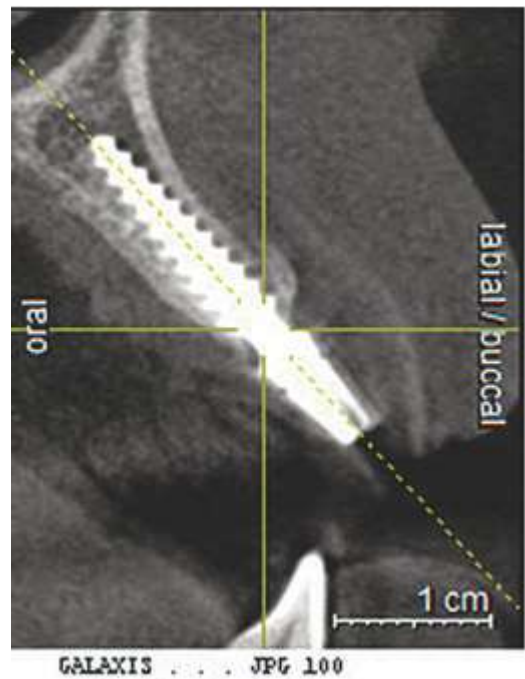


Fig 13: Post op CBCT [Rt]

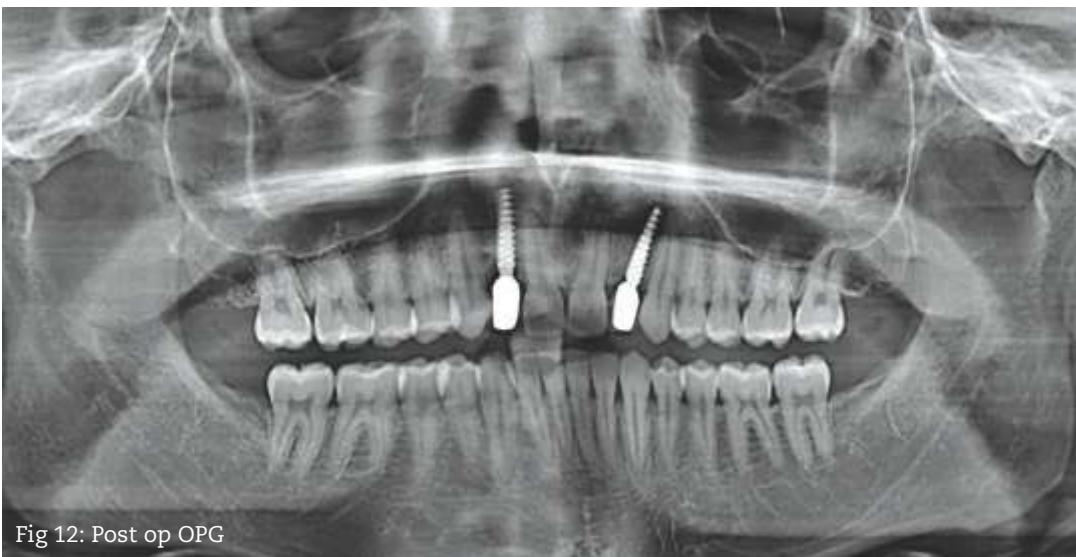

Fig 12: Post op OPG



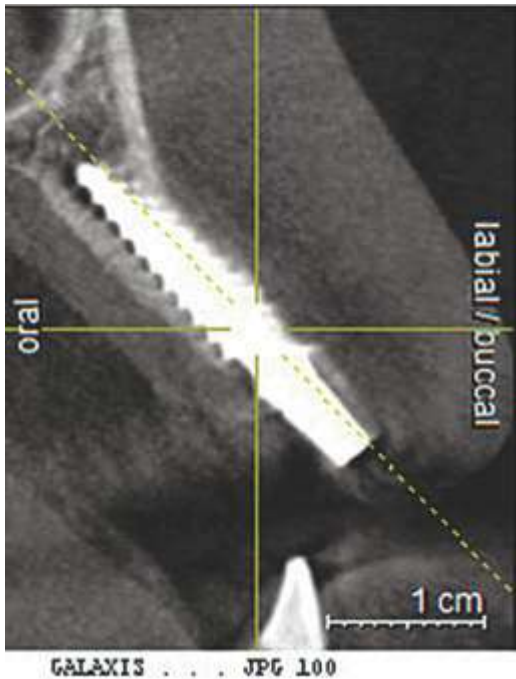


Fig 14 : Post op CBCT [Lt]

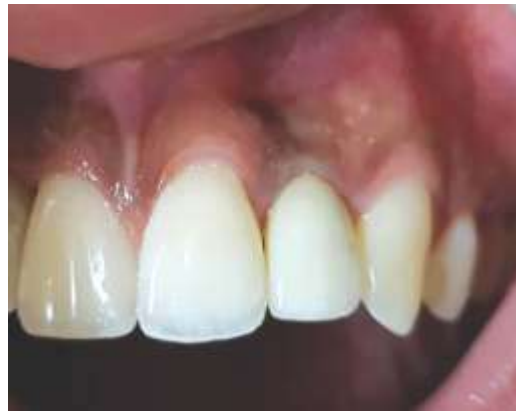

Fig 15: Zirconia crown labial view

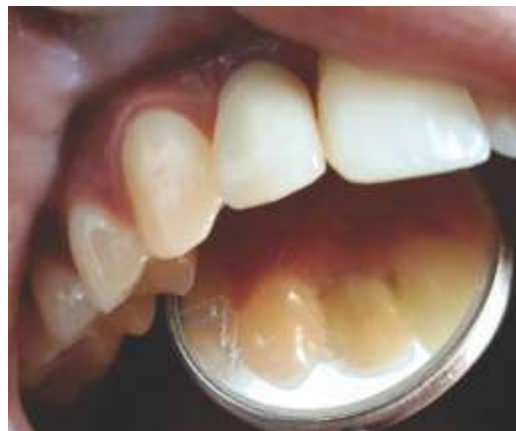

Fig 16 : Zirconia crown palatal view

## CONCLUSION

Immediate functional loading of implants is not only the requirement of the patient and the doctor but also facilitates more favorable bone response than delayed loading. KOC implants with its special compression screw design is one of the most ideal implants which will help the dental practitioner to provide an excellent immediate load solution for such patients. KOC implants placed following all prescribed protocols, have very high success rate

Table Taken from “Immediate functional loading: Results for the concept of the strategic Implant“

Table 15: Implants survival rate (for each implant type) for placement in fresh extraction sockets or healed bone

| Type of implants | Placed into fresh extraction sockets yes/no | Radiological follow-up | Clinical inspection as follow- up | Patient report as follow- up |
|------------------|---|------------------------|-----------------------------------|------------------------------|
| BECES            | 493/526 (48.4%/51.6%)                       | 94.7%/93.0%            | 94.9%/93.0%                       | 96.3%/95.6%                  |
| Significance (P) |   | 0.761                  | 0.745                             | 0.867                        |
| KOS              | 29/114 (20.3%/79.7%)                        | 100%/98.0%             | 100%/98.1%                        | 100%/98.1%                   |
| Significance (P) |   | 0.479                  | 0.479                             | 0.483                        |
| KOS+             | 2/4 (33.3%/66.7%)                           | 0%/75.0%               | 0%/75.0%                          | 0%/75.0%                     |
| Significance (P) |   | 0.062                  | 0.062                             | 0.062                        |

\*Statistically significant. \*Log rank. Survival rates for Implants BCS/BECS, KOS and KOS Plus. The survival of BOI implants is 100%

## REFERENCES

- 1) Perception of attractiveness of missing maxillary lateral incisors replaced by canines. Souza RA, Alves GN, Dental press J Orthod. 2018 Sep-Oct;23(5):65-74.
- 2) Management of missing maxillary lateral incisor. Sabri R1 J.A.M.Dent.assoc. 1999 Jan;130(1):80-4.
- 3) Introduction into the Work with Strategic Implants. Ihde S, Ihde A 3rd ed. Munich, Germany: The International Implant Foundation Publishing; 2017.
- 4) Scientific classification & evaluation: Comparison of basal and crestal implants and their modus of application. CMF Impl. Dir. Vol.4 N° 1 Januar: 4– 17 (2009), Ihde S.
- 5) Comparison and definition of the pathological phenomena occurring after a tooth replacement and the possible therapeutic stages implying basal and crestal implants Ihde S. &Konstantinovic. Implantodontie 14 (2005) 176-185, V. (10).
- 6) The primary stability and survival rate of 2-stage, conical compression screw implants; Ihde S., Soo-Nam Yang, Yoo Hyo Ha. J Maxillofac Oral SurgInd, 2008, Vol 7, No. 2: 273– 277.

# CRUCIAL RADIOGRAPHIC APPRAISAL OF ROOTS - A KEY TO ENDODONTIC SUCCESS

## ABSTRACT

Missing canal is the most common cause which contribute endodontic failures. Proper radiographic diagnosis should be there to identify extra root or extra canal. Radix Entomolaris is the clinical situation where an extra root is present disto-lingually. Clinicians must identify the presence of extra root which will lead to successful endodontic treatment.

**KeyWords:** Radix Entomolaris, Third Root.

## Authors:

<sup>1</sup>Dr. Ravindra Jagannath Jadhav

<sup>2</sup>Dr. Sudha Mattigatti

<sup>3</sup> Dr. Lygi C. John

<sup>4</sup> Dr. Prachi Ingale

<sup>1</sup>Assistant Professor  
Department of Conservative Dentistry  
and Endodontics  
VasantdadaPatil Dental College and Hospital  
Kavalapur, Taluk- Miraj,  
Sangli 416306, Maharashtra

<sup>2</sup>Associate Professor  
Department of Conservative Dentistry  
and Endodontics  
School of Dental Sciences  
Krishna Institute of Medical Sciences  
Deemed University  
Karad, Maharashtra

<sup>3</sup>Private Practitioner  
Mumbai

<sup>4</sup>Private Practitioner  
Pune

## Address for correspondence:

Dr. Ravindra Jagannath Jadhav  
Assistant Professor  
Department of Conservative Dentistry  
and Endodontics  
Vasantdada Patil Dental College and Hospital  
Kavalapur, Taluk- Miraj,  
Sangli 416306, Maharashtra  
Email: ravindrajadhavbds@yahoo.in

J Ind Dent Assoc Kochi 2019;1(2)44-50.



## INTRODUCTION

For more than 50 years there has been universal agreement that the endodontic success depends on the triad that consists of shaping canals, cleaning in 3 dimensions, and three-dimensional hermetically sealed obturation of the canal systems.<sup>1</sup> The main and most important objective of root canal therapy is thorough shaping and cleaning of all pulp spaces and its complete 3 dimensional obturation with an inert filling material. Canal preparation is the most important and challenging part of the triad due to the complex morphology of the root canal system. The main reason for failure of root canal treatment is presence of an untreated canal. Therefore it is essential to have a thorough knowledge about internal and external morphologies of the teeth and together with diagnosis and treatment planning, it is a basic requirement for endodontic success.<sup>2</sup>

Following are the main factors behind the failure of root canal treatment:

- 1) incomplete removal of pulp,
- 2) lack of tight apical and coronal seal and
- 3) last but not least missed canals.<sup>3</sup>

Thus, the clinician should be aware of the various internal and external morphologies of permanent tooth and the possible variations which may be encountered during the root canal treatment of permanent tooth.<sup>4</sup>

The first posterior tooth to erupt in the oral cavity is the mandibular first molar and hence it is the tooth that most often requires root canal treatment. The mandibular first molar typically has two well-defined roots, mesial root and distal root. Mesial root has flattened mesiodistal surface and widened buccolingual surface and distal root is straight with a wide oval canal or two round canals.<sup>5</sup> Mostly, the mesial root has two root canals ending in two distinct apical foramina, whereas in some cases these merge together at the root tip to end in a single foramen. The canals of the mesial root take a more curved course with a mesial orientation immediately below the orifice and then distal in the rest of the root canal.<sup>6</sup> The distal root typically has one kidney-shaped root canal and the orifice is particularly narrow and round sometimes a second distal canal may also be present.<sup>7</sup>

Following are the various anatomical

variations that have been described in the mandibular first molar:

- 1) the presence of three mesial canals was reported by Fabra-Campos<sup>7,8</sup> and Bond<sup>9</sup>.
- 2) the presence of three distal canals was noted by Stroner<sup>10</sup>.

Like the number of root canals, the number of roots may also vary in some tooth. Carabell, first mentioned in the literature an additional third root<sup>11</sup>, and Bolk termed it as radix entomolaris (RE) in 1915<sup>12</sup>. This additional or supernumerary root is located distolingually in mandibular molars, mainly first molars. When an additional root is present at the mesiobuccal side it is called the radix paramolaris (RP). Carlsen and Alexandersen described the identification and external morphology of these root complexes, containing a lingual or buccal supernumerary root<sup>13,14</sup>.

## CASE REPORT

A male patient 22-year-old reported to the Department of Conservative Dentistry & Endodontics, SDS, KIMSUDU with a chief complaint of pain in lower-right posterior teeth from a few days. Intra-oral examination of the lower arch, revealed deep occlusal caries with respect to the first molar of right quadrant [Figure 1] and the teeth was tender to percussion. The mobility of the teeth were within physiologic limits and vitality testing revealed the teeth to be non-vital. The medical history of the patient was noncontributory.

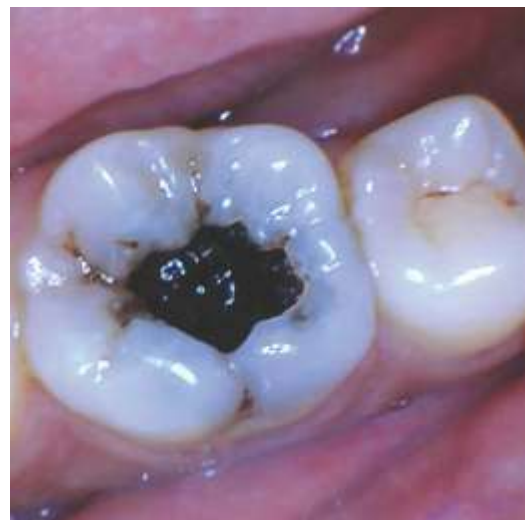

Figure 1 – Intra oral Clinical Image

Radiographically, there was radiolucency involving enamel, dentin and pulp. Periapical radiograph taken from the mesial angulation, revealed the presence of an additional distolingual root, which was of slightly curved and of the same length to that of the distal root. [Figure 2]

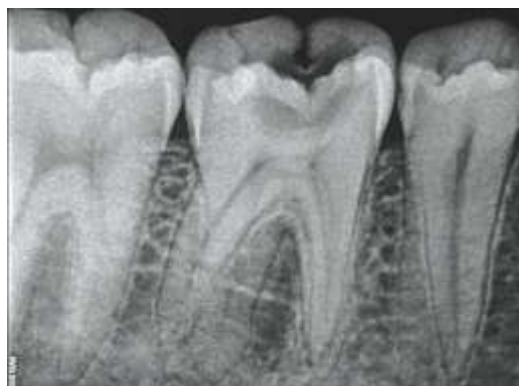

Figure 2 - Pre-operative Radiograph

### Treatment

The tooth was anesthetized and Caries excavation was done, followed by access opening with 46, under rubber dam isolation. Pulp chamber was de-roofed. Three canal orifices were initially identified. On further exploration, a second distal canal was found which was located more lingually. [Figure 3]

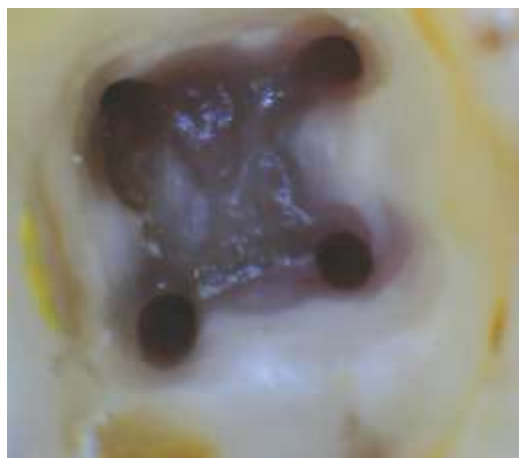

Figure 3. Clinical Image Of Access Opening

To have proper location of orifice, and straight line access of this third root, access cavity was modified from conventional triangular to trapezoidal form with more extension to lingual side.

Initial negotiation of the root canals was performed with Mani stainless steel K file size

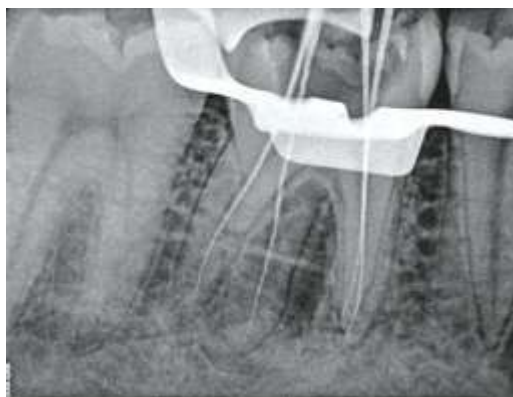


Figure 4 – Working Length Radiograph

ISO 10. The working length of the canals was determined electronically using an apex locator Root ZX Mini [J morita] and confirmed radiographically. [Figure 4]

Canals were cleaned and shaped using hybrid technique with C-Pilot [SybronEndo] hand NiTi files ISO 15, 20 & 25 with .02 taper which is followed by Hero Shaper [Micro Mega] rotary Ni-Ti files of ISO size 20/.04, 20/.06 & 25/.06 using EDTA gel as a lubricant.

Canals were irrigated using 3% sodium hypochlorite solution to remove smear layer and flushed with normal saline. Master cone radiograph was taken. [Figure 5] Obturation of the root canals was performed using AH plus sealer [Dentsply] and corresponding guttapercha points of 25/.06, snugly fitting to the root apex. [Figure 6 and 7] Endodontic access cavity was then sealed using composite resin.



Figure 5. Master Cone Radiograph

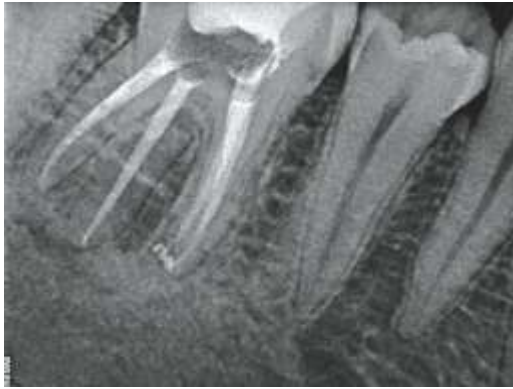

Figure 6. Obturation Radiograph

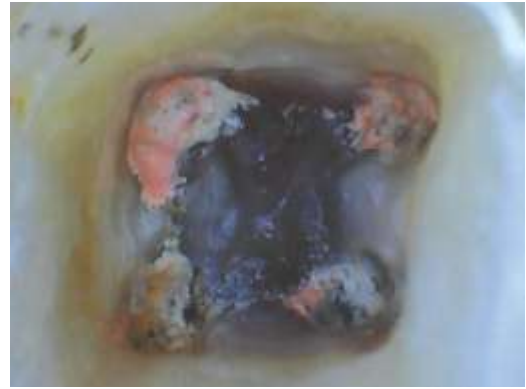


Figure 7. Obturation Clinical Image

## DISCUSSION

Radix Entomolaris (additional root located lingually): The presence of radix entomolaris has been associated with ethnic groups of mongoloid origin (>30%) and low prevalence (<5%) in white Caucasian, African, Eurasian and Indian populations.<sup>15</sup>

In north Indian population about 1.75% cases showed Bilateral occurrence for RE<sup>16</sup> whereas slightly higher rate was observed in south Indian population.

The relationship between radix entomolaris (RE) & gender predilection is not clearly stated. Few studies have reported more of male predilection for RE, While others reported no significant relationship between gender & RE.<sup>17</sup> Similarly, no significant relationship was reported for side distribution, while few studies reported it to be more on left side while others on right side<sup>17</sup>. The bilateral occurrence of RE is reported to vary from 37.14 to 67%. But, some studies have reported only unilateral occurrence of RE, hence further studies are required to clarify this aspect<sup>13,17,18,19</sup>.

In European populations it has been reported that a separate RE is present in the mandibular first molar with a maximum frequency of 3.4-4.2%.<sup>5,20,21,22</sup> In African populations a maximum of 3% is found.<sup>23</sup> In Eurasian and Indian populations the frequency is less than 5%.<sup>24</sup> In populations with Mongoloid traits, such as Chinese, Eskimo and American Indians, the RE occurs with a frequency of 5% to more than 40%.<sup>23,24,25,26,27,28</sup>

The RE is mostly located distolingually, with its coronal third completely or partially fixed to the distal root. The dimensions of the RE can vary. It can be in a form of a short conical extension or a 'mature' root with normal length and root canal. The distolingual root may be separate from other roots or may be partially fused with the other roots.<sup>29</sup>

On the basis of the curve of the root/root canal the RE could be classified in following three groups. This classification is based on a classification proposed by Ribeiro and Consolaro (1997) [Figure 8]

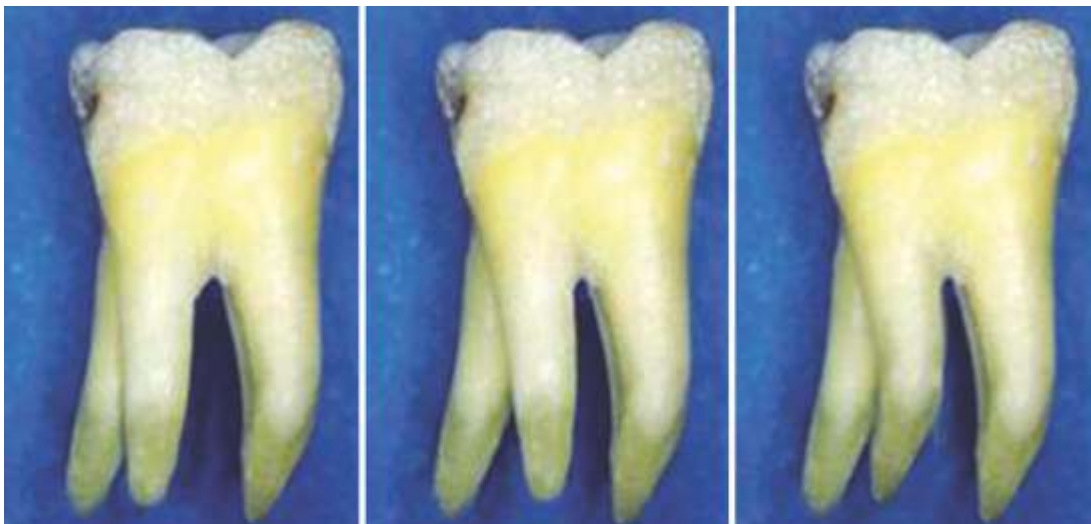

Figure 8 - Ribeiro and Consolaro Classification OF Radix Entomoalris

- 1) Type I refers to a straight root/ root canal,
- 2) Type II to an initially curved entrance and the continuation as a straight root/root canals,
- 3) Type III to an initial curve in the coronal third of the root canal and a second buccally orientated curve starting from the middle to apical third.<sup>30</sup>

According to the location of the cervical part of the RE Carlsen and Alexandersen classified RE in four different types.

- Type A
- Type B
- Type C
- Type AC

Types A and B refer to a distally located cervical part of the RE with two normal and one normal distal root components, respectively.

Type C refers to a mesially located cervical part while type AC refers to a central location between the distal and mesial root components.<sup>13</sup>

Morphologically, the radix entomolaris is located distolingually ranging from short, conical extension to normal mature root length. The coronal third part is partially or completely fixed to distal root. Generally, the radix entomolaris is smaller than mesio-buccal and disto-buccal roots and it may also contain pulpal tissue.<sup>31</sup> Externally, the distal furcation is slightly lower (1mm.) than the furcation between mesial and distal roots.<sup>32</sup>

On clinical examination, features which are observed on a tooth with additional distolingual root includes a more bulbous crown outline, an additional cusp and a prominent distolingual lobe or cervical prominence. These features can indicate the presence of additional root.

Radiographically, third root is visible in 90% of cases.<sup>33</sup> It may be present as unclear outline of distal root or root canal hence, occasionally it may be missed because of its slender dimension or overlapping with distal root therefore radiographs should be carefully inspected to reveal the presence of hidden radix entomolaris. Additional radiographs with different horizontal angulations should be taken for confirming the presence of supernumerary root. Additional radiographs taken from horizontal projections, 20 degree

from mesial and 20 degree from distal reveals the basic information about the anatomy of additional third root.

In addition to this, using magnifying loupes, dental microscope or intraoral camera may also be helpful. OPG is also useful in determining the presence of complex root anatomies. Recently, to aid in the diagnosis of teeth with complex root anatomies cone-beam computed tomography (CBCT) technique has also emerged. However, cost and accessibility are the main limiting factors till now.<sup>34</sup>

With a good knowledge of law of symmetry and law of orifices, following are the various methods which are very useful.<sup>35</sup>

1. Adequate access modification for enhanced visualization
2. Careful observation of dentinal map
3. Fiberoptictransillumination to locate the developmental line between the canal orifices
4. Careful exploration with a sharp instrument (DG16) of floor of the chamber for canal orifices
5. Looking for bleeding points
6. Champagne bubble test with warmed 2.6% NaOCl and observed under magnification
7. Staining the chamber with 1% methylene blue
8. Straight and angled radiographs with instruments in canals.

Some of the common problems which we have encountered during the treatment of Radix Entomolaris are difficulty in Radiographic interpretation, inability to locate the fourth canal, modification in access cavity preparation, confusion in working length determination.

## CONCLUSION

Teeth are never alike. A number of variations occur which pose a challenge to a clinician. Failure to identify and treat an RE can significantly affect the outcome of an endodontic treatment. Proper mesial and distal angulation and interpretation of radiographs help to identify the root canal anatomy and any



variations that are present in it. In the case of a Radix Entomolaris, the conventional triangular access cavity opening must be modified to a trapezoidal form in order to properly locate the distolingually located canal orifice of the extra root.

## REFERENCES

- Ruddle CJ. Endodontic triad for success: the role of minimally invasive technology. *Dent Today*. 2015 May;34(5):76-80.
- Vertucci FJ. Root canal morphology and its relationship to endodontic procedures. *Endodontic topics*. 2005 Mar;10(1):3-29.
- Iqbal A. The factors responsible for endodontic treatment failure in the permanent dentitions of the patients reported to the college of dentistry, the University of Aljouf, Kingdom of Saudi Arabia. *Journal of clinical and diagnostic research: JCDR*. 2016 May;10(5):ZC146.
- Parolia A, Kundabala M, Thomas MS, Mohan M, Joshi N. Three rooted, four canalled mandibular first molar (Radix Entomolaris). *Kathmandu University Medical Journal*. 2009;7(3):289-92.
- Skidmore AE, Bjorndal AM. Root canal morphology of the human mandibular first molar. *Oral Surgery, Oral Medicine, Oral Pathology and Oral Radiology*. 1971 Nov 1;32(5):778-84.
- Vertucci FJ, Haddix JE, Britto LR. Tooth morphology and access cavity preparation. *Pathways of the Pulp*. 2006;9:148-232.
- Fabra-Campos H. Unusual root anatomy of mandibular first molars. *J Endod* 1985;11:568-57
- Fabra-Campos H. Three canals in the mesial root of mandibular first permanent molars: a clinical study. *International endodontic journal*. 1989 Jan;22(1):39-43.
- Bond JL, Hartwell GR, Donnelly JC, Portell FR. Clinical management of middle mesial root canals in mandibular molars. *Journal of endodontics*. 1988 Jun 1;14(6):312-4.
- Stroner WF, Remeikis NA, Carr GB. Mandibular first molar with three distal canals. *Oral Surgery, Oral Medicine, Oral Pathology and Oral Radiology*. 1984 May 1;57(5):554-7.
- Carabelli G. *Systematisches Handbuch der Zahnheilkunde*, 2nd ed. Vienna: Braumuller und Seidel, 1844:114.
- Bolk L. Bemerkungen über Wurzelvariationen am menschlichen unteren Molaren. *Zeitschrift für Morphologie und Anthropologie*. 1915 Jan 1(H. 3):605-10.
- Carlsen O, Alexandersen V. Radix entomolaris: identification and morphology. *European Journal of Oral Sciences*. 1990 Oct;98(5):363-73.
- CARLSEN O, ALEXANDERSEN V. Radix paramolaris in permanent mandibular molars: identification and morphology. *European Journal of Oral Sciences*. 1991 Jun;99(3):189-95.
- Walker RT. Root form and canal anatomy of mandibular second molars in a southern Chinese population. *Journal of Endodontics*. 1988 Jan 1;14(7):325-9.
- Bains R, Bains VK, Loomba K, Loomba A. Prevalence of radix entomolaris and fused roots in mandibular permanent molars of a North Indian population: A hospital-based retrospective radiographic study. *Indian Journal of Oral Sciences*. 2016 Jan 1;7(1):19.
- Abella F, Patel S, Durán-Sindreu F, Mercadé M, Roig M. Mandibular first molars with disto-lingual roots: review and clinical management. *International endodontic journal*. 2012 Nov;45(11):963-78.
- Tu MG, Huang HL, Hsue SS, Hsu JT, Chen SY, Jou MJ, Tsai CC. Detection of permanent three-rooted mandibular first molars by cone-beam computed tomography imaging in Taiwanese individuals. *Journal of Endodontics*. 2009 Apr 1;35(4):503-7.
- Tu MG, Tsai CC, Jou MJ, Chen WL, Chang YF, Chen SY, Cheng HW. Prevalence of three-rooted mandibular first molars among Taiwanese individuals. *Journal of Endodontics*. 2007 Oct 1;33(10):1163-6.
- Taylor AE. Variations in the human tooth-form as met with in isolated teeth. *Journal of anatomy and physiology*. 1899 Jan;33(Pt 2):268.

21. Turner CG. Three-rooted mandibular first permanent molars and the question of American Indian origins. *American Journal of Physical Anthropology*. 1971 Mar;34(2):229-41.
22. Steelman R. Incidence of an accessory distal root on mandibular first permanent molars in Hispanic children. *ASDC journal of dentistry for children*. 1986;53(2):122-3.
23. Sperber GH, Moreau JL. Study of the number of roots and canals in Senegalese first permanent mandibular molars. *International Endodontic Journal*. 1998 Mar;31(2):117-22.
24. Tratman EK. Three rooted lower molars in man and their racial distribution. *Br Dent J*. 1938;64:264-74.
25. Curzon ME. Three-rooted mandibular permanent molars in English Caucasians. *Journal of Dental Research*. 1973;52(1):181.
26. PECORA JD. Three-rooted mandibular molars in patients of Mongolian, Caucasian and Negro origin. *Braz Dent J*. 1992;3(2):113-7.
27. Yew SC, Chan K. A retrospective study of endodontically treated mandibular first molars in a Chinese population. *Journal of endodontics*. 1993 Sep 1;19(9):471-3.
28. Ahmed HA, Abu-Bakr NH, Yahia NA, Ibrahim YE. Root and canal morphology of permanent mandibular molars in a Sudanese population. *International Endodontic Journal*. 2007 Oct;40(10):766-71.
29. Calberson FL, De Moor RJ, Deroose CA. The radix entomolaris and paramolaris: clinical approach in endodontics. *Journal of endodontics*. 2007 Jan 1;33(1):58-63.
30. Reibiero FC, Consolaro A. Clinical and anthropological importance of distolingual root seen in lower permanent molars. *Endodonzia*. 1997;15:72-8.
31. Reichart PA, Metah D. Three-rooted permanent mandibular first molars in the Thai. *Community dentistry and oral epidemiology*. 1981 Aug;9(4):191-2.
32. Gu Y, Zhou P, Ding Y, Wang P, Ni L. Root canal morphology of permanent three-rooted mandibular first molars: part III-an odontometric analysis. *Journal of endodontics*. 2011 Apr 1;37(4):485-90.
33. Walker RT. Three-rooted lower first permanent molars in Hong Kong Chinese. *British Dental Journal*. 1985;159:298-9.
34. Gopikrishna V, Reuben J, Kandaswamy D. Endodontic management of a maxillary first molar with two palatal roots and a single fused buccal root diagnosed with spiral computed tomography-a case report. *Oral Surgery, Oral Medicine, Oral Pathology, Oral Radiology, and Endodontology*. 2008 Apr 1;105(4):e74-8.
35. Bhargavi N, Velmurugan N, Kandaswamy D. The hunt for elusive canals. *Endodontology*. 2005;17(1):18-21.





**JIDAK**

JOURNAL OF INDIAN DENTAL ASSOCIATION - KOCHI